

Clinical Diagnostic Procedures in Endodontics

Humaira Anjum Baig*

Department of Endodontics, King Fahd University, Saudi Arabia

Submission: November 1, 2015; **Published:** January 27, 2016

***Corresponding author:** Humaira Anjum Baig, Department of Endodontics, King Fahd University, Saudi Arabia, Email: humaira_shakeel@yahoo.com

Definition

Endodontics is a branch of dentistry that deals with the etiology, diagnosis, prevention and treatment of the diseases of the pulp and periapical tissues compatible with good health.

- To arrive at a diagnosis, there is a definitive procedure to be followed which involves step by step implementation of the clinical diagnostic methods.
- A key purpose of establishing a proper pulpal and periapical diagnosis is to determine what clinical treatment is needed.
- Another important purpose of establishing universal classification system is to allow communication between educators, clinicians, students and researchers.

In 2008, the American Association of Endodontists held a consensus conference to standardize diagnostic terms used in Endodontics [1-4]. The goals were to propose universal recommendations regarding endodontic diagnoses; develop a standardized definition of key diagnostic terms that will be generally accepted by Endodontists, educators, third parties and students; determine radiographic criteria, objective test results and clinical criteria needed to validate the diagnostic terms established at the conference. Both the AAE & American Board of Endodontics have accepted these terms and recommend their usage across all dental disciplines and healthcare professions [5-7].

Examinations & Diagnostic Procedures

- Diagnosis cannot be made from a single isolated piece of information [4].
- The clinician must systematically gather all of the necessary information to make a "probable" diagnosis.
- When taking the medical and dental history, the clinician should already be formulating in his or her mind a preliminary but logical diagnosis, especially if there is a chief complaint

- The clinical and radiographic examinations in combination with a thorough periodontal evaluation and clinical testing (pulp and periapical tests) are then used to confirm the preliminary diagnosis.
- In some cases, the clinical and radiographic examinations are inconclusive or give conflicting results and as a result, definitive pulp and periapical diagnoses cannot be made.
- It is also important to recognize that treatment should not be rendered without a diagnosis and in these situations, the patient may have to wait and be reassessed at a later date or be referred to an endodontist.

Symptoms

- Subjective Symptoms:** Symptoms which are experienced and reported by the patients to the clinician.
- Objective Symptoms:** Symptoms which are ascertained by the clinician through various tests.

History and records

History taking forms an integral part of clinical evaluations. Basically questions concerning the patients (Table 1).

- Chief complaint
- Past medical history
- Past dental history are reviewed

The importance of past medical history should never be underestimated as this forms the backdrop of most of our treatment plans. For ex:

- Diabetes mellitus- (RCT/extraction) to be done only when under check.
- Hypertension- Extractions to be avoided. (Secondary bleeding).
- Cardiovascular diseases-prior antibiotic cover anesthesia without adrenaline.

- | | |
|--|--|
| <p>4. Renal hepatic impairment- choice of drug</p> <p>5. Drug allergies-</p> <p>6. Asthmatics-NSAIDS to be given with caution.</p> | <p>7. Jaundice-Hepatitis carrier</p> <p>8. Pregnancy- X-ray to be avoided.</p> <p>Drugs to be used with caution.</p> |
|--|--|

Table 1: Medical History.

Medical/dental history	Past / recent treatment, drugs
Chief complaint (if any)	How long, symptoms, duration of pain, location, onset, stimuli, relief, referred, medications
Clinical Exam	Facial symmetry, sinus tract, soft tissue, periodontal status (probing, mobility), caries, restorations (defective, newly placed)
Clinical testing	Cold, electric pulp test, heat
Pulp tests	Percussion, palpation, tooth slooth (biting)
Periapical test	
Radiographic analysis	Periapical x-rays (at least 2), bitewing (x-ray,) cone beam- computed tomography
Additional tests	Transillumination, selective anesthesia, test cavity

Subjective symptoms

Generally the subjective symptoms or chief complaints are:

1. Pain
2. Swelling
3. Loss of function
4. Loss of esthetics

The patient's chief complaint is the best starting point for a correct diagnosis

Pain – It may be defined as a noxious stimuli that causes discomfort.

Questions that should be asked are:

1. Kind of pain
2. Duration of pain
3. Causative factors if any- a)cold b)hot c)pressure
4. Relieving factors-
5. Cold
6. Pressure

Generally pulpal pain is described in one of the two ways.

1. Sharp, piercing and lancinating pain.
2. Dull, boring, gnawing, excruciating.

Patients may report that their dental pain is exacerbated by lying down or bending over. This occurs because of increase in blood pressure to the head, which results in increased pressure on the confined pulp [8,9].

*The first type of pain is caused by the excitation of the 'A' delta nerve fibres in the pulp.

*The second type of pain is caused by the excitation & slower rates of transmission of 'C' nerve fibres in the pulp.

The ability to localise pain is important. Sharp piercing pain in a tooth usually response to cold and is easy to localize. When the pain is defused, the patient describes an area of discomfort rather than a specific site. The duration of pain is often diagnostic.

a) The pulpal pain may last for a short duration only as long as the irritant is in contact with the tooth (acute reversible pulpitis). Endodontics may not be necessary.

b) If the pain persists for a longer duration, even after the removal of the irritant i.e. cold/hot, (irreversible pulpitis). Endodontic therapy is indicated.

Objective symptoms

1. Visual and tactile inspections
2. Percussions
3. Palpations
4. Mobility
5. Radiography
6. Thermal test
7. Electric pulp test
8. Anesthetic test
9. Test cavity

Visual & tactile inspection: The thorough visual and tactile examination of hard & soft tissues relies on checking the 3 C's i.e. Color, Contour and Consistency

a) Color: Any deviation from healthy coral pink color of gingiva is easily recognizable when inflammation is present.

Acute inflammation- fiery red color
Chronic inflammation- dull red, bordering purple.

b) Contour: swelling brings about a change in the contour of hard or soft tissue.

- c) Consistency: Soft, spongy, fluctuant tissue consistency differs from healthy, firm tissue and is indicative of underlying pathology.

In Hard Tissues

- a) Color: A normal appearing crown has a life like translucency and sparkle, that is missing in a pulp less tooth teeth that are discolored, opaque and less life like should be carefully examined.
- b) Contours: Of crown should be examined because fracture, wear and restorations change crown contours.
- c) Consistency: Of a hard tissue relates to the presence of caries and internal and external resorption. In presence of caries, the dentine consistency is very soft, except in arrested caries.

Technique of Inspection: It involves the comprehensive use of one's eyes, fingers and explorer and the periodontal probe. The examination of the teeth & the periodontium should always be done under:

1. dry conditions,
2. having optimum light and
3. most importantly using all possible barriers such as gloves, face mask and protective eye wear.

Percussion: Percussion of tooth initially with fingers (low intensity) and then later with increasing intensity using the handle of an instrument is undertaken to evaluate the status of the periodontium surrounding the tooth. A positive response differing from adjacent tooth, usually indicates the presence of periodontitis. When periodontitis occurs unrelated to periodontal lesions, it usually is a sequelae to pulpal necrosis. When apical periodontitis is present as a sequelae to periodontal lesions, the pulp is usually vital. While percussing a particular tooth, a more valid response can be obtained if at the same time, patient's body movement, reflex pain reactions or even an unspoken response is observed (Figure 1).

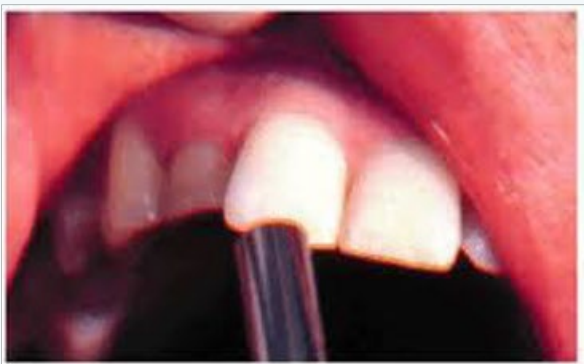

Figure 1: Percussion

Palpation: It is done with finger tips, using light pressure to examine tissue consistency and pain response. It is done to determine whether the tissue is fluctuant and enlarge sufficiently for incision and drainage.

- a) Presence, intensity and location of pain.
- b) Presence of bone crepitus.

Mobility & Depressibility Testing

The mobility test is used to evaluate the integrity of the attachment apparatus surrounding the tooth.

- a. The technique consists of moving the tooth laterally in its socket by using the handles of 2 instruments
- b. The test of depressibility consists of moving the tooth vertically in its socket. In a positive situation the chances of saving the tooth are very poor (Table 2). Endodontic treatment should not be carried out on teeth with grade 3 mobility unless the mobility is reduced (Figure 2).

Table 2: Degree of Mobility.

0 degree mobility	Physiologic Mobility
1 degree mobility	Noticeable Movement Of The Tooth In Its Socket
2 degree mobility	Movement In A Range Of 1mm
3 degree mobility	Movement Greater Than 1mm Or When The Tooth Can Be Depressed

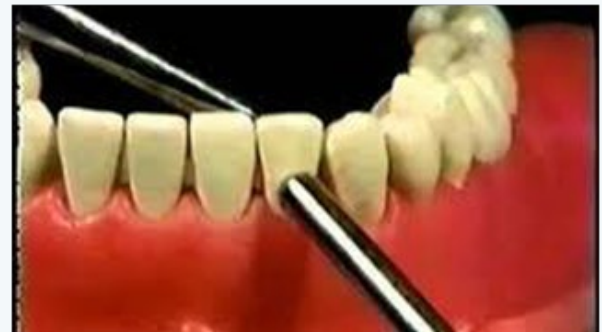

Figure 2: Mobility

Radiography: Radiographs contain information on the presence of

- a. Caries involving the pulp
- b. May show number, course, shape, length and width of root canals.
- c. May also show the presence of calcified material in the pulp chamber.
- d. May also show internal and external resorption.
- e. Thickening of the pdl and also resorption of cementum.
- f. Can also observe the nature and extent of periapical &

alveolar bone destruction.

Limitations of radiographs as diagnostic tools:

1. A lesion cannot be visualized if it is still in the cancellous bone. Only when it has penetrated into the cortical bone we get a radiolucent image. In other words....
 - a) A periapical lesion is usually larger than its image.
 - b) A pathologic area can be present yet be obscured by a plate of cortical bone.
 - c) An acute alveolar abscess in a tooth can have a normal radiographic appearance with no apparent radiolucency.
2. A radiograph cannot be used to differentiate reliably among a chronic abscess, a granuloma or a cyst. An accurate diagnosis can only be made by histopathological evidence. The routinely accepted d/d features are:
 - a) Granuloma: it is a dense radiolucency that is well defined.
 - b) Chronic alveolar abscess: it is a diffused radiolucency showing irregular pattern of bone destruction.
 - c) Cyst: it is a radiolucent mass surrounded by thin line of radioopacity.
3. The presence of periapical radiolucency does not automatically indicate a diseased tooth.
 - a) It may superimpose an anatomical land mark such as maxillary sinus, medullary spaces, mental foramen, incisive foramen.
 - b) In many instances it may also be a disorder that is not pulpally related to Ameloblastoma, Malignant tumors, Periodontal cyst, Traumatic bone cyst.
4. A major limitation of radiography is that of different interpretations by different observers.

Advancements in radiography:

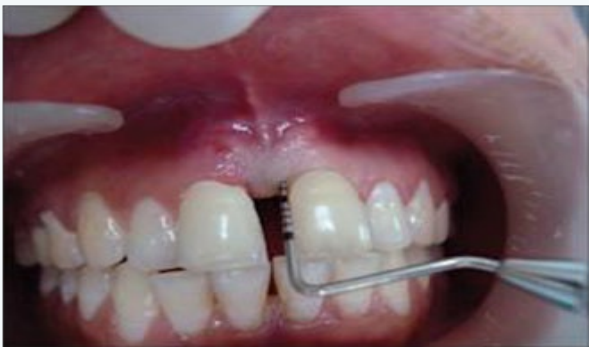

Figure 3: Periodontal Probe

1. **Digital intra oral radiography:** All X-ray images are

in a digital format, viewed on a computer screen and thus requiring less than 1/3rd of the radiation doses administered when taking conventional X-ray film.

2. **Digital OPG:** These are panoramic x-rays also used in digital format. With the latest software applications, one X-ray image allows the dentist to investigate many different aspects of your oral health (Figure 3-5).

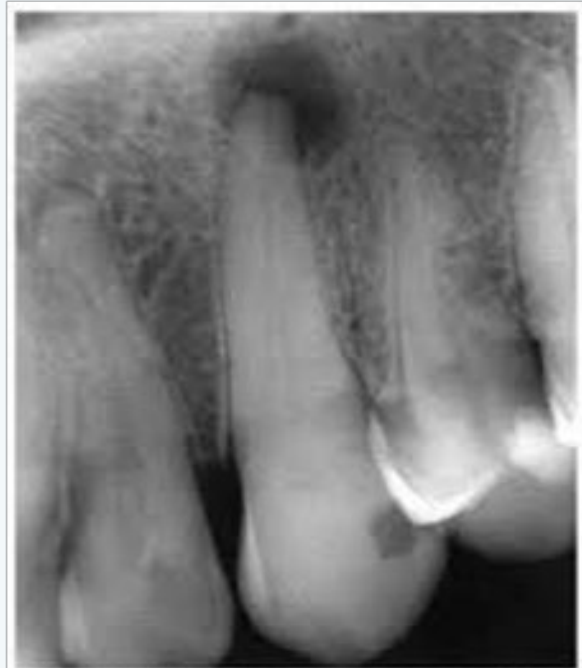

FIGURE 2 - Maxillary canine with obliteration of pulp chamber by calcific metamorphosis of the pulp. It is noteworthy that after a few years chronic periapical lesion was detected. It is found in approximately a quarter of cases between 2 and 22 years of monitoring.

Figure 4: Periapical x-ray

Cone beam computed tomography (CBCT):

- a) Computed Tomography has evolved into an indispensable imaging method in clinical routine.
- b) CT yields images of much higher contrast compared with conventional radiography.
- c) It was the first method to non invasively acquire images inside the human body that were not biased by superimposition of distinct anatomical structure.
- d) CBCT is an X-ray imaging approach that provides high resolution 3D images of the jaws & teeth.
- e) CBCT shoots out a cone shaped x-ray beam and captures a large volume of area requiring minimal amounts of generated x-rays.
- f) Within 10 seconds the machine rotates 360 degrees around the head and captures 288 static images (Figure 6).

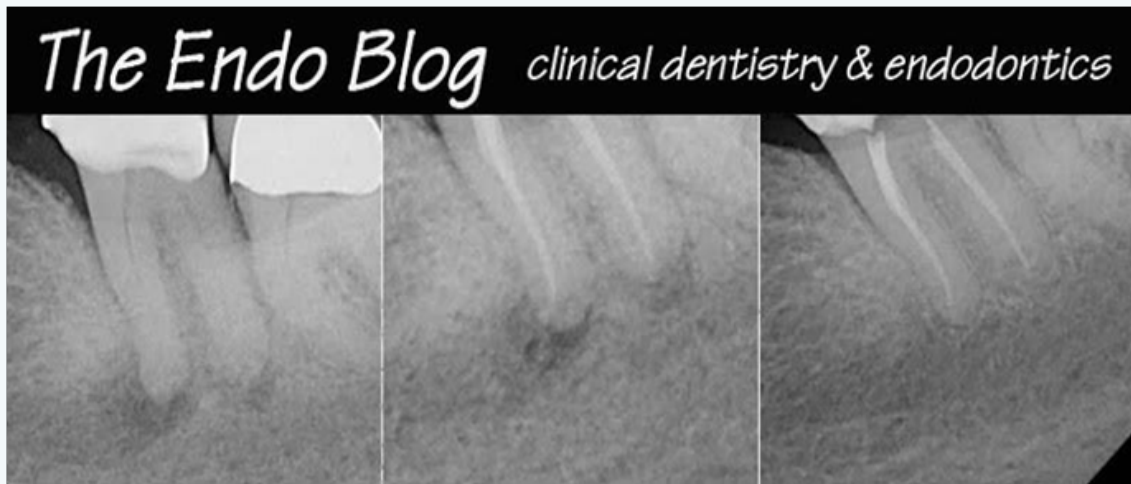

Figure 5: Periapical X-ray

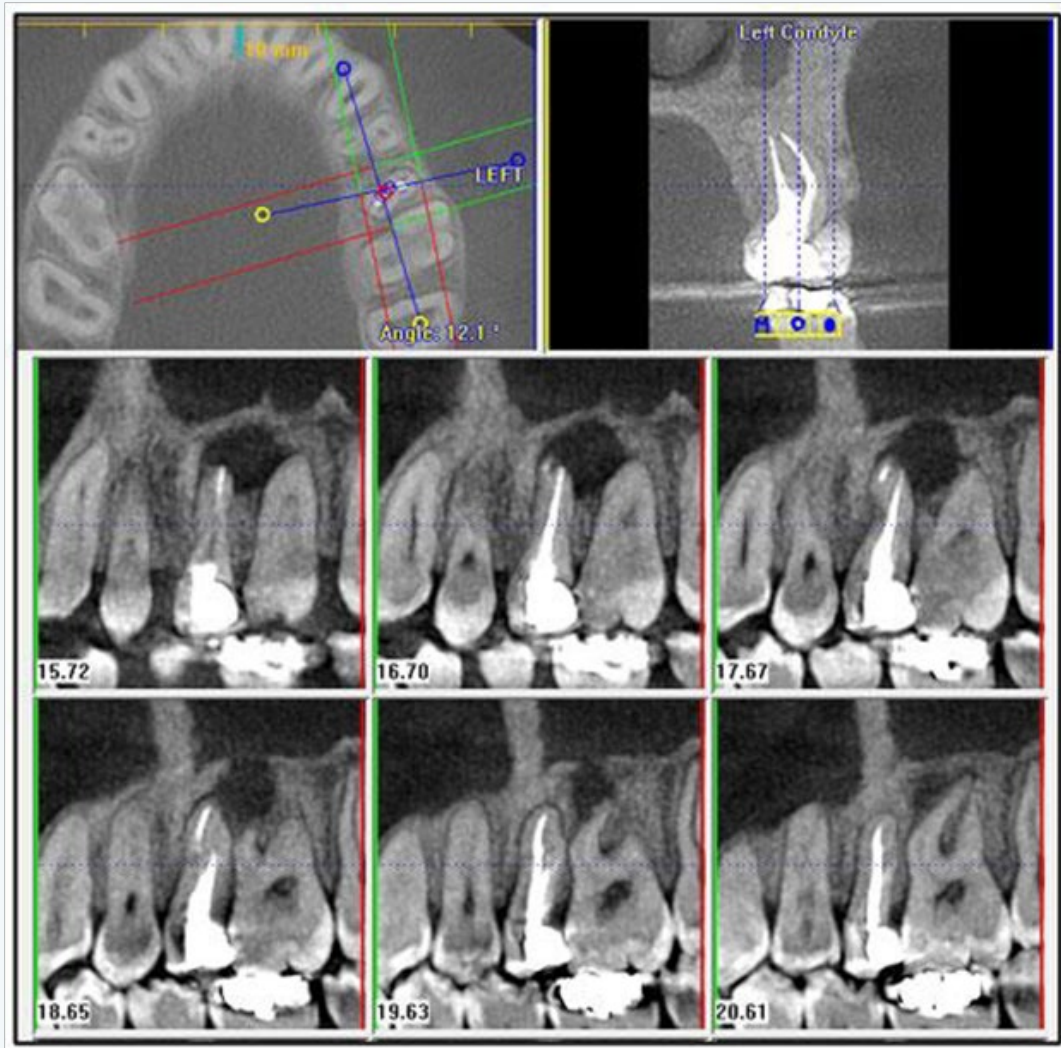


Figure 6: CBCT images

Advantages

- Precise identification & detection of periapical lesions.
- Detection of mandibular canal.
- Complete 3D reconstruction & display from any angle.
- Patient radiation dose 5 times lower than normal CT.
- It requires only a single scan to capture the entire object, with reduced exposure time.

Micro – CT:

Recently, micro CTs, which essentially comprise a miniaturized design of cone beam CTs – typically used for non destructive 3D microscopy have become commercially available. The X-rayed measuring field is usually as small as 2 cubic cm. in volume.

Tuned Aperture Computed Tomography (TACT)

Improve accuracy in caries diagnosis because of its 3D or pseudo 3D capabilities.

TACT slices can be produced from an arbitrary number of X-ray projections, each exposed from a different angle. TACT is useful in detection of caries & recurrent caries, periodontal bone loss, periapical lesion, localization and TMJ bone changes.

MRI- Magnetic Resonance Imaging

This technique is based on the presence of specific magnetic properties found within atomic nuclei containing protons and neutron.

Indications:

- Assessing diseases of TMJ.
- Cleft lip and palate.
- Tonsillitis and adenoiditis.
- Cyst and infections.
- Tumours.

Thermal Test: This test involves application of heat and cold to a tooth, to determine sensitivity to thermal changes.

- A positive response to cold indicates pulp vitality regardless of whether the pulp is normal or not. An abnormal response to heat indicates the presence of pulpal or periapical disorder requiring endodontic therapy.
- When a reaction to cold occurs the patient can immediately point to the affected tooth, whereas a positive response to heat on a single tooth results in a localized painful response which is momentarily delayed.

a) Technique of Heat Testing

- Use of hot air, hot burnisher, hot guttapercha, after isolation and drying.
- After isolation with the rubber dam immersing the tooth in a coffee hot water with a syringe.

b) Technique for Cold Testing

- Use of cold air
- Ethylchloride sprays.
- Use of ice pencils
- CO₂ snow (dry ice)-78 degree C.

Electric Pulp Testing: The electric pulp tester uses a nerve stimulation to determine the presence of vitality. The objective is to stimulate a pulpal response by subjecting the tooth to an increasing degree of electric current. A +ve response is an indication of vitality whereas a -ve response is indicative of pulpal necrosis (Figure 7).

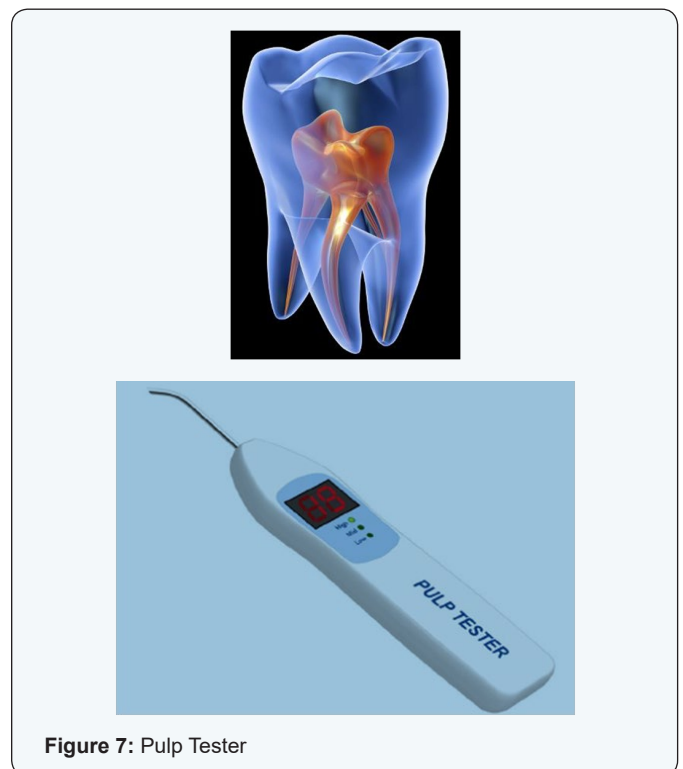

Figure 7: Pulp Tester

Limitation of the test are:

- A false +ve response can be achieved when moist gangrenous pulp is present in the root canals. In multirooted teeth, when some nerve fibers are still vital in 1 or more canals.
- A false -ve response occurs in the presence of calcification in the pulp tissue.

- c) More current is needed in a tooth with reparative dentin, diminishing size of pulp cavity and fibrotic pulp.

Anaesthetic Test

- a) This test is restricted to patients who are in acute pain at the time of examination and when the usual tests have failed to enable the clinician to identify the offending tooth
- b) The objective is to anaesthetize a single tooth at a time until the pain disappears, thus localizing the specific offending tooth.
- c) Technique is to start with the most posterior tooth in the most particular arch and then shift to the mesial.

Test cavity

- a) It allows one to determine pulp vitality and is performed only when all other tests have failed.
- b) It is done by drilling the cavity in the tooth, through the DEJ OF AN un-anaesthetized. If a +ve response is there, medicated cement is filled in, and the adjacent tooth is drilled.

Techniques for detecting vertical crown/root fractures: In vital teeth the most common reason for a fracture is trauma. In non-vital teeth trauma may also be a contributory factor but endodontic treatment followed by overzealous post reinforcement is a common cause.

1. Fibre optic examination.
2. Wedging and staining.
3. Radiographic examination.
4. Thorough dental history.
5. Bite tests.
6. Periodontal probing.
7. Restoration removal.

Diagnostic Terminology Approved By The American Association Of Endodontists And The American Board Of Endodontics

Pulpal Diagnoses

1. Normal Pulp: Pulp is symptom free and normally responsive to pulp testing.
2. Reversible Pulpitis: Indicates that the inflammation should resolve and the pulp returned to normal following management of the cause.
3. Symptomatic Irreversible Pulpitis: It is based on subjective

and objective finding that the vital inflamed pulp is incapable of healing and that root canal treatment is indicated.

4. Asymptomatic Irreversible Pulpitis: It is a clinical diagnosis based on subjective and objective findings that the vital inflamed pulp is incapable of healing and that root canal treatment is indicated. There are no clinical symptoms.
5. Pulp Necrosis: Indicates death of the dental pulp requiring root canal treatment. The pulp is non-responsive to pulp testing and is asymptomatic
6. Previously Treated
7. Previously Initiated Therapy: Such as pulpotomy or pulpectomy.

Apical Diagnosis

1. Normal apical tissues are not sensitive to percussion or palpation and radiographically, the lamina dura is intact and the PDL is uniform.
2. Symptomatic apical periodontitis represents inflammation of the apical periodontium, producing clinical symptoms involving a painful response to biting and / or percussion or palpation.
3. Asymptomatic apical periodontitis is inflammation and destruction of the apical periodontium that is of pulpal origin. It appears as an apical radiolucency.
4. Chronic apical abscess is an inflammatory reaction to pulpal infection and necrosis characterized by gradual onset and discharge of pus.
5. Acute apical abscess is an inflammatory reaction to pulpal infection and necrosis characterized by rapid onset, spontaneous pain, tenderness to percussion pus formation.
6. Condensing osteitis

Classification of Endodontic Emergencies

Pre-treatment

- a. Dentine hypersensitivity
- b. Pain of pulpal origin
- c. Reversible pulpitis
- d. Irreversible pulpitis
- e. Acute apical periodontitis
- f. Acute periapical abscess
- g. Traumatic injury
- h. Cracked tooth syndrome

Patients under Treatment

- a) Mid treatment flare-ups
- b) Exposure of pulp
- c) Fracture of teeth
- d) Recently placed restoration
- e) Periodontal treatment

Post Endodontic Treatment

- a. Over instrumentation
- b. Over extended filling
- c. Under filling
- d. Fracture of root
- e. High restoration

References

1. Glickman GN (2009) AAE consensus conference on diagnostic terminology: background & perspectives. *J Endod* 35(12): 1619-1620.
2. Seltzer S, Bender IB, Ziontz M (1963) The dynamics of pulp inflammation: correlations between diagnostic data and actual histologic findings in the pulp. *Oral surg Oral Med Oral pathol* 16: 969-977.
3. Berman LH, Hartwell GR (2015) *Diagnosis*. In: Cohen S (Eds.) *pathways of the pulp*. (11th edn), Mosby, USA.
4. Schweitzer JL (2009) The endodontic diagnostic puzzle. *Gen.dent* 57(6): 560-567.
5. Pantera CT (2009) AAE Consensus conference recommended diagnostic terminology. *J Endod* 35(12): 1634
6. American association of Endodontists (2012) *Glossary of endodontic term*. 8th edn.
7. Glickman GN, Bakland LK, Fouad AF, Hargreaves KM, Schwartz SA (2009) Diagnostic terminology: report of an online survey. *J Endod* 35(12): 1625-1633.
8. Abbott PV, Yu C (2007) A clinical classification of the status of the pulp and the root canal system. *Aust. Dent. J* 52(1 suppl): S17-S31.
9. Vinay Gupta. *Diagnostic methods in endodontics*.