

A Rare Case of Ewing's Sarcoma in the Mandible of A 22-Month-Old Child: A Case Report and Review of The Literature

Fahd Alrowily^{1*}, Leland McFadden², Deborah McFadden³ and Carla Penner⁴

¹Department of Oral and Maxillofacial Surgery, Canada

²Department of Oral and Maxillofacial Surgery, University of Manitoba, Canada

³Department of Pathology & Laboratory Medicine, University of British Columbia, Canada

⁴Department of Pathology, University of Manitoba, Canada

Submission: November 11, 2015; **Published:** March 23, 2016

***Corresponding author:** Fahd Alrowily, BDS, M-dent, FRCDC, Private practice of Oral and Maxillofacial Surgery, AB, Canada,

Email: dralrowily@yahoo.com

Abstract

Keywords

Abbreviations: ES: Ewing's Sarcoma; FNA: Fine Needle Aspiration; PNET: Primitive Neuro Ectodermal Tumor; FISH: Fluorescent In situ Hybridization

Introduction

Ewing's sarcoma (ES) is a highly lethal round cell sarcoma, thought to be of neuroectodermal origin, first described by James Ewing in 1921. ES occurs most often in younger patients, with 90% between the ages of 5 and 30 years, and affects males in more than 60% of cases. Nearly 50% of all reported cases of ES occur in the femur and pelvic bones. Of the fewer than 3% of all cases that occur in the jaws, the majority involve the mandibular ramus, with a few cases reported in the maxilla. Rapid growth and propensity for metastasis are dominant features of this malignant bone tumor. Thus, the possibility exists that jaw involvement may represent metastasis from another skeletal site. When ES involves the jaws, there may be facial deformity, destruction of alveolar bone, loosening of the teeth, mucosal ulceration, or soft tissue penetration. Pain, swelling, and sensory disturbances may be associated findings. Fever, leukocytosis, and an elevated erythrocyte sedimentation rate may also be present and lead to an erroneous diagnosis of osteomyelitis. We report a rare case of ES, occurring in the mandibular symphysis of a 22-month-old boy, to add to the body of literature on the subject.

Case report

A 22-month-old boy was referred to the Oral and Maxillofacial Surgery Department of the Health Sciences Center Hospital

in Winnipeg. The patient had presented to the Emergency Department with concerns related to a mass in the anterior mandible. The patient's parents had noted progressive swelling of his chin for three months before admission. Two weeks prior to being seen in the Emergency Room, the parents had noted that the child's lower teeth were loose and there was periodic bleeding from the gum. There was no history of trauma. The child appeared to have tenderness and preferred soft foods. There was no associated change in his energy: his level of energy and activity had remained unchanged. He had had no weight loss. His past medical history was unremarkable. On examination, there was swelling and tenderness in the region of the chin. There were no palpable nodes in the neck, supraclavicular or axillary regions. Trans orally, swelling was noted to involve the symphysis area (Figure 1). Physical examination was otherwise noncontributory, and the patient was in good general health. Radiographic examination showed a radiolucent lesion extending from the lower right premolar area to the left premolar area (Figure 2). The medullary and cortical bone were destroyed, and there was expansion into the soft tissues (Figure 3). MRI of the mandible showed a 2.2 cm x 3.2 cm mass in the anterior mandible, centered in the midline, there was heterogenous signal on T2 weighted images, with focal areas of increased signal intensity. The signal appeared more homogenous on T1 weighted images. The lesion demonstrated mild heterogenous enhancement following Gadolinium IV contrast

infusion (Figure 4). Initially a fine needle aspiration (FNA) was performed and cytological examination showed features of a small round blue cell tumor with features suggestive of an ES/ Primitive neuroectodermal tumor (PNET). An excisional biopsy was performed the histologic examination showed sheets of small round blue cells with scant cytoplasm separated with some fibrous strands (Figure 5). Mitotic and apoptic figures were conspicuous. The tumor cells appeared to destroy bony septae. Neoplastic cells were strongly and diffusely reactive with CD99 and FLI-1 immuno histochemistry. NSE, CD45, Myogenin, and MyoD1 were non-reactive ruling out the possibility of a tumor of skeletal, neural or lymphoid origin. Fluorescent in situ hybridization (FISH) studies for ES rearrangements were performed in the Department of Pathology & Laboratory Medicine at BC Children's Hospital and showed the EWSR1 locus located on chromosome 22 q12. There was no evidence of a rearrangement involving FKHR (FOXO1) (which is frequently rearranged in alveolar rhabdomyosarcoma).

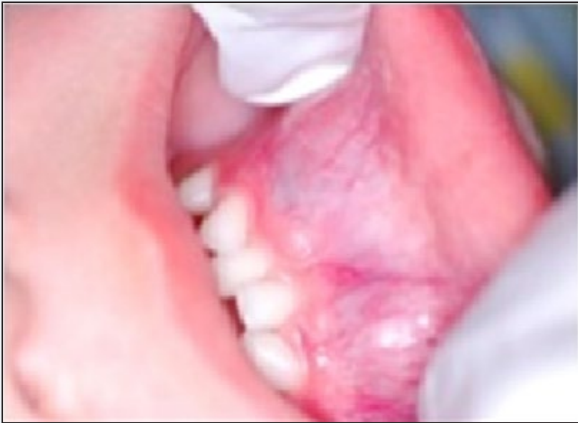

Figure 1: Anterior mandibular swelling.

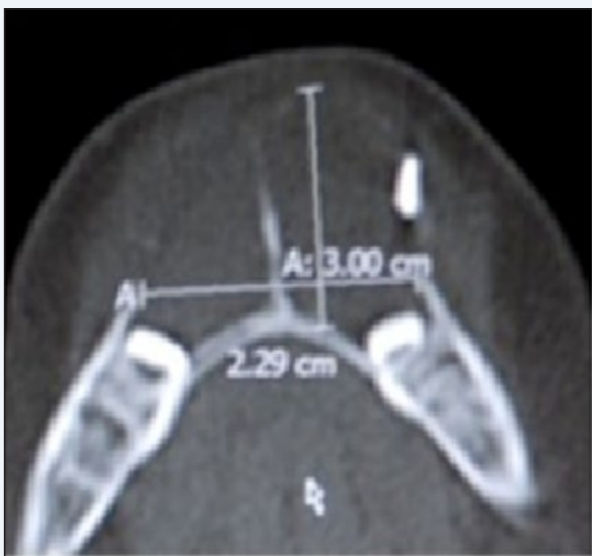

Figure 2: CT scan axial view.

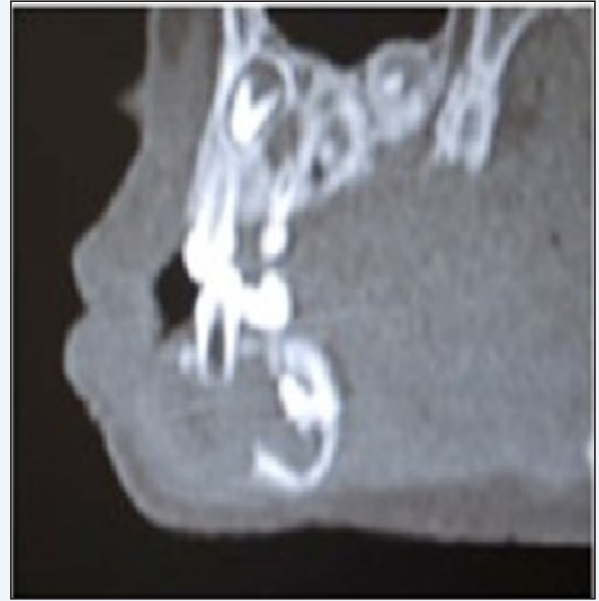

Figure 3: CT scan sagittal view.

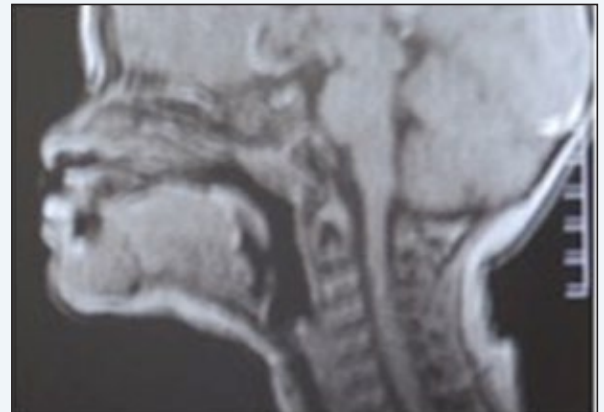


Figure 4: MRI sagittal view.

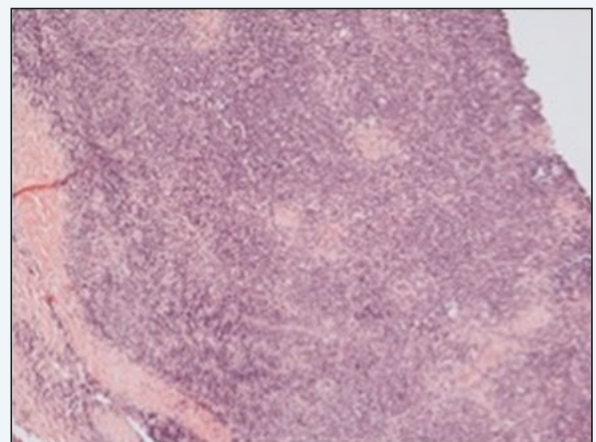


Figure 5: Histopathological slide of the biopsy.

Clinical Examinations To Exclude A Metastatic Tumor Were Negative

The case was reviewed at the Cancer Care Center tumor board and the decision was made to start with chemo radiation therapy. The patient received 5580 cGY of radiation in 31 fractions and underwent chemotherapy with Cyclo phosphamide, Vincristine and Adriamycin for twenty-five weeks, with Ifosfamide and Etoposide for twenty-three weeks. Follow up with PET scan six months after completion of treatment showed no significant hypermetabolism in the region of the patient's primary tumor in the anterior mandible (Figure 6).

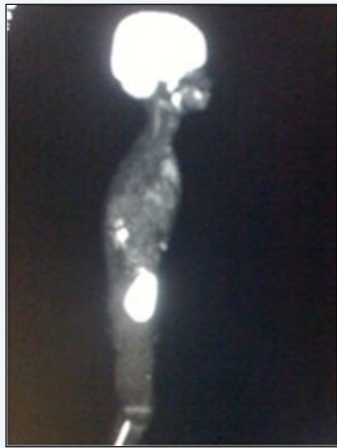

Figure 6: PET scan six months after completion of treatment.

Discussion

Clinical presentation of ES may be accompanied by swelling with or without tenderness and so may simulate an infectious as well as a malignant process. This is especially so when ES presents in unusual locations, such as in the jaw, where it is rarely encountered. Presentation in the anterior mandible is even rarer. Ewing's sarcoma belongs to a group of neoplasms often referred to as small round cell tumors, which typically occur in childhood and adolescence. The histologic findings in this group of tumors consist of poorly differentiated cells with uniform nuclei, round or oval, and scarce cytoplasm. The differential diagnosis of small round cell tumors includes 4 main categories: lymphoma, neuroblastoma, rhabdomyosarcoma, and primitive neuroectodermal tumors, a group that includes Ewing's sarcoma. Distinguishing these entities requires histopathologic examination, including immunohistochemistry, as well as use of cytogenetic and molecular techniques. Of the immunohistochemical stains, positive MIC-2 (CD-99) supports a diagnosis of ES. Historically, the survival rate of Ewing's sarcoma has been low. Treatment consists of local control of the disease in its primary location, using radical surgery or radiotherapy, and systemic control of subclinical micro metastasis with chemotherapy, thus obtaining a survival rate between 50% and 70%. Presence of meta states is the most important predictive factor that influences the

prognosis. The indications for surgery should be carefully considered in each patient with regard to age and location, size, extension, and resectability of the primary tumor, always taking into account the deformity and surgical morbidity that may result. It is essential that special consideration be given to issues related to the growing child to achieve optimal restoration of mastication, speech, and facial appearance as well as maintenance of bone volume. Concerns about interfering with the dynamics of the growing pediatric facial skeleton when reconstructive surgery is required for the treatment of tumors are warranted, and the question of growth of the reconstructed mandible remains controversial. Patients with mandibular tumors are noted to have a more favorable overall survival than those with any other bone site of origin. While ES is rare in maxillofacial population, it does occur and must be considered in the differential diagnosis if a child presents with a facial mass.

Acknowledgement

The authors are grateful to Dr. Deborah McFadden (clinical professor, department of Pathology & Laboratory Medicine, University of British Columbia), for her great help and support.

Reference

1. Regezi JA, Sciubba J (1999) Oral Pathology. Saunders, Philadelphia, USA, pp. 407-408.
2. Behnia H, Motamedi MH, Bruksch KE (1998) Radiolucent lesion of the mandibular angle and ramus. *J Oral Maxillofac Surg* 56(9): 1086-1090.
3. Waldron CA (1995) Bone pathology. In Neville BW, Damm DD, Allen CM, et al. (Eds.), *Oral and Maxillofacial Pathology*. Saunders, Philadelphia, USA, pp. 487-489.
4. Shafer WG, Hine MK, Levy BM (1983) *A Textbook of Oral Pathology*. Saunders, Philadelphia, USA, pp. 177-178
5. Angervall L, Enzinger FM (1975) Extraskeletal neoplasm resembling Ewing's sarcoma. *Cancer* 36(1): 240-251.
6. Gillespie JJ, Roth LM, Wills ER, Einhorn LH, Willman J (1979) Extraskeletal Ewing's sarcoma: Histologic and ultrastructural observations in three cases. *Am J Surg Pathol* 3(2): 99-108.
7. Ward-Booth P (1992) Surgical management of malignant tumors of the jaws and oral cavities. In Peterson LJ, Indresano AT, Marciani RD, et al. (Eds.), *Principles of Oral and Maxillofacial Surgery*. Vol 2. Philadelphia, USA, pp. 806.
8. Krane MS, Schiller AL (1994) Hyperostosis, neoplasms, and other disorders of bone and cartilage. In Isselbacher KJ, Braunwald E, Wilson JD, et al. (Eds.), *Harrison's Principles of Internal Medicine*. Vol 2, New York, USA, pp. 2197.
9. Weiss SW, Goldblum JR (2001) *Soft Tissue Tumor and Ewing's Sarcoma Histologic and Immunohistochemical Staining*. Mosby, Philadelphia, USA, pp. 1292-1295.
10. Weiss SW, Goldblum JR (2001) *Soft tissue tumor and Ewing's sarcoma histologic and immunohistochemical staining*. Mosby, Philadelphia, USA, pp. 1303-1305.
11. German J (1994) Cytogenetic aspects of human disease. In Isselbacher KJ, Braunwald E, Wilson JD, et al. (Eds.), *Harrison's Principles of Internal Medicine*, McGraw-Hill, New York, USA, pp. 372-373.

12. Deutsch M, Wollman MR (2002) Radiotherapy for metastases to the mandible in children. *J Oral Maxillofac Surg* 60(3): 269-271.
13. Sturla LM, Westwood G, Selby PJ, Lewis IJ, Burchill SA (2000) Induction of cell death by basic fibroblast growth factor in Ewing's sarcoma. *Cancer Res* 60(21): 6160-6170.
14. Gorospe L, Fernández-Gil MA, García-Raya P, Royo A, López-Barea F, et al (2001) Ewing's sarcoma of the mandible radiological features with emphasis on MRI appearance. *Oral Surg Oral Med Oral Pathol Oral Radiol Endod* 91(6): 728-734.
15. Talesh KT, Motamedi MHK, Jeihounian M (2003) Ewing's Sarcoma of the Mandibular ondyle: Report of a Case. *J Oral Maxillofac Surg* 61(10): 1216-1219.
16. Infante-Cossio P, Gutierrez-Perez JL, Garcia-Perla A, Noguer-Mediavilla M, Gavilan-Carrasco F(2005) Primary Ewing's Sarcoma of the Maxilla and Zygoma: Report of a Case. *J Oral Maxillofac Surg* 63(10): 1539-1542.
17. Li JS, Chen WL, Huang ZQ, Zhang DM (2009) Pediatric Mandibular Reconstruction After Benign Tumor Ablation Using a Vascularized Fibular Flap. *J Craniofac Surg* 20(2): 431-434.