

# The Using of Cervical and Deltopectoral Flaps in the Reconstruction Surgery of Head and Neck Area

**Chingiz R Rahimov, Mohammad M Davudov, Parisa Foroughiasl\***

*Azerbaijan Medical University, Azerbaijan*

**Submission:** October 01, 2015; **Published:** April 28, 2016

**\*Corresponding author:** Dr. Parisa Foroughiasl, Azerbaijan Medical University, 3585 S, Centinela Ave. Apt 8, Azerbaijan, Tel: (+1) 310 795 3407; Email: dr.parisaforoughi@hotmail.com

## Abstract

Over the past three decades, many advances have been made in the treatment of head and neck cancer. These include the combination of radiation therapy and chemotherapy with surgery, conservation laryngeal surgery, and modifications of the classic radical neck dissection. The desire to improve postoperative outcomes by focusing on preservation of tissue and function led to these advances and resulted in more rapid recovery and decreased cosmetic deformities while maintaining equal cure rates to prior techniques. Despite the fact that these changes have decreased morbidity, overall survival rates for patients with head and neck cancer has reached a plateau over the past several decades. Because of this, the focus of many head and neck surgeons in the past 20 years has been directed at further decreasing morbidity from surgery and improving functional and reconstructive outcomes. Squamous cell carcinoma is one of the most common malignant tumors of the skin and oral mucosa. However, squamous cell carcinoma involving near total upper and lower lip and oral commissure. Simultaneous reconstruction of the lower lip has been inconclusive and presents a challenge to the surgeon. We report such a case and outline our simultaneous reconstruction with local flaps. To the best of our knowledge this has never been reported.

**Keywords:** Squamous cell carcinoma; Computed tomography

## Introduction

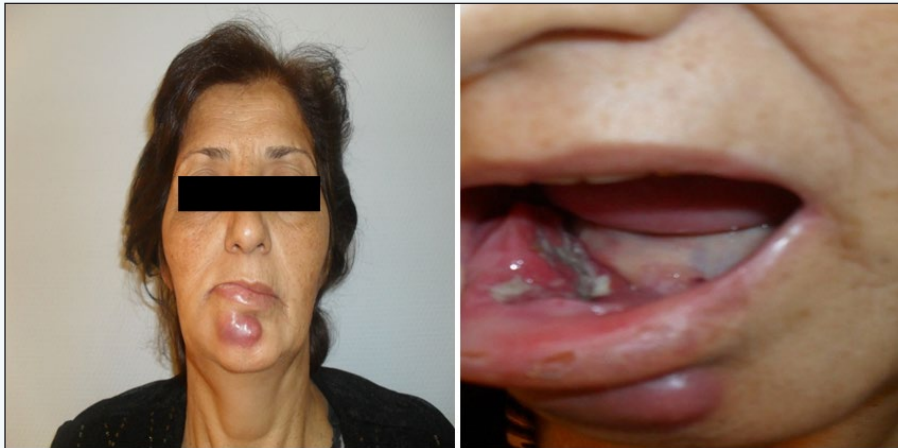Squamous cell carcinoma (SCC) is one of the most common malignant tumors of the skin and oral mucosa. SCC of the lips accounts for approximately 30%, SCC of the 14 % of oral cavity malignancies [1]. The majority of these occur on the lower lip because of its great exposure to precipitating factors. SCC grows along the mucosal surfaces and infiltrates deeper structures in a predictable pattern. Tumors can spread by direct penetration, tracking along nerve and vascular invasion routes [2,3]. Defects after surgery of the lips may be classified into upper lip, lower lip, and oral commissure. SCC of the lip usually involves the upper or lower lip and oral commissure, but the behavior of SCC in this case was different. The defects in this case involved two parts of the lip and floor of the mouth, reconstruction was a challenge and there is no gold standard. Reconstructive lip and floor of the mouth surgery aims to restore function, obtain a watertight-seal, maintain sensation and avoid cosmetic deformity [4-6]. Reconstruction lip and floor of the mouth has been inconclusive and presents a challenge to the surgeon. We report such a case and outline our simultaneous reconstruction with combined cervical and deltopectoral flaps.

## Case Presentation

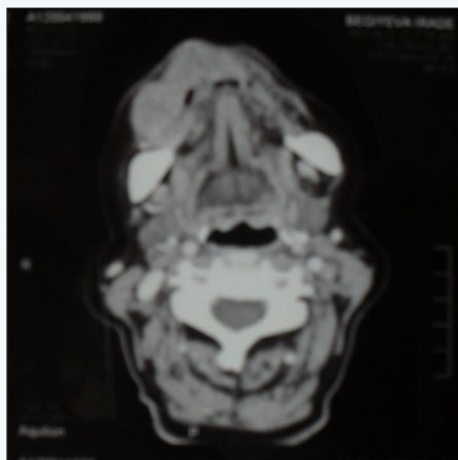
A 54-year-old Azeri woman presented with a large rapidly growing squamous cell carcinoma involving the lower lip, right oral commissure and right cheek. She had a history of a small proliferative mass on the right cheek 3 month previously, grew progressively and spread to the skin and membrane of lower lip and the pain has started. She had a proliferative mass on the lower lip that rapidly grew to involve the circumoral region and the right buccal mucosa (Figure 1A&1B). Incisional biopsy revealed well-differentiated squamous cell carcinoma. Physical examination revealed a tumor mass that involved skin and mucosa of the lower lip, the right oral commissure and the right buccal region including mucosa. An enlarged left submental lymph node was palpable. Sensation along her mental nerve was intact. Panorex X-ray showed no bony destruction. A computed tomography (CT) scan revealed an irregular lobulated contour, heterogeneous enhancing mass involving her lower lips, predominantly on the right side (Figure 2). The mass extended to her right buccal space, the anterior portion of the right masticator space and obliterated the fat plane of the anterior aspect of the right masseter muscle. There were necrotic submandibular lymph nodes

which measured 2.0 cm on the right and 0.8 cm on the left. A CT scan also revealed multiple subcentimeter lymph nodes on both cervical regions. No definite bony invasion was observed. Her parotid glands showed no abnormality. Thus, the clinical staging was T4N2bM0. En bloc resection with 1 cm margins was performed including near total lower lip, right commissure right buccal region and upper margin of mandible. In addition, right radical neck dissection was performed (Figure 3A&3B). Examination of frozen sections revealed no malignancy in any of the surgical margins. The lower lip and soft tissue of symphysis mandible were reconstructed with a deltopectoral flap, this flap used as a mucosal tube or a mucosal patch and a floor of the mouth advancement with cervical rotational-advancement flap. The superiorly based anterior cervical flap for intraoral reconstruction was popularized by Hollon Farr [1]. The blood supply to the flap is random and therefore its dimensions are limited. This flap is therefore applicable only in the repair of relatively small defects

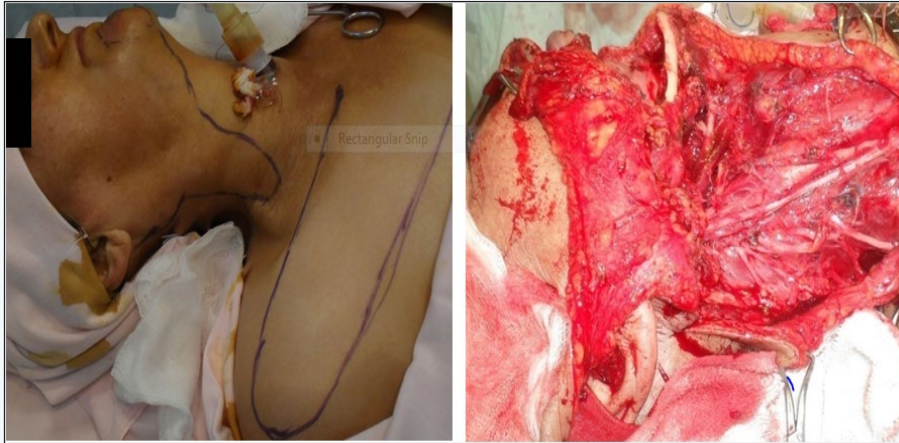
of the anterior oral cavity. Note that the distal third of the flap usually has to be discarded since it is unlikely to survive due to lack of blood supply. Rotation of this flap in the floor of the mouth results in a planned orocutaneous fistula which will need a second stage for its closure. Internal side of deltopectoral flap in the lower lip area was achieved with skin grafts (Figure 4A&4B). The pathology report showed well differentiated squamous cell carcinoma with lymphovascular invasion. All surgical resection margins showed no malignant cells. Metastatic squamous cell carcinoma was present in nine right cervical lymph nodes with extra capsular extension. She didn't develop complications of microstomia or necrosis in the flaps (Figure 5A&5B). Deltopectoral flap pulling away at 3 weeks postoperatively (Figure 6A&6B). She was subsequently treated with adjuvant radiation commencing one month after surgery. External radiotherapy was performed in the fields of her primary cancer and bilateral neck. She could eat a soft diet with occasional mild drooling of saliva.



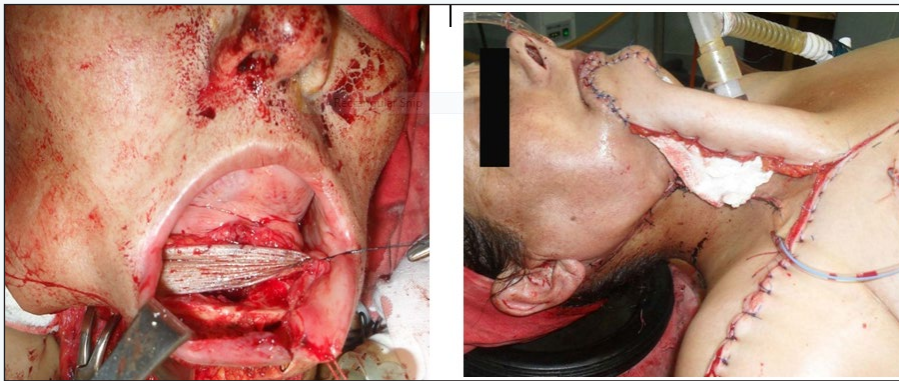
**Figure 1A:** Pre-operative view.  
**Figure 1B:** Intraoperative view.



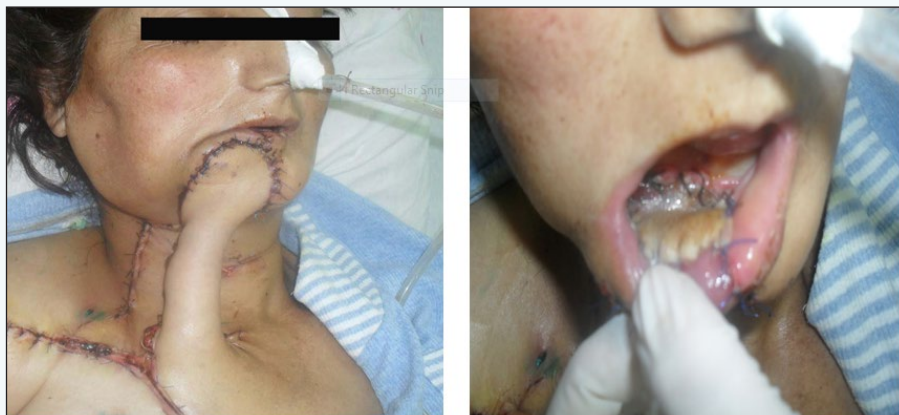**Figure 2:** Head and neck computer tomography (CT) examination of patient.



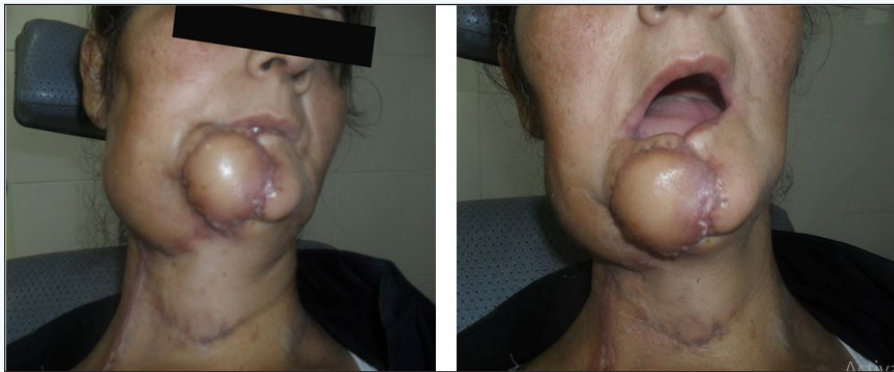**Figure 3A:** Intra-operative after en bloc resection (frontal view) deltopectoral flap and cervical flap figures.  
**Figure 3B:** Lateral view, cervical flap rotated to oral cavity for recon floor of mouth.



**Figure 4A:** Immediate post-operative view after simultaneous reconstruction of lower lips and diagram showed local flaps coverage. Cervical flap rotated to oral cavity for recon floor of mouth.  
**Figure 4B:** Immediate post-operative view after simultaneous reconstruction of lower lips and diagram showed local flaps coverage. For recon lower lip skin defect and can be divided after 3 weeks.



**Figure 5A:** Two weeks post-operative.  
**Figure 5B:** Interoral view.



**Figure 6A:** One month post-operative.

**Figure 6B:** Interoral view.

## Discussion

Defects after surgery of the lips may be classified into upper lip, lower lip, and oral commissure. SCC of the lip usually involves the upper or lower lip and oral commissure, but the behavior of SCC in this case was different. The defects in this case involved two parts of the lip, reconstruction was a challenge and there is no gold standard. Reconstructive lip surgery aims to restore function, obtain a watertight-seal, maintain sensation and avoid cosmetic deformity. Many methods are available for the reconstruction of lower lip defects such as the 'stair case' technique [7], and the Schuchardt [6], Karapandzic [8], Bernard [9], Webster techniques [10]. The principle of lip defects involves reconstruction with the remaining or opposite lip but there are no existing studies that describe simultaneous reconstruction of both upper and lower lips. In large defects involving both upper and lower lips, it is difficult to achieve all the goals of lip reconstruction but we desired to achieve both an oncologic and reconstructive outcome. In our case, we used a local flap in the reconstruction of both areas in a patient with SCC, a technique that has never been reported. Although, in advanced stages of SCC, microsurgery is recommended and popular, no 'gold standard' exists for large reconstructions of lower lip and right buccal area, especially in SCC. Local flaps still provide a predictable method to reconstruct perioral defects following resection for oral cancer [11]. We suggest this method as another option following the step ladder of reconstruction. The main drawback of this technique is the soft tissue volume that may shrink after radiation therapy. However, we believed that the advantages of this technique are two-stage operation, less donor site morbidity and less surgical time. Complications in such as this operation included cervical and deltopectoral flaps necrosis and microstomia. In this case we didn't have these and although, we could save this patient, the patient had a better quality of life. In our case, we used a cervical and deltopectoral flaps in the reconstruction of both areas in a patient with SCC of buccal mucosa involved lower lip mucosa and skin. Although, in advanced stages of SCC, microsurgery is recommended and popular, no 'gold standard' exists for large reconstructions of lower lip and right buccal area, especially in

SCC. Local flaps still provide a predictable method to reconstruct perioral defects following resection for oral cancer [11,12]. We suggest this method as another option following the step ladder of reconstruction. The main drawback of this technique is the soft tissue volume that may shrink after radiation therapy. However, we believed that the advantages of this technique are two-stage operation, less donor site morbidity and less surgical time. Complications in such as this operation included cervical and deltopectoral flaps necrosis and orocutaneous fistula. In this case we didn't have these and although, we could save this patient, the patient had a better quality of life.

## Conclusion

SCC is one of the most common malignant tumors but SCC involving near total upper lip, lower lip and oral commissure is rarely seen. In our patient SCC grew along the mucosal surfaces and the tumor could spread along the orbicularis oris and cervical muscles. Therefore, we report advanced SCC involving lower lip, left commissure and extending to the right buccal area treated with simultaneous resection and reconstruction with local flaps, a technique that has never been reported.

## References

1. Shah JP (1990) Color atlas of head and neck surgery. Wolfe Med Pub Ltd, Barcelona, Spain, pp. 9.
2. David LL (2006) Tumors of the Lips, Oral Cavity and Oropharynx. In: Mathes SJ (Ed.), Plastic Surgery. (2<sup>nd</sup> edn), Saunders Elsevier, Philadelphia, USA, pp. 159-180.
3. Zitsch RP, Park CW, Renner GJ, Rea JL (1995) Outcome analysis for lip carcinoma. *Otolaryngol Head Neck Surg.* 113(5): 589-596.
4. Lesavoy MA (1981) Lip deformities and their reconstruction. In: Lesavoy MA (Ed.), Reconstruction of the head and neck. William & Wilkins, Baltimore, USA, pp. 95.
5. Johanson B, Aspelund E, Breine U, Holmstrom H (1974) Surgical treatment of non-traumatic lower lip lesions with special reference to the step technique. A follow-up on 149 patients. *Scand J Plast Reconstr Surg* 8(3): 232-240.
6. Schuchardt K (1954) Operationen im Gesicht und im kieferbereich Operationen an den Lippen. In: Beer A, et al. (Eds.), Chirurgische Operationslehre. Leipzig, JA Barth, Germany.

7. American Cancer Society (2003) Cancer Facts and Figures.
8. Karapandzic M (1974) Reconstruction of lip defects by local arterial flaps. *Br J Plast Surg* 27(1): 93-97.
9. Bernard C (1853) Cancer de la levre inferieure opera par un procede nouveau. *Bull Mem Soc Chir Paris* 3: 357.
10. Webster RC, Coffey RJ, Kelleher RE (1960) Total and partial reconstruction of the lower lip with innervated musclebearing flaps. *Plast Reconstr Surg Transplant Bull* 25: 360-371.
11. Terry A. Day, Douglas A Girod (2006) Oral cavity reconstruction, CRC Press, New York, USA.
12. Closmann JJ, Pogrel MA, Schmidt BL (2006) Reconstruction of perioral defects following resection for oral squamous cell carcinoma. *J Oral Maxillofac Surg* 64(3): 367-374.