

The Dentist First and Last

Emad Toto*

Prosthodontist at Private Dental Clinic, Syria

Submission: March 05, 2016; **Published:** May 04, 2016

***Corresponding author:** Emad Toto, Prosthodontist, Former assistant lecturer Damascus University, Syria. Syria, Tel: 00963947405557; Email: dr-emadtoto@hotmail.com

Case report

Have you ever thought that, you forgot something very important while achieving your goal. In deed all of us we like to be proud of doing and achieving our treatment plan, but also all of us we are human being and we could have mistakes. Is that enough, no not at all, we should realize our mistake and solve it. 22 years old female patient got ortho treatment and end it before 18 months. 3 months later patient got swelling on the left side. Follow up with her dentist assured that, there is nothing with her upper left teeth. Patient advised by dentist to get E.N.T specialist consult who has given huge amount of antibiotics and 2 days later drainage done beside her nose. Few days' later pus started coming from the same area and since that day pus not stop. Many dentists, E.N.T specialists and dermatologists can't find out what or where is the source of that pus and without any result. Some of doctors advised her to go for a graft and some others apply coaterly to same area which becomes dark, opened with pus and with bad smell. One and half year passed with her complication and without any hope of healing. Lastly patient came with her mother and starting giving her complaint. Always there are basics for our treatment plans to be achieved as well as we planed and one of these basics is light continuous moves, follow up with X Ray during ortho treatment is required. Panorama x ray requested and so easy the diagnosis was found. Patient had 23 necrotic pulp with periapical abscess and little swelling related to 23 not diagnosed well and unnecessary and wrong drainage and in wrong area done lead to easy fistula established beside her nose for 16 months. 23 root canal access done without any kind of anesthesia and completely necrotic pulp tissue removal done. R.c.t protocol with only normal saline and antibiotic described. Few days' later pus and fistula foramen started to disappear. After session #40 enlargements achieved and calcium hydroxide applied to the root canal. 2 weeks later pus and fistula completely disappeared. Nothing to be compared to her smile when she got hope to be healed after many doctors and many diagnosis. [Figure1to 6] Dentist started and other dentist ends it.

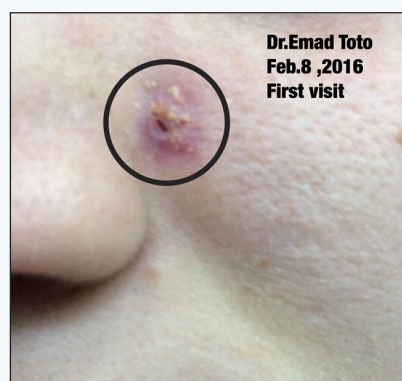


Figure 1: Emad Toto February 8, 2016 First visit.

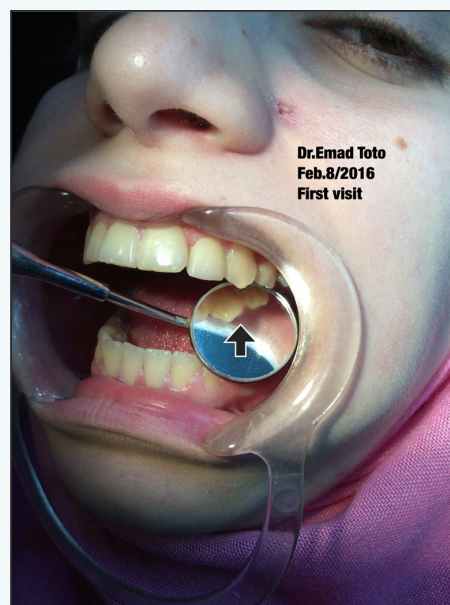

Figure 2: Emad Toto February 8, 2016 First visit.

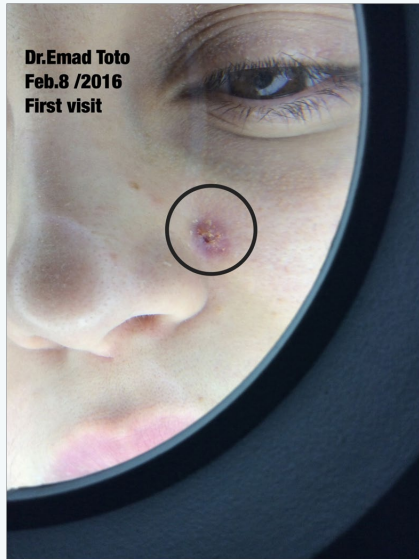

Figure 3: Emad Toto February 8, 2016 First visit.

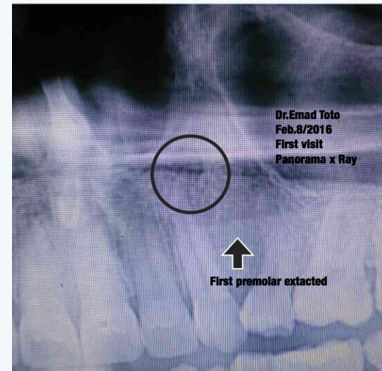


Figure 5: Emad Toto February 08, 2016 first visit Panorama X ray.

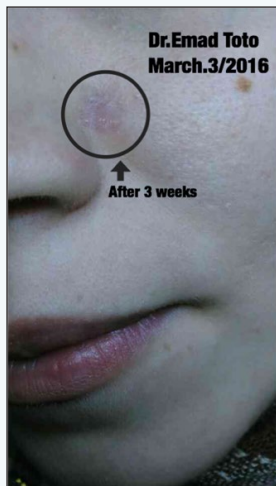


Figure 4: Emad Toto March 03, 2016 visit after 3 weeks.

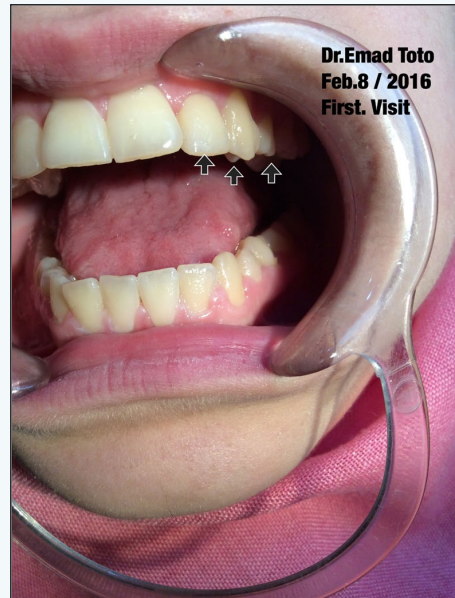

Figure 6: Dr. Emad Toto February 8, 2016 First visit.