



Case Report

Volume 15 Issue 2 - March 2022
DOI: 10.19080/ADOH.2022.15.555910

Adv Dent & Oral Health

Copyright © All rights are reserved by Morittu S

The Importance of the Management of the Orthodontic-Pedodontic Patient: A Case Report



Morittu S*

Dental Hygienist, Private Practice, Silanus, Sardinia, Italy

Submission: February 27, 2022; Published: March 09, 2022

*Corresponding author: Morittu S, Dental Hygienist, Private Practice, Silanus, Sardinia, Italy

Abstract

The absence of oral care during orthodontic treatment in childrens is the main cause of most of the damage to the hard and soft tissues of the oral cavity. The incidence of enamel demineralization (ortodontico white spot lesions) and caries need oral preventive-personalized paths. Professional oral hygiene, instructions for home-oral hygiene, fluoride and sealing. Many studies confirm that "the presence in the mouth of orthodontic fixed and/or mobile device scan compromise plaque control". With this case report, I want to demonstrate how the intervention of the dental hygienist is necessary to preserve the state of oral health in the oral cavity during orthodontic treatment.

Keywords: Enamel demineralization; Plaque control; White Spot lesions

Introduction

The clinical case (Figure1) concerns a patient of 10 years who comes to my attention in a very good state of general health but with a compromised oral health. The patient has been carrying fixed orthodontics for more than two years at another dental office, where, in addition to not being present the figure of the dental hygienist, she has never been given professional oral hygiene and has not been explained to her the operations of professional oral hygiene in the presence of orthodontic equipment. The clinical examination and the history have shown a lack of knowledge of the importance of oral hygiene in the presence of orthodontic equipment, no professional oral hygiene by the former operator, instruction in maneuvers and home hygiene. As a professional in the health of oral hygiene I set myself the goal of transmitting this concept, to show the patient the critical issues in her oral cavity and motivate her to improve the situation and with it the health of both hard and soft tissues (Figure 1).

Case Report

The patient is submitted to the documentation of the case through intra-oral photos, both with out and with the use of the plaque-detector (useful to provide the patient with visual evidence of the presence of both plaque and tartar, which the naked eye could not identify). With the mirror and the picture of the teeth,

brackets and bands with the plate detector I start my session of motivation and instruction (Figure 2 & 3).

The plaque-detector allows me to show the patient the areas where she cannot clean well, in pink is highlighted the plaque of "young age" (recent residues, less than 24h), in dark purple/blue the old residues, and in "blue/ green", plaque residues with acidogenic activity, which is responsible of "White Spot lesions" post orthodontics. I proceed with the use of the electric toothbrush, to show the patient that an "electric" device with the suitable head can facilitate the cleaning of the teeth [1-6].

Results

I see the patient after one month from the first session of oral hygiene, document the progress achieved (Figure 4 & 5), reinforcing the motivation with photos that show the improvements obtained with greater care in home hygiene combined with professional treatments. The patient showed that she was very careful to scrupulously perform the oral hygiene protocols at home customized for her. The use of technologies such as photography and plaque detector, allowed me to motivate the patient and show the effects of plaque and tartar in hard and soft tissues;

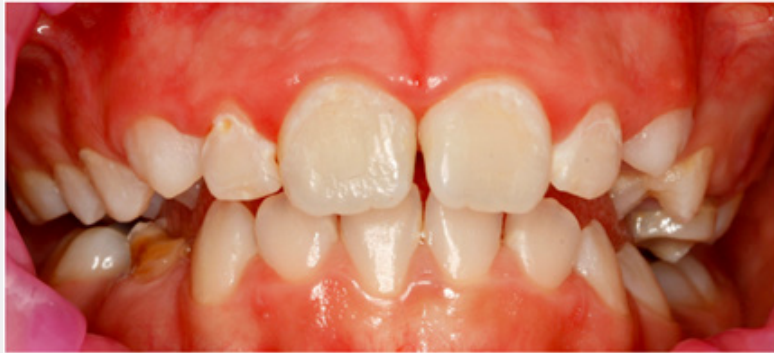

Figure 1

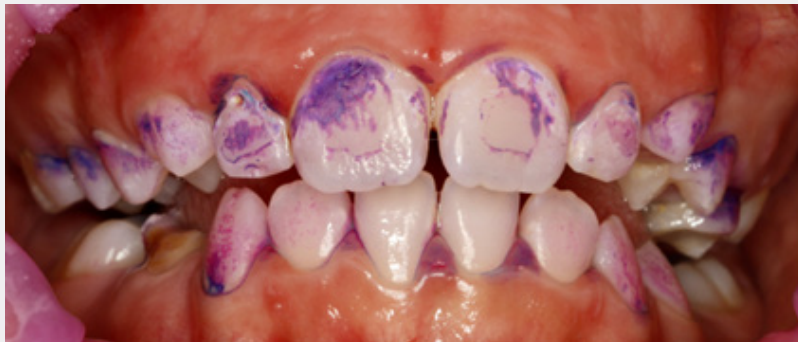

Figure 2

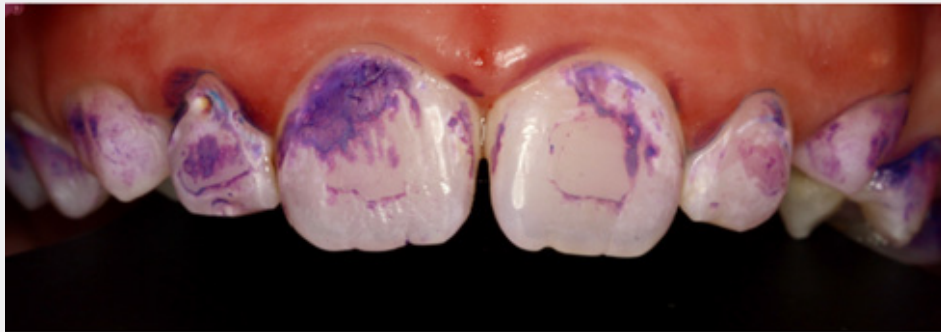


Figure 3

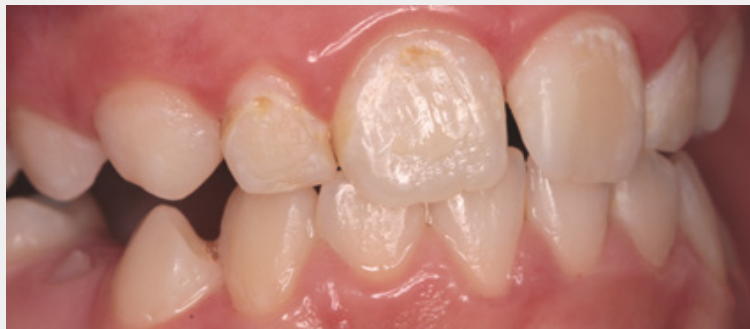

Figure 4

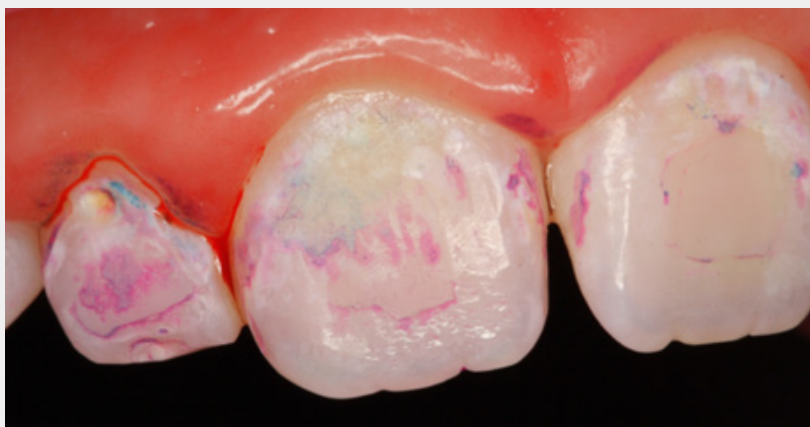

Figure 5

a) Airflow, ultrasound with modulating power allowed me to work on the patient without her experiencing pain.

b) Professional products have allowed me to restore integrity to dental enamel and reduce post-hygiene bleeding.

c) Home hygiene devices specially designed for patients with fixed orthodontics have facilitated cleaning at home (Figure 4 & 5).

Conclusion

The management of this case has supported the evidence that in the absence of management in oral hygiene, the damage to hard and soft tissues will be evident. With an adequate knowledge of both the instruments and the devices at home we are able to intercept and direct patients towards a better oral health path for them so that, once the orthodontic therapy is finished: gingival tissues returns to a state of optimal health, hard tissues are improved but require conservative dentistry. Every patient in orthodontic therapy should be helped by the dental hygienist pre, during and post orthodontic therapy.

References

1. Huang J, Yao Y, Jiang J, Li C (2018) Effects of motivational methods on oral hygiene of orthodontic patients: A systematic review and meta-analysis. *Medicine (Baltimore)* 97(47): e13182.
2. Khoroushi M, Kachuie M (2017) Prevention and Treatment of White Spot Lesions in Orthodontic Patients. *Contemp Clin Dent* 8(1): 11-19.
3. Zabokova-Bilbilova E, Popovska L, Kapusevska B, Stefanovska E (2014) White spot lesions: prevention and management during the orthodontic treatment. *Pril (Makedon Akad Nauk Umet Odd Med Nauki)* 35(2): 161-168.
4. Panagiotou A, Rossouw PE, Michelogiannakis D, Javed F (2021) Role of Essential Oil-Based Mouthwashes in Controlling Gingivitis in Patients Undergoing Fixed Orthodontic Treatment. A Review of Clinical Trials. *Int J Environ Res Public Health* 18(20): 10825.
5. Schou L (2000) The relevance of behavioural sciences in dental practice. *Int Dent J* pp. 324-332.
6. Migliorati M, Isaia L, Cassaro A, Rivetti A, Silvestrini-Biavati F, et al. (2015) Efficacy of professional hygiene and prophylaxis on preventing plaque increase in orthodontic patients with multibracket appliances: a systematic review. *Eur J Orthod* 37(3):297-307.



This work is licensed under Creative Commons Attribution 4.0 License
DOI: [10.19080/ADOH.2022.15.555910](https://doi.org/10.19080/ADOH.2022.15.555910)

Your next submission with Juniper Publishers will reach you the below assets

- Quality Editorial service
- Swift Peer Review
- Reprints availability
- E-prints Service
- Manuscript Podcast for convenient understanding
- Global attainment for your research
- Manuscript accessibility in different formats
(Pdf, E-pub, Full Text, Audio)
- Unceasing customer service

Track the below URL for one-step submission
<https://juniperpublishers.com/online-submission.php>