



**Case Report**

Volume 4 Issue 1 – March 2017  
DOI: 10.19080/AJPN.2017.04.555685

Acad J Ped Neonatol

Copyright © All rights are reserved by Byron Alexis Pacheco-Mendoza

# Gross Hematuria Post-Pieloplasty as Single Manifestation of Primary Renal Candidiasis

**Pacheco-Mendoza Byron A<sup>1\*</sup>, David Mejía-Camacho<sup>2</sup> and Realpe<sup>1</sup>**

<sup>1</sup>Department of Pediatric Surgeon and Pediatric Urology, Centro Médico Nacional "20 de Noviembre" ISSSTE, Mexico

<sup>2</sup>Department of Pediatrics, Hospital General de Cabo San Lucas, Mexico

**Submission:** February 05, 2017; **Published:** March 28, 2017

**\*Corresponding author:** Byron Alexis Pacheco-Mendoza, Monrovia 302-206, Portales Norte, Benito Juárez, 06720, Mexico City, Mexico, Tel: +52 5552005003, Ex: 14315, +5215548707834; Email: urochild@gmail.com

## Abstract

Primary Renal Candidiasis (PRC) has been described in pre-term and term newborn hospitalized in neonatal intensive care units (NICU). A risk factor for PRC is hydronephrosis. The aim of this paper is to present the case of a toddler suffering from PRC without hospitalization in intensive care units, and with gross hematuria postpieloplasty.

A 3 year-old male was admitted in the hospital with fever and gastrointestinal vomiting. The diagnosis of hydronephrosis by ureteropelvic junction obstruction was established. Treatment with ceftriaxone and nephrostomy guided by ultrasonography (US) was applied. Three months later, pyeloplasty and pigtail placement were carried out. Two weeks after postpyeloplasty, the patient presented gross hematuria, with secondary anemia (Hb 6.5g/dl). Urine cultures positive for *Candida albicans*. US renal report fungoma of 7x5mm in left kidney. Management was done with fluconazole at 6 mg/kg/day by 6 weeks. Currently asymptomatic.

**Keywords:** Gross hematuria; Renal candidiasis; Pyeloplasty

**Abbreviations:** PRC: Primary Renal Candidiasis; US: Ultrasonography; KBUS: Kidney-Bladder-Ultrasonography; APD: Anterior-Posterior Diameter; NORA: Normalised Residual Activity; DRF: Differential Renal Function

## Introduction

Primary renal candidiasis (PRC) has been described previously [1]. Preterm newborn have risk factors for developing systemic or non-systemic candidiasis, because they are subject to intravenous broad spectrum antibiotics, parenteral nutrition, central venous catheters; among other factors. An important history in these patients is the presence of hydronephrosis [2].

The main clinical manifestation reported in the PRC has been anuria or oliguria secondary to mycetomas, fungomas obstructing the ureteropelvic junction, especially in pre-term patients [3,4].

The aim of this paper is to present the case of a toddler with PRC manifested by gross hematuria postpyeloplasty and being an outpatient.

## Case Report

A 3 year-old male patient, no report of prenatal hydronephrosis, with no relevant prenatal and perinatal history. Fever of 39 °C, 48 hours of evolution and gastrointestinal vomiting.

## Physical examination

Palpable mass on the left flank, painful, mobile, non-stony.

## Laboratories

Hematic biometry: Leukocytes 16,340/ul, neutrophils 88%. Blood chemistry: Serum creatinine 0.26 mg / dl. Uroanalysis: Leukocyte esterase (+), countless leukocytes.

## Work-up

Kidney-Bladder-Ultrasonography (KBUS): Left kidney with severe hydronephrosis with pelvis of 350 ml, anterior-posterior diameter (APD) pelvic of 75mm, renal parenchyma thinned (4mm).

Diuretic renography with 99mTcMAG-3: Normalised residual activity (NORA) at 60 minutes >1 in the left kidney with 39% of differential renal function (DRF).

Based on these results, we decided to perform nephrostomy and intravenous (IV) treatment with ceftriaxone for 14 days, thus resolving the infectious condition.

Three months later, Anderson Hynes pyeloplasty and pigtail catheter placement were performed. After 24 hours postsurgery, there were no complications, no incidents or accidents.

## Evolution

After two weeks post-pyeloplasty, he presents gross hematuria with clots, without abdominal pain. During physical examination with heart rate (HR) of 125bpm, abdomen without bleeding in surgical wound, no hematomas, no palpable mass.

## Laboratories

Hb: 6.5g/dl, hematocrit 19%, leukocytes 4300/ul, platelets 188,000/ul TP: 14.2, TTPa: 38.5, Urine culture: 48-hour without bacterial growth.

## Work-up

KBUS with APDpelvic of 48 mm, no evidence of renal pelvic clots, no retroperitoneal extra-renal collections.

We decided to hospitalize with absolute rest, red blood cells were transfused; he was discharged from hospital at 48 hours without hematuria.

After 8 weeks post-pyeloplasty, a pigtail catheter was removed by cystoscopy.

After 10 weeks post-pyeloplasty, there was gross hematuria again, without clots, without symptomatic anemia.

## Laboratories

Urinalysis: countless haematocytes, no crenocytes, no urine proteins. Urine culture: Report at 48 hours candida albicans.

Abdominal US to search fungomas: Two hyperechoic images in left renal parenchyma of 7x5 mm and 3x3 mm, without acoustic shadow suggestive of mycetomas (Figure 1).

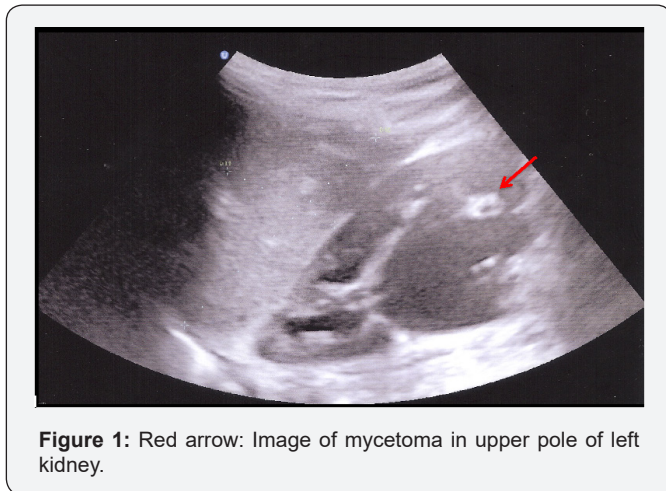


Figure 1: Red arrow: Image of mycetoma in upper pole of left kidney.

## Doppler echocardiogram: Normal.

Management with fluconazole 7 days IV and then 5 weeks oral.

Actually in the last follow-up at 12 months after the antifungal treatment, the patient was asymptomatic with negative urinalysis and urine cultures, KBUS with residual image of 3x4mm in left kidney.

## Discussion

PRC has been reported in term infants [5], preterm infants [6] and, infants [7], commonly in intensive care units; but we do not know of reports in a toddler as in the case that we are reporting.

Due to the use in the intensive care rooms, of broad spectrum antibiotics, intravascular devices and parenteral nutrition, among other factors, fungic systemic or localized infections have been increasing [8,9]. But our patient does not belong to this group of inpatients; he is a patient diagnosed from the outpatient clinic. Most of the reported cases of PRC in children have as a common denominator, the presence of ipsilateral hydronephrosis [10], similar to our patient; but also we added a risk factor that was the use of nephrostomy for 3 months, which undoubtedly contributed to the colonization of the kidney by candida.

PRC can manifest as pyelonephritis and/ or mycetomas [11]. In children we do not know of reports of pyelonephritis (PN) as the only manifestation, but we do of PN plus mycetomas [10], or mycetomas at the ureteropelvic junction causing anuria or oliguria [12,13]. The patient in the study, did not have obstruction of the urinary tract, he had gross hematuria with acute anemia. We found reports in adults of macroscopic hematuria in PRC [14], but according to the review in the world literature this is the first case reported with this clinical manifestation in toddler.

The diagnosis of PRC has been established by ultrasonography (US), retrograde pyelography, excretory urography, anterograde pyelography and tomography [15]. The most used method is the US. We established the diagnosis by US, and also followed up with US.

The treatment of primary renal candidiasis is based on antifungal agents, the mostly used are fluconazole, amphotericin and flucytosine [16,17]; we used fluconazole for 6 weeks with complete resolution of symptom and mycetomas.

For the cases of obstructive uropathy secondary to mycetomas, several treatments have been described, such as percutaneous nephrostomy [18], percutaneous extraction of mycetomas with thrombectomy devices [19]; none of these procedures was necessary to use in our patient; gross hematuria finished with oral fluconazole treatment.

## Conclusion

This is the first report of a child with primary renal candidiasis, manifested with anemising gross hematuria post-pyeloplasty. We present this manifestation of primary renal candidiasis to be considered in the differential diagnosis of a patient with hematuria and history of pyeloplasty with chronic use of nephrostomy.

## References

1. Pappu LD, Purohit DM, Bradford BF, Turner WR, Levkoff AH (1984) Primary renal candidiasis in two preterm neonates. Report of cases and review of literatura on renal candidiasis in infancy. *Am J Dis Child* 138(10): 923-926.

2. Matsumoto AH, Dejter SW, Barth KH, Gibbons MD (1990) Percutaneous nephrostomy drainage in the management of neonatal anuria secondary to renal candidiasis. *J Pediatr Surg* 25(12): 1295-1297.
3. Eckstein CW, Kass EJ (1982) Anuria in a newborn secondary to bilateral ureteropelvic fungus balls. *J Urol* 127(1): 109-110.
4. Laufer J, Reichman B, Graif M, Brish M (1986) Anuria in a premature infant due to ureteropelvic fungal bezoars. *Eur J Pediatr* 145(1-2): 125-127.
5. Babut JM, Coeurdacier P, Bawad F, Treguier C, Fremont B (1995) Urinary fungal bezoars in children—report of two cases. *Eur J Pediatr Surg* 5(4): 248-252.
6. Devile CJ, Ogilvie D (1992) Renal candidiasis in the preterm infant. *Arch Dis Child* 67(10 Spec No): 1244.
7. Hitchcock RJ, Pallet A, Hall MA, Malone PS (1995) Urinary tract candidiasis in neonates and infants. *Br J Urol* 76(2): 252-256.
8. Abdallah Y, Kaddu-Mulindwa D, Nankunda J, Musoke PM (2015) Prevalence and immediate outcome of candida colonized preterm neonates admitted to special care unit of Mulago Hospital, Kampala Uganda. *Afr health Sci* 15(1): 197-205.
9. Gholamipur P, Mahmoudi S, Pourakbari B, Ashtiani MT, Sabouni F, et al. (2014) Candiduria in children: a first report from an Iranian referral pediatric. *J Prev Med Hyg* 55(2): 54-57.
10. Hajouz S, Dafiri R (2014) Renal candidal bezoar: case report and review of the literature. *Arch Pediatr* 21(1): 70-72. [Article in French].
11. Fisher JF, Sobel JD, Kauffman CA, Newman CA (2011) Candida urinary tract infections--treatment. *Clin Infect Dis* 52(Suppl 6): S457-S466.
12. Visser D, Monnens L, Feitz W, Semmekrot B (1998) Fungal bezoars as a cause of renal insufficiency in neonates and infants--recommended treatment strategy. *Clin Nephrol* 49(3): 198-201.
13. Yoo SY, Namkoong MK (1995) Acute renal failure caused by fungal bezoar: a late complication of candida sepsis associated with central catheterization. *J Pediatr Surg* 30(11): 1600-1602.
14. Napodano RJ, Bansal S (1980) Gross hematuria: a rare manifestation of primary renal candidiasis. *Postgrad Med* 67(3): 253-257.
15. Sadegi BJ, Patel BK, Wilbur AC, Hhosla A, Shamim E (2009) Primary renal candidiasis. Importance of imaging and clinical history in diagnosis and management. *J Ultrasound Med* 28(4): 507-514.
16. Abele-Horn M, Kopp A, Sternberg U, Ohly A, Dauber A, et al. (1996) A randomized study comparing fluconazole with amphotericin B/5-flucytosine for the treatment of systemic candida infections in intensive care patients. *Infection* 24(6): 426-432.
17. Triolo V, Gari-Toussain M, Casagrande F, Garraffo R, Dageville C, et al. (2002) Fluconazole therapy for candida albicans urinary tract infections in infants. *Pediatr Nephrol* 17(7): 550-553.
18. Matsumoto AH, Dejter SW, Barth KH, Gibbons MD (1990) Percutaneous nephrostomy drainage in the management of neonatal anuria secondary to renal candidiasis. *J Pediatr Surg* 25(12): 1295-1297.
19. Shich MC, Leung DA, Roth JA, Hagspiel KD (2005) Percutaneous extraction of bilateral renal mycetomas in premature infant using mechanical thrombectomy device. *Urology* 65(6): 1226.



This work is licensed under Creative Commons Attribution 4.0 License  
DOI: [10.19080/AJPN.2017.04.555685](https://doi.org/10.19080/AJPN.2017.04.555685)

### Your next submission with Juniper Publishers will reach you the below assets

- Quality Editorial service
- Swift Peer Review
- Reprints availability
- E-prints Service
- Manuscript Podcast for convenient understanding
- Global attainment for your research
- Manuscript accessibility in different formats  
( Pdf, E-pub, Full Text, Audio)
- Unceasing customer service

Track the below URL for one-step submission  
<https://juniperpublishers.com/online-submission.php>