

Cavum Septi Pellucidiet Vergae: Anatomic Finding and Review

Luiz Reis Barbosa Júnior* and Adalmir Morterá Dantas

Faculty of Medicine of Health Sciences Center, Federal University of Rio de Janeiro, Brazil

Submission: March 17, 2016; **Published:** April 11, 2016

***Corresponding author:** Luiz Reis Barbosa Junior, Faculty of Medicine of Health Sciences Center, Carlos Chagas Filho Biophysics Institute, Universidade Federal do Rio de Janeiro, Rua Rodolpho Paulo Rocco 255, Cidade Universitária, Ilha do Fundão, Rio de Janeiro - RJ - Brazil, Tel: (55 21) 96900-0027; Email: luiz_reis@hucff.ufrj.br

Abstract

The authors discuss in this article about the cavum septi pellucidi and cavum Vergae. The septum pellucidum is a transparent part of two laminae that extends from the anterior part of the body (the genu) to the superior surface of the fornix. The development of the septum pellucidum occurs from the primitive lamina terminalis which forms the anterior wall of the telencephalic cavity. The article presents a mini-review on the subject and it includes information about their embryology and anatomic findings.

Keywords: Anatomy; Cavumseptumpellucidum; Cavumseptipellucidi; Cavumvergae; Verga's Ventricle

Embryology of the Septum

Derived from the lateral part of the terminal bar, firstly, the septum binds to the frontal direction, always separated from the pallial part by a ventricular groove, a septum-cortical fissure. This pre commissural part of the septum has a considerable thickness, especially in lower mammals. As with the reptiles, their cells are grouped into two nuclei, the septi nuclei dorsolateral and ventromedial. It contains the fibers that ascend to the hippocampus (olfactory hippocampal fibers or olfactory bundle of the septum). The pre commissural part continues backward, below the corpus callosum and over the foramen of Monro. This supra foraminal of the septum contains the fibers fornicae and cortico-habenulae. The extension of the corpus callosum allows an extension of the septum, whose pre commissural part is reduced as the measure that increases the frontal extension of the corpus callosum, while the supra foraminal suffers a stretching and a reduction still more important, as a result of the posterior displacement of the Amon horn. Such septum extension implies in its reduction to a fine membrane, the septum pellucidum of a man. Among the septal nucleus, the ventro medial nucleus, located in front of the anterior commissure, only maintains a remarkable volume. The bilateral septi can suffer coalescence or even a concrescence so that the arachnoid space, a septum cavity located between the septi of both sides, disappears. This process is almost normal in its posterior part. On the other hand, an increase of the arachnoid fluid can cause an expansion of the interseptal sub callosal

space, including its posterior part, which, then, is transformed and becomes the cavity named Verga. However, it is evident that these cavities do not have any normal communication with the cerebral ventricles [1-3].

Anatomy of the Septum

The septum, in the ventromedial portion of the hemispheres of the forebrain, is differentiated in all vertebrates [4]. The septum pellucidum of man is composed of two thin leaves of gliotic tissue with occasional scattered neurons. The leaves may be fused, but an interseptal space, the cavum septi pellucidi, persists in 85 per cent of normal adult as a small slit or large space [5]. This interseptal space is lined by the ependyma [6] and it is often connected with the ventricular system, as known by the frequency of filling with air during pneumoencephalography, even in neonates [7]. A combination of the theories would explain the histological nature of the septal leaves as neural tissue lined by ependyma and derived from the lamina terminalis the cavum septi pellucidi may be continuous with the third ventricle, or the laminae terminalis may completely separate the cavum from the anterior end of the ventricle: the open cavum septi pellucidi described by Thompson [8] as occurring in ungulates, carnivorous, and primates, was really the recess beneath the frontal end of the corpus callosum [9]. The human septum pellucidum is absent in association with agenesis of the corpus callosum [10] and is intimately related to and dependent upon the proceeding and concomitant growth of the corpus callosum

during embryogenesis [11,12].

The Ventricular System

The ventricular system is constituted from the cavities of the cerebral vesicles and the medullar tube. All the ventricular system is intercommunicated, demonstrating its origin of a common cavity, the neural tube cavity. The changes of the cavities are due to an uneven growth of the vesicles and their walls. At the level of the medullar tube, the growth is restricted and the walls suffer a large thickening. Consequently, the cavity becomes relatively thin and will constitute the ependymal channel. At the level of the rhombencephalon we will have an expanded cavity, in spite of the pronounced growth of the walls which will constitute the floor (medulla oblongata and pons) and the roof (cerebellum) - the 4th ventricle. The caudal portion of the roof of the 4th ventricle is formed by the plate of the miencephalon roof, which is stretched and consisted of few spongioblasts layers - is the coroidal plate of the 4th ventricle. At the level of the mesencephalon, the growth of the walls is relatively larger than that of the cavity, becoming reduced to a channel of small diameter - the cerebral aqueduct, which connects with the 4th and 3rd ventricles. At the level of the diencephalon it was observed that there is a large growth of the lateral walls, forming the thalamic region, while the cavity is reduced to a narrow sagittal cleft - the 3rd. Ventricle. Its roof remains thin with some thick cellular layers - the coroidal layer of the 3rd ventricle. Below the corpus callosum a thin membrane is observed named septum pellucidum (transparent septum), located between the corpus callosum and the trigon. It has a triangular form and in its inner lodging a small cavity which is named (wrongly named) the fifth Verga's ventricle. In the telencephalon the situation is more complex due to the appearance of the hemispheric vesicles and the primitive cavity is unfolded into two cavities, in a wide communication with the 3rd. Ventricle - they will be the lateral ventricles. Later the communication will be reduced, and the lateral ventricles start to communicate with the 3rd, through two holes - they are the inter ventricular holes. The regions where the hemispheric vesicles are limited with the diencephalic floor remain thin, constituting the choroidal plates of the lateral ventricles.

Anatomic Case

After the dissection of the encephalon in a cadaver of a man, we observed in anatomic cuts the Verga's ventricle (Figure 1). The pathology and the image of the septum pellucidum and the Verga's ventricle are an anatomic rarity. The "cavum of the septum pellucidum" is a cavity filled with the cerebrospinal fluid which is situated between the frontal horns of the lateral ventricles. The "cavum Vergae" is a posterior digitiform extension elongated from the cavum septum pellucidum which is located among the fornices. The cavum septum pellucidum can occur in an isolated manner, however, the cavum Vergae only occurs in conjunction with the cavum septum pellucidum. When the two occur, the correct Latin nomenclature is cavum septi

pellucidiet Vergae. In the daily use, the combination usually is called cavum of the septum pellucidum [13]. The septi pellucidi are two paired triangular membranes ("leaflets") which develop approximately with 12 weeks of gestational age. The embryonic septi pellucidi are not fused, and the cavity between them is filled with cerebrospinal fluid. This simple cavity between the two leaflets receives two different names. Anterior to the foramen of Monro it is called "cavum of septum pellucidum". The posterior continuation between the fornices is called "cavum Vergae". Normally, the two septi pellucidi fuse, and the cavity between them is obliterated. The fused membranes become the septum pellucidum. The presence of the cavum of the septum pellucidum usually is asymptomatic and is an alteration of the type "don't touch", found accidentally in the image exams. The computed tomography and the magnetic resonance imaging of these two entities show a cleft cavity not much visible and a prominent collection measuring various millimeters in diameter. In rare cases, these pathologies exceptionally increased determine an expansive effect, displacing laterally the fornices and the leaflets of the septi pellucidi. Those two pathologies should not be confused with a "cavum velum interpositum", which is the space of the triangular cerebrospinal fluid, thin, which recovers the thalamus and the third ventricle. The "cavum velum interpositum" usually occurs without the cavum septi pellucidi.

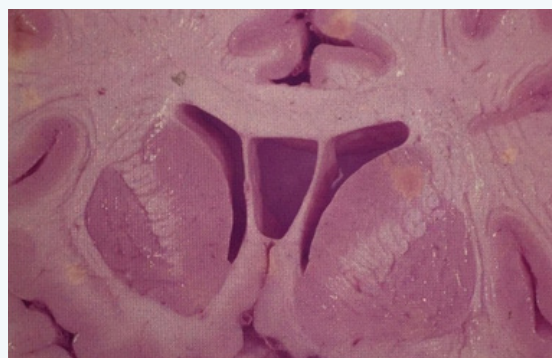


Figure 1: Septum Pellucidum and Verga's ventricle in anatomic cuts after dissection of the encephalon in a cadaver of a man.

Conflict of Interest

The authors declare that they have no financial interest or any conflicts of interest in this research.

References

1. Oppel A (1914) *Leiftadenfür das EmbryologischePraktikucu und Grundrib der Entwicklungslehre des Menschen und der Wirbeltiere*. Jena: Verlag von Gustav Fischer, pp. 313.
2. Arey LB (1965) *Developmental Anatomy. A textbook and laboratory manual of embryology*. W.B. Saunders Company, Philadelphia, USA, pp. 695.
3. Larsen WJ (1993) *Human Embryology*. New York: Churchill Livingstone, USA, pp. 479.
4. Sarnat MB, Netsky M (1974) *Evolution of the nervous system*. New York: Oxford University, USA, pp. 248-249.

5. Hughes RA, Kerndian JW, Craig WM (1955) Caves and cysts of the septum pellucidum. *AMA Arch Neurol Psychiatry* 74(3): 259-266.
6. Liss L, Mervis L (1964) The ependymal lining of the cavum septi pellucid: A histological and histochemical study. *J Neuropathol Exp Neurol* 23: 355-367.
7. Larroche JC, Baudey J (1961) Cavum septi lucidi, cavum Vergae, cavum veli interpositi: cavities of the median line. Anatomical and pneumoencephalographic study in the neonatal period. *Biol Neonat* 3: 193-236.
8. Thompson IM (1932) On the cavium septi pellucidi. *J Anat* 67(Pt 1): 59-77.
9. Abbie AA (1939) The origin of the corpus callosum and the fate of structures related to it. *J Comp Neurol* 70: 12-44.
10. Kirschbaum WR (1947) Agenesis of the corpus callosum and associated malformations. *J Neuropathol Exp Neurol* 6(1): 78-94.
11. Kappers CUA (1947) *Anatomie comparée du système nerveux*. Paris, Masson, 347.
12. Rakic P, Yakovlev PI (1968) Development of the corpus callosum and cavum septi in man. *J Comp Neurol* 132(1): 45-72.
13. Osborn AG (2014) *Encéfalo de Osborn. Imagem, patologia e anatomia*. Porto Alegre: Artmed 1018-1019.