



Case Report

Volume 3 Issue 4 – December 2017  
DOI: 10.19080/APBIJ.2017.03.555620

Anatomy Physiol Biochem Int J

Copyright © All rights are reserved by Aranka Ilea

# Aesthetic Facial Reconstruction Using Eye Epitheses: A Case Report



Aranka Ilea<sup>1\*</sup>, Cosmin Vâjâean<sup>1</sup>, Horațiu Bălescu<sup>2</sup>, Radu Septimiu Câmpian<sup>1</sup>

<sup>1</sup>"Iuliu Hațieganu" University of Medicine and Pharmacy Cluj-Napoca, Department of Oral Rehabilitation, Oral Health and Dental Office Management, Romania

<sup>2</sup>"Victor Babeș" University of Medicine and Pharmacy Timișoara Aranka Ilea and Cosmin Vâjâean have an equal contribution as first authors of the article.

**Submission:** November 11, 2017; **Published:** December 01, 2017

**\*Corresponding author:** Aranka Ilea, "Iuliu Hațieganu" University of Medicine and Pharmacy, Faculty of Dental Medicine, Cluj-Napoca, Romania, Victor Babeș Street, no. 15, Cluj-Napoca, Romania Tel: +40746151210; Email: arankailea@yahoo.com, aranka.ilea@umfcluj.ro

## Abstract

Facial defects affect the quality of life of patients. The loss of the eyeball causes important damage both through the loss of visual acuity and aesthetic facial defects. For an adequate aesthetic reconstruction, these patients need a personalized eye epithesis to restore their physiognomy and offer them a better quality of life. Eye epitheses restore the aesthetic appearance, but not function, and their construction depends on the skills of the anaplastologist. This paper presents the case of a patient who underwent aesthetic reconstruction using an eye epithesis. A patient aged 44 years presented to the Anaplastology Laboratory for the reconstruction of an eyeball defect. After the clinical examination, the impression was taken and sent to the laboratory. The working model was fabricated and after the construction of the wax model, the iris was painted. The reconstruction was artificially vascularized and the prosthesis was polished. The prosthesis was placed in the eye cavity and the patient was asked to perform eye movements in all directions and various facial movements. The opening of the palpebral fissure was verified. Eye epitheses made in the laboratory are superior to prefabricated epitheses, because they are personalized and adapted to each individual patient. Eye epithesis, aesthetic facial reconstruction, anaplastology, eye prosthesis, eyeball defects.

## Introduction

Eye epitheses are foreign physical bodies that replace the entire eyeball or part of it, restoring the defect from an aesthetic point of view. These epitheses only play a physiognomic role, as patients use them for their social integration. The causes of eyeball defects fall under two categories: congenital and acquired Schoen et al. [1], Wagenblast et al. [2]. Ionizing radiation, chemotherapy, and/or surgery are used for the treatment of oromaxillofacial cancer, but they may result in the disfiguration of the patient, followed by a decrease in the quality of life. This is why subsequent aesthetic reconstruction is as important as treatment itself Oh et al. [3], Miles et al. [4].

The loss of the orbital contents is most frequently the consequence of trauma or tumor processes. Facial traumas often have an impact on the orbital contents. Traumas can be confined to the orbit or they may exist in the context of various facial trauma. Important sequelae occur in penetrating wounds of the orbit, the penetration of orbital foreign bodies and the formation of retrobulbar hematoma Fini et al. [5]. Primary malignant tumors of the orbit may have their origin in various tissues found at this level: nerve, muscle, bone, cartilage, fibrous, adipose, lymphoid

and hematogenic tissues. The orbit can also be invaded by malignant neoplasms that develop in adjacent structures (eyelids, lacrimal sac), in the neighboring cavities (sinuses, nasopharynx) or in the endocranium.

They extend to the orbit through bone effraction or from near to near. In the orbit, metastatic tumors with a starting point in different tissues and organs of the body can also be located. The onset of the disease manifests by fetid serosanguinolent secretions in the nostril on the affected side, palpebral edema, periorbital pain, headaches. In more advanced phases, the tumor is externalized to the eyelids, the skin is infiltrated, it becomes red-purple and ulcerated. In the majority of the cases, treatment consists of orbital exenteration. Exenteration consists of the removal of the entire contents of the orbit (eyelids, eyeballs, related organs). In the defect, skin grafts or a pedicled temporal flap are applied at the level of the temporal artery.

Children may also present different substance defects following surgery. Frequently, in retinoblastoma cases, the removal of the contents of the orbit is required, and the defect can be reconstructed using an eye prosthesis. At the age of 4-5 years

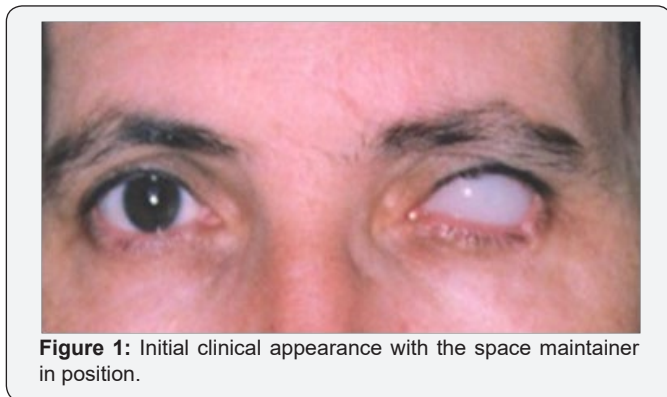or when the child becomes cooperative, a definitive epithesis will be made. Eye epitheses are classified according to several criteria: from the point of view of the material from which they are made (glass epitheses, plastic epitheses), depending on the execution procedure (prefabricated epitheses, epitheses made in the laboratory). The aim of this paper is to present the way in which a personalized eye epithesis is designed and made in the anaplastology laboratory.

## Methods

Patient B.S., aged 44 years, presented to the Anaplastology Laboratory on the recommendation of the surgeon for the reconstruction of an eyeball defect, resulting after a trauma produced by a chainsaw in November 2009. The material used in the laboratory for the reconstruction of the eyeball was thermally polymerized and auto-polymerized acrylic resin.

This has different colors, depending on the elements that it needs to reproduce.

## Clinical examination



The lack of substance and the absent organ were evaluated, and the construction of an intraorbital prosthesis was recommended by the surgeon (Figure 1). The usefulness of the prosthesis was assessed depending on the status of soft tissues, subadjacent bone and facial mobility during facial mimicry.

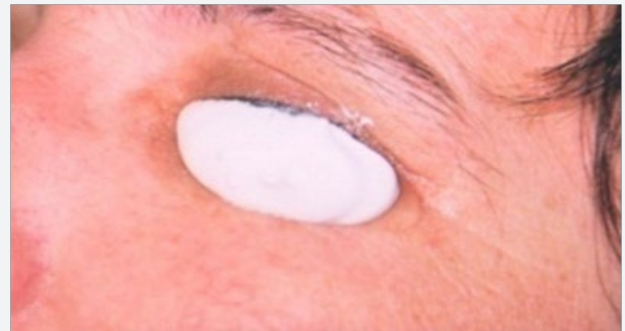In the same session, the patient's record was drawn, which included the following:

- a. iris diameter= 11.9mm
- b. pupil diameter= 3-3.5mm (during exposure to light and dark)
- c. color of the healthy eye= brown with greenish hues and radial iridescences (No. 2)
- d. color of the sclera= A12
- e. density and position of vascularization= 2-4
- f. depth of the sac= 9-11mm
- g. eyelid opening= 18mm

Photographs taken before the accident (front and profile) were analyzed in order to obtain an aesthetic restoration.

## Impression

### Partial impression technique (Figure 2)



**Figure 2:** Impression stage.

The patient was in dorsal decubitus, for an easy and correct handling of the impression material. The impression tray was chosen depending on the degree of lack of substance. The soft tissues were cleaned with a gauze pad and their status was assessed: on the outside, the eyelids had a normal appearance, without essential changes in volume or shape; the inferior and superior fornices were favorable for prosthetic restoration; the mucosa had no ulcerations, and cicatrization was adequate. By correlating anamnestic data with objective examination data, it was found that this patient had a medium size defect. The surrounding tissues were isolated with petroleum ointment. The impression material was prepared (CA 37 FAST SET was used) according to the user's instructions: one measure of fast setting alginate and one measure (special graduated cup) of water.

The mixing of these two components resulted in a creamy mixture, which was introduced in a syringe, avoiding the formation of air bubbles. The impression material was injected in the eye cavity starting from the internal angle of the eyelid, following the trajectory of the inferior fornix and, without removing the syringe, the superior fornix was also outlined, then the internal angle was regained. During this time, the patient was asked to look at a fixed point with her healthy eye, in order to avoid the deformation of the impression. After the setting of the material, the impression was removed carefully and was sent to the laboratory.

## Fabrication of the working model

Hard plaster was prepared and poured into a conformator. The impression was introduced with the posterior side into the plaster so that it exceeded the impression tray margins by 2mm. After the setting of the material, 4 plaster guides were made and the first part of the model was isolated with petroleum ointment. A new plaster amount was prepared and poured over the first part of the model. After the setting of the material, the two parts of the model were detached and the impression was removed.

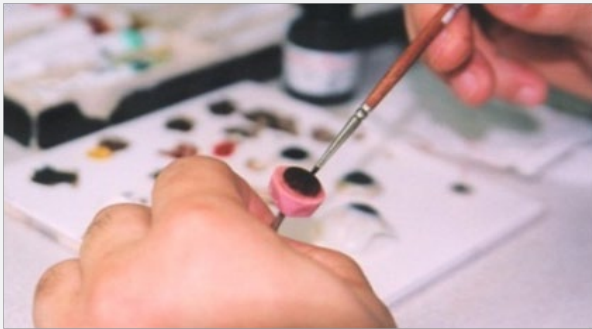## Construction of the wax pattern

Both parts of the model were isolated with petroleum ointment and the wax pattern was made by was dripping inside the

model through the orifice created in the upper part (the palpebral fissure). The model was reassembled before the cooling of the wax and was maintained under pressure until its cooling. The model was detached, the wax pattern was removed and was smoothed manually.

At the site where the position of the pupil was approximated (slightly eccentric, towards the nasal angle), a convexity was made by wax dripping. After the completion of the wax pattern, a silicone putty conformator was made, by pressing a putty layer on the convex side of the wax pattern, in which after setting, an orifice was made in the upper part. After placing the conformator on the model, without the wax pattern, white auto-polymerized acrylic resin was introduced through the orifice, into the space between the conformator and the model. The wax pattern, obtained after the removal of the putty, was processed and finished.

### Painting of the iris



**Figure 3:** Painting of the iris.

The discs for painting the iris were chosen based on the data of the patient's record. The color of the healthy eye was brown with greenish hues. The first disc was made from a brown plate, 0.2mm larger compared to the iris diameter (11.9mm), which was covered with white thermally polymerized acrylic resin, for a smooth transition between the two colors. A support was attached to the first disc, which facilitated handling during painting. The second disc, made of transparent acrylic resin, had a black round spot in the middle, 3.5mm in diameter, corresponding to the pupil. During the iris painting session, the patient's presence was necessary, and this stage was carried out under natural lighting conditions. First, the background (the basic color) was made, which was brown, obtained from black + orange + brown (Figure 3).

Then, the iris rays were painted, using a thinner brush, in various greenish hues, obtained following combinations of the basic colors. The control of the colors was performed using a water drop placed on the surface of the colored disc, in order to establish contact between the two discs and to facilitate the visualization of the painted color and its comparison with the color of the healthy eye. The two discs reconstructing the iris were glued with transparent thermally polymerized acrylate. On the surface of the painted disc, an auto-polymerized acrylate

pyramid was made, which represented the key for the positioning of the disc in the mould. The two discs were packed in hard plaster (Moldano).

### Flasking of the wax pattern with the iris in position

The flasking mass (hard plaster) was prepared and poured in the first half of the flask, where the wax pattern was positioned up to the maximum diameter. After the setting of the material, the plaster and the wax pattern were isolated using separating solution. The second half of the flask was placed over the first half and a new amount of mixed plaster was cast by vibration, until the flask was filled. After setting, the flask was maintained under pressure for five minutes, then, its two parts were separated and the mould was isolated.

Before using the acrylic resin, the iris disc margin was trimmed with a bur so that the acrylate could advance higher on the iris following pressure, and after processing and finishing, the appearance of diffuse transition outside the contour could result. The iris was repositioned using the acrylic pyramid and was glued to the mould for an accurate fixation. The acrylic resin was prepared according to the manufacturer's instructions, and the shade matching the color of the healthy eye was selected using the color key. It was introduced in the mould and maintained under pressure. The acrylic resin was polymerized (by boiling for 1 hour).

### Deflasking

After polymerization, the resulting epithesis was deflasked, after which 1 mm of its surface was trimmed with a bur, in order to make room for the transparent acrylic resin and the reconstructed vascularization.

### Vascularization Reconstruction

In order to reproduce vascularization, a red cotton thread split into three was used. The three threads were introduced in the monomer to obtain the appearance of small veins, and they were positioned on the epithesis surface using the pliers. The artificial vascularization was fixed on the epithesis surface with transparent acrylic resin (Palasil, SR, 3/60, DENTURE - BASE), applied in a thin layer.

### Flasking for the polymerization of the transparent acrylic resin

The transparent thermally polymerized acrylate was cured in the same mould used for the flasking of the wax pattern. The resulting epithesis was deflasked and processed.

### Finishing of the prosthesis

The epithesis was processed using acrylic burs, by reducing all irregularities on its surface. In the first stage, motor polishing was performed with a brush and quartz (in water), after which it was continued with a brush and paste (the final aspect of the eye epithesis can be seen in (Figure 4).

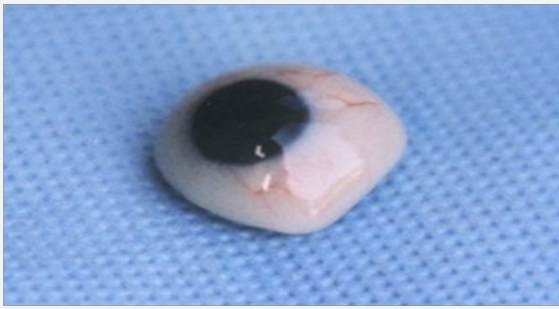


Figure 4: Final aspect of the epithesis.

## Results

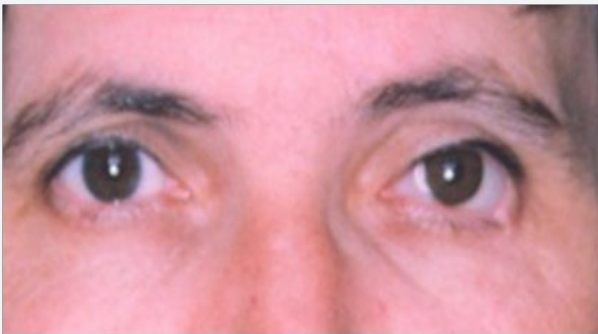

Figure 5: Final clinical aspect with the epithesis in position.

The prosthesis was placed in the eye cavity and the patient was asked to perform eye movements in all directions and various facial movements. The opening of the palpebral fissure was verified (Figure 5). The patient was also informed about how to insert, use and clean the eye prosthesis. The evolution of the case was favorable both regarding the adaptation of the patient to the eye epithesis and aesthetic appearance.

## Discussion

The reconstruction of orbital defects is and will remain a responsible and demanding medical task. Regardless of the reason of exenteration, at all clinical and clinical-technical stages of restoration, the doctor and technician use a wide diversity of biomaterials on a provisional or long term basis. The anaplastologist must prove a certain level of knowledge; he/she must be able to rapidly elaborate logical rationales and to choose the best solutions from multiple possibilities. Due to the psychological impact of an eyeball defect on the patient, eye epitheses are accepted with enthusiasm, although they meet only physiognomic, not functional requirements. The prosthetic reconstruction of orbital defects raises complex problems regarding the

adjustment of the future epitheses, their aesthetic appearance and physiological integration- problems that have no pre-established solutions, as each clinical case represents a particular situation, for which an adequate solution must be found.

This is why compared to prefabricated eye prostheses, prostheses made in the laboratory have the great advantage of being individualized, from the color of the iris, its striations, the light or opacity spots and vascularization to the general shape of the epithesis. The only advantage in the case of prefabricated prostheses is that of immediate prosthetic restoration. In specialized clinics, there are kits with such prostheses, which although available in a wide spectrum of colors and sizes, very rarely succeed in perfectly reproducing the healthy eye, and the alterations are perceived in an unfavorable manner by patients and their entourage. The choice of the therapeutic solution should take into account not only the competence of the anaplastologist, but also the material and technical equipment of the laboratory, the patient's financial possibilities, as well as the patient's cooperation with the specialist during the restoration.

## Conclusion

The construction of an adequate eye epithesis, particularly in terms of aesthetic appearance, is extremely important for a successful reintegration of patients in society and for the continuation of their activities, ensuring in this way a satisfactory quality of life.

## Acknowledgment

Aranka Ilea and Cosmin Văjăean have an equal contribution as first authors of the article.

## References

1. Schoen PJ, Raghoobar GM, Van Oort RP, Reintsema H, Van der Laan BF, et al. (2001) Treatment outcome of bone-anchored prostheses after tumor surgery. *Cancer* 92(12): 3045-3050.
2. Wagenblast J, Baghi M, Helbig M, Arnoldner C, Bisdas S, et al. (2008) Craniofacial reconstructions with bone-anchored epithesis in head and neck cancer patients- a valid way back to self perception and social reintegration. *Anticancer Res* 28(4C): 2349-2352.
3. Oh WS, Roumanas E, Beumer J 3<sup>rd</sup> (2007) Maxillofacial restoration after head and neck tumor therapy. *Compend Contin Educ Dent* 28(2): 70-76.
4. Miles BA, Sinn DP, Gion GG (2006) Experience with cranial implant-based prosthetic reconstruction. *J Craniofac Surg* 17(5): 889-897.
5. Fini G, Frontero L, Cascino F Mici E, Pellacchia V, Carini ML (2011) Fronto-orbito-zygomatic trauma with eyelid involvement *J Craniofac Surg* 22(4): 1287-1293.



This work is licensed under Creative Commons Attribution 4.0 License  
DOI: [10.19080/APBIJ.2017.03.555620](https://doi.org/10.19080/APBIJ.2017.03.555620)

## Your next submission with Juniper Publishers will reach you the below assets

- Quality Editorial service
- Swift Peer Review
- Reprints availability
- E-prints Service
- Manuscript Podcast for convenient understanding
- Global attainment for your research
- Manuscript accessibility in different formats ( Pdf, E-pub, Full Text, Audio)
- Unceasing customer service

Track the below URL for one-step submission

<https://juniperpublishers.com/online-submission.php>