



Review Article

Volume 5 Issue 2 - May 2018
DOI: 10.19080/APBJ.2018.05.555657

Anatomy Physiol Biochem Int J
Copyright © All rights are reserved by Mete Özdikici

Volumetric Evaluation of the Paranasal Sinuses with the Cavalieri Method



Mete Özdikici*

Department of Radiology, Bakirköy Training and Research Hospital, Turkey

Submission: April 23, 2018; Published: May 25, 2018

*Corresponding author: Mete Özdikici, Department of Radiology, Bakirköy Training and Research Hospital, İstanbul, Turkey, Tel: 00905065309467; Email: meteozdikici@hotmail.com

Abstract

Objectives: Our aim was to estimate the volumes of paranasal sinuses with Cavalieri principle.

Materials and Methods: The volumes of paranasal sinuses were estimated using the Cavalieri principle with coronal CT scans of 125 (68 male and 57 female) cases ranged from 18 to 75 years and analyzed by gender and age. The right-left comparison was also researched.

Results: The mean volumes (\pm S.D.) of unilateral sinuses were 6.0 ± 4.3 , 19.1 ± 6.1 , 5.7 ± 1.5 and 7.1 ± 3.9 cm³ for the frontal, maxillary, ethmoidal and sphenoidal sinuses, respectively. The volumes of paranasal sinuses were significantly different between the sexes ($P < 0.05$). There was no statistically significant difference between the right and left sinuses. However, the volume of paranasal sinuses gradually decreased after the third decade.

Conclusion: In this study, it is thought that the data obtained using the Cavalieri method will be useful in distinguishing between normal and pathological paranasal sinus volumes.

Keywords: Paranasal sinuses; Computerized tomography; Cavalieri method; Volume

Introduction

Various diseases, especially infections, can lead to changes in the volume of paranasal sinuses. Treatment methods, such as functional endoscopic sinus surgery, require knowledge of the detailed anatomy and volumes of the paranasal sinuses. Consideration of age-related changes in the size of paranasal sinuses is useful in detecting possible abnormalities [1-5]. In this study, we estimated the volume of paranasal sinuses using the Cavalieri principle on Computerized Tomography (CT) images. We also evaluated the effect of aging on the size of the paranasal sinuses.

Materials and Methods

The volumes of the paranasal sinuses were estimated by coronal CT scans in 125 (68 male and 57 female) cases. The ages of the patients ranged from 18 to 75 years. This study, approved by the Ethics Committee, was performed retrospectively and included patients who underwent paranasal sinus tomography due to any cause, but no pathological findings were detected. In the course of about 2 years, the cases that I evaluated normally were selected. The slice thickness on the CT images was 3-5 mm without a gap. Volume measurements are made by using a transparent template to overlay a grid of regularly spaced points

over CT scans of randomly selected patients (Figure 1). Square grid test systems with two different point densities ($d = 0.2, 0.3$) between test points can use to estimate the total volume of the paranasal sinuses.

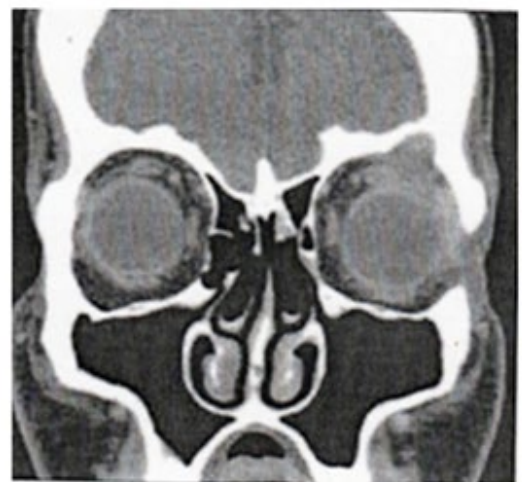
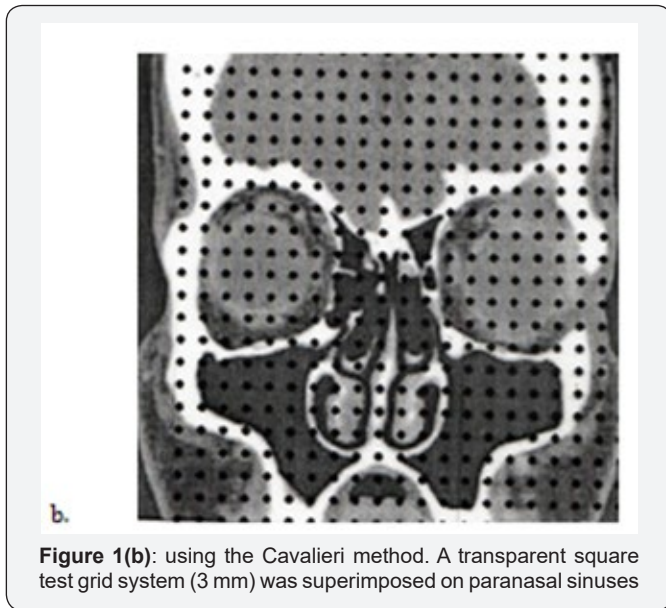


Figure 1(a): Estimation of the volumes of paranasal sinuses



The choice of point density in the grid so that 100 to 300 points were counted for each CT study consistently yielded Coefficients of Error (CE) of 5% or less in volume measurements. This point is counted as the full contact of the counter. Counts are made three times. The double or middle number is used. The volume of an object appearing on a scan (V) is the product of the sum of points that fell on the object (ΣP_i), the area associated with each point (ap), and the distance between scan slices (t) in cubic centimeters. $\{V = \Sigma P_i \cdot ap \cdot t\}$. The statistical analysis was done by myself using the SPSS/PC version 15.0 package program. The volumes of sinuses were compared between the genders. It was analyzed in relation to age. The right-left comparison was also investigated. Pearson's correlation test was used for the evaluation of the effects of aging on the size of paranasal sinuses.

Results

The mean volumes ($\text{cm}^3 \pm \text{S.D.}$) of four paranasal sinuses in males and females are shown in Table 1. The mean volumes of unilateral sinuses were 6.0 ± 4.3 , 19.1 ± 6.1 , 5.7 ± 1.5 and $7.1 \pm 3.9 \text{ cm}^3$; the mean volumes of bilateral sinuses were 12.5 ± 0.9 , 37.2 ± 1.4 , 11.9 ± 0.4 and $13.8 \pm 0.8 \text{ cm}^3$ for the frontal, maxillary, ethmoidal and sphenoidal sinuses, respectively. The total volume of all four paranasal sinuses was 82.1 ± 22.1 and $66.1 \pm 14.6 \text{ cm}^3$ for males and females, respectively. The paranasal sinuses of female subjects were 20% smaller than those of males. The mean CE of the volume estimates was 5%. The volumes of paranasal sinuses were significantly different between the sexes ($P < 0.05$). There was no statistical difference between the sides in either sex ($P > 0.05$). The volumes are higher at 20 years of age and then gradually decrease. There was a negative correlation with age on the total volume of all four sinuses ($r = -0.240$; $P < 0.05$).

Table 1: The mean volumes ($\text{cm}^3 \pm \text{S.D.}$) of four unilateral paranasal sinuses.

Sinus	Male	Female
Frontal	6.6 ± 4.7	5.4 ± 3.9
Maxillary	21.0 ± 6.7	17.2 ± 5.4
Ethmoidal	6.2 ± 1.7	5.1 ± 1.3
Sphenoidal	7.9 ± 4.3	6.4 ± 3.5
Total	82.1 ± 22.1	66.1 ± 14.6

Discussion

The paranasal sinuses consist of the frontal, maxillary, ethmoidal, and sphenoidal sinuses [2]. Because of the allergic and infectious diseases of the paranasal sinuses and nasal cavity, the sinonasal region is often radiologically imaged. It is important to know the paranasal sinus volumes in diagnosis, treatment, and follow-up of diseases such as infection, hypoplasia, sinus atelectasis, pneumosinus dilatans. Treatment methods, such as functional endoscopic sinus surgery, require that the volumes and detailed anatomy of the paranasal sinuses be well-known [1,3-6]. If a CT computer is not available for digital volumetric detection of lesions, the ellipsoid and Cavalieri methods may be an alternative. The Cavalieri estimator is more time consuming, although more reliable than the ellipsoid method [7,8].

Volume measurements from standard CT scans with the Cavalieri estimator can be made easily. It is suitable for daily clinical practice and is free of charge. This technique, which can be quickly applied with a portable transparent template, allows retrospective or prospective studies [6,9]. In our study, we combined the Cavalieri principle of stereological methods with CT scanning technique. The sum of the points that fell on the object, ΣP_i , was then multiplied by the area associated with each point, $ap \text{ (cm}^2\text{)}$, and the distance between slices, $t \text{ (cm)}$, to arrive at the volumes of related structures and organs, $V \text{ (cm}^3\text{)}$. $\{V = \Sigma P_i \cdot ap \cdot t\}$ [9]. The choice of point density in the grid so that 100 to 300 points were counted for each CT study consistently yielded coefficients of error of 5% or less in our tumor volume measurements [6-10]. In our study, the mean CE of estimates was 5%.

The mean CE of frontal, maxillary, ethmoidal and sphenoidal sinuses were 6%, 3%, 5% and 5%, respectively. The unilateral mean volumes of frontal, maxillary, ethmoidal and sphenoidal sinuses were 6.0 ± 4.3 , 19.1 ± 6.1 , 5.7 ± 1.5 and $7.1 \pm 3.9 \text{ cm}^3$, respectively. Maxillary sinuses have the largest volume. In most of the studies it was determined that the paranasal sinus volumes were higher in males than females, these volumes decreased with age and the side difference was not significant [1-3,6,11-14]. In some rare studies, this difference between men and women is

not statistically significant [15]. Our results also showed that the volumes of all paranasal sinuses are larger in males ($P < 0.05$). The paranasal sinuses of female subjects were 20% smaller than those of males. There was no statistically significant difference between the right and left paranasal sinuses ($P > 0.05$). It also revealed that the total volume of paranasal sinuses has a negative correlation with the age that means the paranasal sinus volume tends to decrease by the age of subjects ($r = -0.240$; $P < 0.05$).

Conclusion

In cases where the volumes of the paranasal sinuses are changing, it is important to know the normal volume limits if surgical treatment methods are needed. If there is no CT computer system, the measurement of paranasal sinus volumes obtained from CT scans using the Cavalieri principle can be evaluated as a practical and useful method. Moreover, the studies on the volume of all paranasal sinuses are extremely limited in the literature and it is clear that there is a need for new data to establish a standard in this respect. We think that our study will contribute to the formation of a standard in volume determination of paranasal sinuses.

References

1. Yonetsu K, Watanabe M, Nakamura T (2000) Age-related expansion and reduction in aeration of the sphenoid sinus: volume assessment by helical CT scanning. *AJNR Am J Neuroradiol* 21(1): 179-182.
2. Kawarai Y, Fukushima K, Ogawa T, Nishizaki K, Gunduz M, et al. (1999) Volume quantification of healthy paranasal cavity by three-dimensional CT imaging. *Acta Otolaryngol Suppl* 540: 45-49.
3. Arijji Y, Arijji E, Yoshiura K, Kanda S (1996) Computed tomographic indices for maxillary sinus size in comparison with the sinus volume. *Dentomaxillofac Radiol* 25(1): 19-24.
4. Urken ML, Som PM, Lawson W, Edelstein D, Weber AL, et al. (1987) Abnormally large frontal sinus. II. Nomenclature, pathology, and symptoms. *Laryngoscope* 97(5): 606-611.
5. Adams WM, Jones RI, Chavda SI, Pahor AL, Taifa KT (1998) Pneumosinus dilatans: a discussion of four cases and the possible aetiology. *Rhinology* 36(1): 40-42.
6. Emirzeoglu M, Sahin B, Bilgic S, Celebi M, Uzun A (2007) Volumetric evaluation of the paranasal sinuses in normal subjects using computer tomography images: A stereological study. *Auris Nasus Larynx* 34(2): 191-195.
7. Roberts N, Puddephat MJ, McNulty V (2000) The benefit of stereology for quantitative radiology. *Br J Radiol* 73(871): 679-697.
8. Stocchetti N, Croci M, Spagnoli D, Gilardoni F, Resta F, et al. (2000) Mass volume measurement in severe head injury: accuracy and feasibility of two pragmatic methods. *J Neurol Neurosurg Psychiatry* 68(1): 14-17.
9. Clatterbuck RE, Sipos EP (1997) The Efficient Calculation of Neurosurgically Relevant Volumes from Computed Tomographic Scans Using Cavalieri's Direct Estimator. *Neurosurgery* 40(2): 339-343.
10. Garden AS, Roberts N (1996) Fetal and fetal organ volume estimations with magnetic resonance imaging. *Am J Obstet Gynecol* 175(2): 442-448.
11. Karakas S, Kavakli A (2005) Morphometric examination of paranasal sinuses and mastoid air cells using computed tomography. *Ann Saudi Med* 25(1): 41-45.
12. Uchida Y, Goto M, Katsuki T, Akiyoshi T (1998) A cadaveric study of maxillary sinus size as aid in bone grafting of the maxillary sinus floor. *J Oral Maxillofac Surg* 56(10): 1158-1163.
13. Rani SU, Rao GV, Kumar DR, Sravya T, Sivaranjani Y, et al. (2017) Age and gender assessment through three-dimensional morphometric analysis of maxillary sinus using magnetic resonance imaging. *J Forensic Dent Sci* 9(1): 46.
14. Cohen O, Warman M, Fried M, Shoffel Havakuk H, Adi M, et al. (2017) Volumetric analysis of the maxillary, sphenoid and frontal sinuses: A comparative computerized tomography based study. *Auris Nasus Larynx* 45(1): 96-102.
15. Sanchez Fernandez JM, Anta Escuredo JA, Sanchez Del Rey A, Montoya FS (2000) Morphometric study of the paranasal sinuses in normal and pathological conditions. *Acta Otolaryngol* 120(2): 273-278.



This work is licensed under Creative Commons Attribution 4.0 License
DOI: 10.19080/APBIJ.2018.05.555657

Your next submission with Juniper Publishers will reach you the below assets

- Quality Editorial service
- Swift Peer Review
- Reprints availability
- E-prints Service
- Manuscript Podcast for convenient understanding
- Global attainment for your research
- Manuscript accessibility in different formats (Pdf, E-pub, Full Text, Audio)
- Unceasing customer service

Track the below URL for one-step submission
<https://juniperpublishers.com/online-submission.php>