

Portal Venous Gas in a Patient with End-Stage Renal Disease

Shane P Smith^{1*}, Omar Metwally² and Kevin Man²

¹Creighton University School of Medicine, USA

²St. Mary's Medical Center San Francisco, USA

Submission: November 12, 2015; **Published:** November 30, 2015

***Corresponding author:** Shane P Smith, Creighton University School of Medicine, 2500 California Plaza, Omaha, NE 68178, shanesmith@creighton.edu

Abstract

An 86-year-old man with end-stage renal disease presented with acute epigastric pain during a hemodialysis session. Computed tomography on admission demonstrated extensive gaseous distension of the portal venous system and signs of ileus without bowel necrosis. His constipation and portal venous gas (PVG) completely resolved with conservative management. While PVG can often signal impending decompensation in critically ill patients, it can also be observed in relatively benign processes and does not necessarily correlate with the acuity of illness. Its occurrence in patients undergoing hemodialysis may begin with a low-flow state, which can lead to ischemic injury.

Keywords: Portal venous gas; End stage renal disease; Non-occlusive mesenteric ischemia

Abbreviations: PVG: Portal Venous Gas; ESRD: End Stage Renal Disease; NOMI: Non Occlusive Mesenteric Ischemia

Introduction

Wolfe and Evans [1] first described portal venous gas in neonates on abdominal x-ray in 1955. Susman and Senturia [2] later described its presence in adults in 1960 using the same methods. PVG is a rare radiological finding that has been associated with high mortality and the need for urgent surgical intervention [3-5]. On computed tomography, PVG is defined as tubular areas of decreased attenuation with predominance in the left hepatic lobe [6,7].

Case Report

An 86-year-old man with a history of end stage renal disease (ESRD), coronary artery disease, and type II diabetes mellitus was undergoing hemodialysis when he experienced acute, severe epigastric abdominal pain, nausea, and vomiting. Dialysis was stopped, and the patient was transported to the emergency room. The patient had been undergoing outpatient hemodialysis for the past three years. He was admitted to the hospital three days prior for gross hematuria status post urethral stent placement while on clopidogrel and was discharged home two days prior on continuous bladder irrigation. His medications included amlodipine, carvedilol, ferrous sulfate, sitagliptin, clopidogrel, simvastatin, valacyclovir, tamsulosin and finasteride.

The patient was afebrile with a blood pressure of 91/50, a normal heart and respiratory rate, and saturating normally on room air. On physical exam he had hypoactive bowel sounds without tenderness, peritoneal signs, distension, nor organomegaly. Laboratory results revealed a white blood cell count of 11,000 cells/uL, hemoglobin 11.6 g/dL, BUN 27, creatinine 4.1 mg/dL, bicarbonate 27 mmol/L, and potassium 4.1 mmol/L.

CT scan of his abdomen and pelvis revealed gas throughout the portal venous system, ileus, and a left non-obstructing inguinal hernia. Figures 1A & B and 2A & B demonstrate large amounts of air in the portal venous vessels and bile ducts. The small and large bowels were dilated until the level of the rectum (Figure 2A and B).

The patient's abdominal pain completely resolved within one day, and he remained hemodynamically stable throughout his hospital course. He was initially started on piperacillin-tazobactam 3.375 g IV every six hours and resuscitated with normal saline. Repeat CT scan on hospital day five showed complete resolution of the portal venous gas (Figure 3A and B). The patient's diet was advanced as tolerated after he demonstrated normal bowel sounds and began passing flatus. Stool guaiac performed at this time was positive, hemoglobin

and hematocrit remained stable, and white blood cell count was 9,000 cells/uL. The patient was discharged on hospital day five with amoxicillin-clavulanate 500 mg PO three times a day to

finish a ten-day total course of antibiotics. He was also placed on pantoprazole 40 mg PO daily and referred for outpatient colonoscopy.

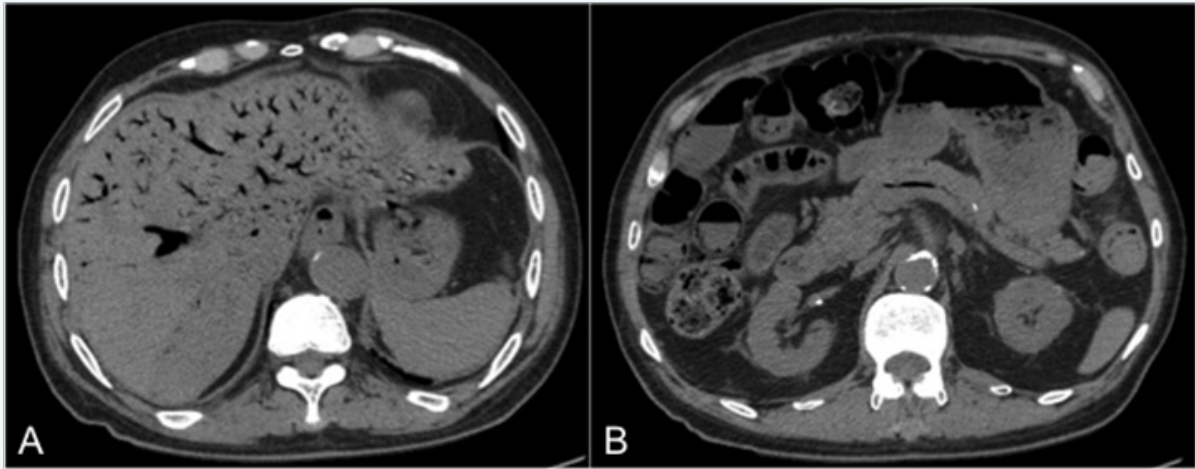


Figure 1: Non-contrast CT of the abdomen and pelvis on admission.

A. Axial view of the liver with extensive portal venous gas.

B. Axial view of the intestines demonstrating feces and air-fluid levels in the small bowel and gas within the large bowel wall without evidence of bowel necrosis.

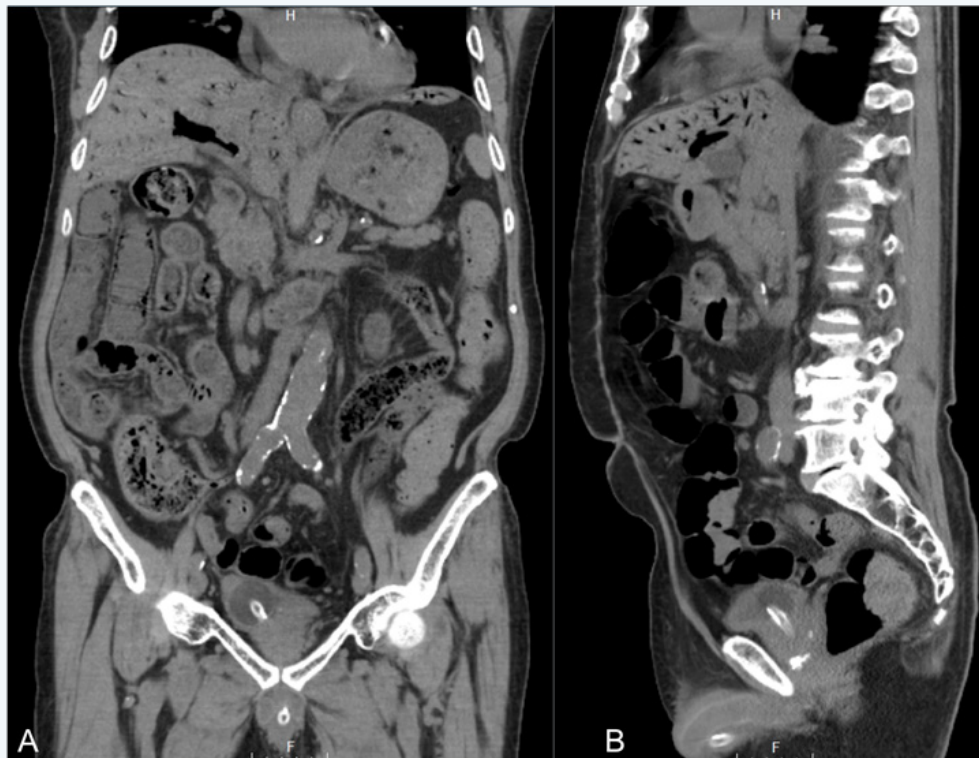

Figure 2: Non-contrast CT of the abdomen and pelvis on admission.

A. Coronal view of the liver showing extensive portal venous gas and the small and large bowel with a large amount of feces and fecalization of the small bowel.

B. Sagittal view of the liver showing extensive portal venous gas, large bowel containing stool and gas, and small bowel with air fluid levels.

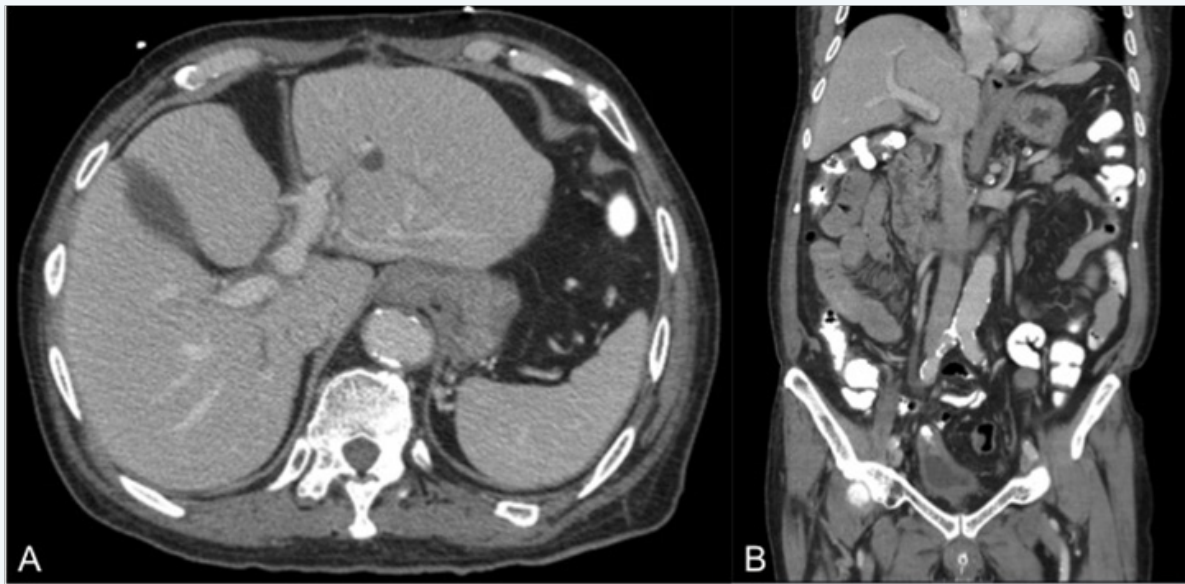


Figure 3: CT of the abdomen and pelvis with oral contrast on hospital day 6.

A. Axial view of the liver showing complete resolution of extensive portal venous gas.

B. Coronal view of the liver showing complete resolution of portal venous gas and resorption of bowel gas.

Discussion

PVG has been reported in a variety of conditions and is associated with a broad differential diagnosis. It has been seen in inflammatory bowel disease including ulcerative colitis and Crohn's disease, graft versus host disease, and cystic fibrosis [8-11]. It has also been associated with mechanical disorders of the bowel including obstruction, pseudo-obstruction, and paralytic ileus [12,13]. Iatrogenically, PVG has been reported with esophagogastroduodenoscopy, colonoscopy, endoscopic retrograde cholangiopancreatography, arterial catheterization, enemas, and radiofrequency tumor ablation [14-18].

Various mechanisms of gas entry into the portal venous system have been proposed, including ileus-related distension and disruption of the bowel mucosa and subsequent gas entry, mucosal damage due to ischemia or inflammation, and translocation of anaerobic gas-forming bacteria to the venous system [12,13,19]. The urgency and method of intervention in PVG depend upon the underlying disease process. Experts generally advocate urgent laparotomy when PVG is associated with signs of bowel necrosis or ischemia on CT, careful monitoring in cases of distension, and conservative management in postoperative cases [20]. Our case was characterized by marked gaseous distension of the portal venous system in the absence of radiographic signs of bowel necrosis and ischemia. Our patient was successfully managed with careful monitoring and conservative medical therapy. This case highlights the fact that the level of gaseous distension observed radiographically in cases of PVG does not necessarily correlate with the acuity of the

situation and the need for surgical intervention.

Portal venous gas in patients undergoing hemodialysis has been reported sporadically in the medical literature, both in patients on temporary as well as chronic hemodialysis [12,19]. The mechanism of PVG during hemodialysis has not been completely established, but it has been suggested that the prolonged hypotension that occurs during hemodialysis may contribute to marginal injury to intestinal mucosa allowing for the passage of gas present within the lumen to enter the porto-mesenteric circulation [12]. Hemodialysis patients are at increased risk of non-occlusive mesenteric ischemia (NOMI), which occurs at a rate of 0.3-1.9% per patient per year in this population compared to 0.2% per patient per year in the general population [21,22]. NOMI leads to subsequent mucosal damage, which can disrupt the physiologic barrier that normally prevents gut flora from entering the portal venous circulation. In managing patients on hemodialysis, reducing ultra filtration time, increasing low molecular weight heparin dose, and using vasoactive drugs has decreased NOMI [22]. Continuous intravenous prostaglandin E₁ has been shown to improve survival in patients with suspected NOMI [23].

Our patient also had significant constipation on admission with fecalization of the small bowel (Figure 2A). Hemodialysis patients are known to exhibit bowel dysfunction, particularly adynamic ileus leading to colonic pseudo-obstruction [24]. Significant ileus and subsequent distension is a risk factor for intestinal perforation, a mechanism that has been known to cause PVG [10]. The shear distention of the bowel in ileus

may disrupt the mucosal barrier leading to PVG without frank perforation. This case highlights the importance of remaining vigilant of hemodialysis patients' increased risk of bowel dysfunction. Patients on hemodialysis can develop mucosal barrier disruption in the absence of frank perforation, pseudo-obstruction in the setting of ileus, and bowel perforation.

Portal venous gas is often, but not always, a sign of impending decompensation in critically ill patients. This dramatic radiographic finding can occur in patients who do not have bowel perforation or peritonitis. In this case, it may resolve without mechanical intervention. Its occurrence in patients undergoing hemodialysis is most likely multifactorial and may begin with a low-flow state leading to ischemic injury. Prevention with constipation prophylaxis, regulation of blood pressure during hemodialysis, and correcting electrolyte abnormalities may prevent its occurrence.

References

1. Wolfe JN, Evans WA (1955) Gas in the portal veins of the liver in infants. *Am J Roentgenol Radium Ther Nucl Med* 74(3): 486-489.
2. Susman N, Senturia HR (1960) Gas embolization of the portal venous system. *Am J Roentgenol Radium Ther Nucl Med* 83: 847-850.
3. Liebman PR, Patten MT, Manny J, Benfield JR, Hechtman HB (1978) Hepatic portal venous gas in adults: etiology, pathophysiology and clinical significance. *Ann Surg* 187(3): 281-287.
4. Kinoshita H, Shinozaki M, Tanimura H, Umemoto Y, Sakaguchi S, et al. (2001) Clinical features and management of hepatic portal venous gas: four case reports and cumulative review of the literature. *Arch Surg* 136(12): 1410-1414.
5. Faberman RS, Mayo-Smith WW (1997) Outcome of 17 patients with portal venous gas detected by CT. *AJR Am J Roentgenol* 169(6): 1535-1538.
6. Sebastia C, Quiroga S, Espin E, Boye R, Alvarez-Castells A, et al. (2000) Portomesenteric vein gas: pathologic mechanisms, CT findings, and prognosis. *Radiographics* 20(5): 1213-1224.
7. Sisk PB (1961) Gas in the portal venous system. *Radiology* 77(1): 103-106.
8. Birnberg FA, Gore RM, Shragg B, Margulis AR (1983) Hepatic portal venous gas: a benign finding in a patient with ulcerative colitis. *J Clin Gastroenterol* 5(1): 89-91.
9. Katz BH, Schwartz SS, Vender RJ (1986) Portal venous gas following a barium enema in a patient with Crohn's colitis: A benign finding. *Dis Colon Rectum* 29(1): 49-51.
10. Wiesner W, Mortelet KJ, Glickman JN, Ji H, Ros PR (2002) Portal-venous gas unrelated to mesenteric ischemia. *Eur Radiol* 12(6): 1432-1437.
11. Mallens WM, Schepers-Bok R, Nicolai JJ, Jacobs FA, Heyerman HG (1995) Portal and systemic venous gas in a patient with cystic fibrosis: CT findings. *AJR Am J Roentgenol* 165(2): 338-339.
12. Morimoto Y, Yamakawa T, Tanaka Y, Hiranaka T, Kim M (2001) Recurrent hepatic portal venous gas in a patient with hemodialysis-dependent chronic renal failure. *J Hepatobiliary Pancreat Surg* 8(3): 274-278.
13. Quirke TE (1995) Hepatic portal venous gas associated with ileus. *Am Surg* 61(12): 1084-1086.
14. Herman JB, Levine MS, Long WB (1995) Portal venous gas as a complication of ERCP and endoscopic sphincterotomy. *Am J Gastroenterol* 90(5): 828-829.
15. Nguyen HN, Purucker E, Riehl J, Matern S (1998) Hepatic portal venous gas following emergency endoscopic sclerotherapy of gastric varices. *Hepatogastroenterology* 45(23): 1767-1769.
16. Bull MJ, Kaye B (1985) Portal vein gas following double-contrast barium enema. *Br J Radiol* 58(695): 1129-1130.
17. Oei T, Van Sonnenberg E, Shankar S, Morrison PR, Tuncali K, et al. (2005) Radiofrequency ablation of liver tumors: a new cause of benign portal venous gas. *Radiology* 237(2): 709-717.
18. Schmidt AG (1967) Portal vein gas due to administration of fluids via the umbilical vein. *Radiology* 88(2): 293-294.
19. Hiroyasu I, Tokitoku D, Atsichi Y, Kosaihiro T, Nagamine M, et al. (2008) Flaming portal vein as a new color Doppler sign of portal gas: report of two cases. *J Med Ultrasonics* 35(3): 119-123.
20. Nelson AL, Millington TM, Sahani D, Chung RT, Bauer C, et al. (2015) Hepatic Portal Venous Gas, the ABCs of management. *Arch Surg* 144(6): 575-581.
21. Zeier M, Hupp T, Wiesel M, Rambauser M, Ritz E (1993) Nonocclusive intestinal ischemia as a complication of hemodialysis treatment. *Dtsch Med Wochenschr* 118(27-28): 1020-1024.
22. Qian Y, Chen X, Shi H, Xie J, Chen N (2015) Refractory Abdominal Pain in a Hemodialysis Patient. *Case Rep Nephrol Dial* 5(2): 145-151.
23. Mitsuyoshi A, Obama K, Shinkura N, Ito T, Zaima M (2007) Survival in nonocclusive mesenteric ischemia: early diagnosis by multidetector row computed tomography and early treatment with continuous intravenous high-dose prostaglandin E(1). *Ann Surg* 246(2): 229-235.
24. Adams PL, Edwin A, Rostand SG, Han SY (1982) Lower Gastrointestinal Tract Dysfunction in Patients Receiving Long-term Hemodialysis. *Arch Intern Med* 142(2): 303-306.