

Hepatic Artery Thrombosis after Orthotopic Liver Transplantation

Lucas Souto Nacif*, Liliana Ducatti, Wellington Andraus and Luiz Carneiro D'Albuquerque

Department of Gastroenterology, University of São Paulo School of Medicine, Brazil

Submission: December 07, 2015; **Published:** December 23, 2015

***Corresponding author:** Lucas Souto Nacif, Liver and Gastrointestinal Transplant Division, Department of Gastroenterology, University of São Paulo School of Medicine, 05403-900, São Paulo, Brazil, Tel: +55-11-26613323; Fax: +55-11-26619008; Email: lucasnacif@usp.br

Abstract

Introduction: Hepatic artery thrombosis (HAT) is a feared complication in the postoperative period of liver transplantation (LT). It is one of the most serious vascular complications in the postoperative period and associated with a significant increasing in morbidity, graft loss and mortality.

Methods: Non-Systematic literature review through Medline-PubMed database with headings related to hepatic artery thrombosis and liver transplantation in articles published until November 2012 was done.

Discussion: HAT incidence is 2.5 to 6.8% of adult recipients of liver transplantation. Risk factors for HAT surgical technique are related to more frequent and significant, and are mainly associated with early HAT. HAT may present variable clinical manifestations and lead to choose the best management and approach therapy to this specific complication. Minimizing risk factors, establish protocols for early diagnosis and proper surgical technique must be measured standard of excellence centers that wish to avoid this dreaded complication.

Conclusion: The real goal to decrease the incidence of HAT with their high rates of mortality, morbidity and graft loss; the liver transplant team needs earlier diagnosis and best surgical technique to avoid this complication.

Keywords: Hepatic artery thrombosis; Liver transplantation

Abbreviations: HAT: Hepatic Artery Thrombosis; LT: Liver Transplantation; CT: Computed Tomography

Introduction

Hepatic artery thrombosis (HAT) is a feared complication in the postoperative period of liver transplantation. It is certainly the most common arterial complication in liver transplantation. Initially had a high incidence, especially in the pediatric population, but with the development and improvement of surgical technique and perioperative care was a significant reduction of this complication. It is one of the most serious vascular complications in the postoperative period of liver transplantation (LT) and is associated with a significant increase in morbidity, graft loss and mortality [1].

HAT first description by *Starzl* has been recognized as an important cause of graft loss and mortality. Currently occurs in 2.5 to 6.8% of adult recipients of liver transplantation, with a higher incidence in children and ABO incompatible

liver transplantation [1]. Overall, the HAT is divided into two categories: early, occurring within one month after transplantation, and late, occurring after this period.

Etiology

The actual cause of HAT is often debatable and most often unknown. Are several known risk factors associated with increased incidence of HAT, both factors related to surgery and not. Risk factors for HAT surgical technique are related to more frequent and significant, and are mainly associated with early HAT. We can cite as unrelated to the surgical technique the risk factors that alter the vascular endothelium or hemodynamic flow inside the vessel, such as rejection, prolonged cold ischemia time, ABO incompatibility, donor age over 60 years dead, infections cytomegalovirus, among others [2], usually responsible for HAT later.

Risk Factors

There are many risk factors associated with HAT that are related to the surgical procedure, and in particular the most important of the arterial anastomosis. Some measures can be taken with the aim of reducing the occurrence of this serious complication. The anatomy of the donor graft vascularization and vascular anatomy of the recipient should be supported wherever possible to the diameter and length, as the artery diameter less than 3 mm is associated with a higher incidence of HAT [3]. The variation of the hepatic artery is a known and confirmed risk factor for development of HAT [4] therefore should be carried out an arterial reconstruction proper recipient with anatomical variation.

The anastomosis of the hepatic artery with microsurgery should be recommended whenever possible, since the center has trained staff and proper microscope to perform the same, since their use contributes significantly to reducing the incidence of HAT. The suturing using loupe magnification can yield good results [5]. Another relevant aspect in the incidence of HAT is the technique used for arterial anastomosis: continuous or interrupted suture. Literature data show that the anastomosis is not continuous rather than continuing into the hepatic artery anastomosis, offering therefore a lower risk for HAT [6]. A review of vascular complications in the postoperative liver transplant performed in 2010 showed that more than 20% of HAT is probably associated with the surgical technique in the arterial anastomosis, as the difference in caliber of the arteries, poor quality of the vessels and the anatomical variations that require arterial reconstructions [7].

There are several risk factors for HAT that is unrelated to the surgical procedure, especially hemodynamic changes during the perioperative condition highly associated with a higher incidence of HAT [8]. Another factor associated with an increase in the incidence of HAT is the rejection, because it causes vascular endothelial cell injury, predisposing to thrombosis. The adequacy of immune suppression to prevent rejection is usually enough to avoid HAT [9]. Furthermore, a systematic literature review in 2009 on early hepatic artery thrombosis, have been cited as risk factors: age of the cadaver donors over 60 years, ABO incompatibility, warm ischemia time greater than 45 minutes, prolonged cold ischemia time greater than seven hours, surgical time over seven hours, transfusion of packed red blood cells and more than six units of fresh frozen plasma units above fifteen, cytomegalovirus infection and low weight of the receiver [10].

Clinical Manifestations

The HAT may present variable clinical manifestations, usually one of four ways described below [11]:

Fulminant hepatic necrosis and sepsis

Includes patients who evolve quickly to a decompensation

with severe sepsis, fever, altered level of consciousness, hypotension, and coagulopathy. This presentation is most often associated with cases of early HAT. Laboratory tests show high levels of liver enzymes, leukocytosis, and coagulopathy. The cultures are usually positive for various bacteria and imaging typically demonstrates necrosis of the organ.

Biliary complications

These patients presented with cholangitis, biliary strictures and bile leaks. Most often, this picture comes months after transplantation, when collateral circulation is already installed in the graft. Often these neovascularization are sufficient to avoid a case of fulminant hepatic necrosis and sepsis, but not to prevent ischemia of the biliary tract, since the only biliary vascularization of the graft occurs via the hepatic artery. Most of these patients will go to re-transplant, but this can be postponed and held in criteria elective treatments involving the use of biliary prostheses and appropriate antibiotic therapy.

Asymptomatic

The clinical presentation can vary from a mild elevation of transaminases and bilirubin to a fulminant necrosis. This variety is due partly to the moment of occurrence of the HAT, as previously mentioned. The HAT is characterized earlier for a serious medical event, and late HAT with generally milder clinical picture (Table 1).

Table 1: Clinical features in early and late hepatica artery thrombosis (HAT).

Early HAT	Late HAT
Intimal dissection	Intrahepatic biliary necrosis
Fulminant necrosis	septic shock
Cholangitis	Presence of air in the biliary tract
Biliary fistula	Systemic aspergillosis
Sepsis	Intrahepatic biloma
Multiple organ failure	Gastric perforation

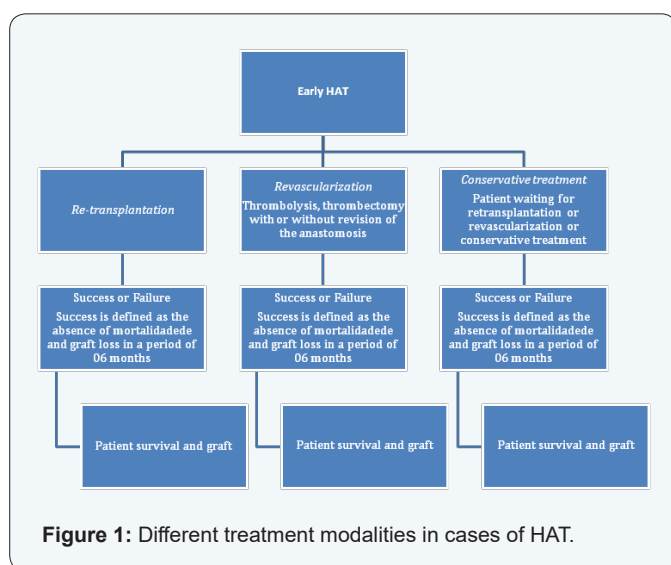
Management

The great challenge for vascular complications in the postoperative period of liver transplantation, such as HAT, is early diagnosis, allowing prompt treatment to try to prevent graft loss. A Doppler ultrasound is the method of choice for early diagnosis because it is able to detect the absence of flow in the hepatic artery. Doppler technique is established for the initial surveillance of vascular integrity after liver transplantation [12]. The median time from diagnosis of HAT is 6.9 days. The screening is routinely performed with an ultrasound, but in cases where there is doubt or suspicion, the patient must undergo a more

detailed study such as Computed tomography (CT) angiography, magnetic resonance angiography or angiography interventional radiology, which are the methods used to confirmation [13]. Most centers take into account a pooled analysis of clinical, laboratory and radiological cases to completion.

It is a serious complication in the postoperative period of liver transplantation with a graft loss rate of approximately 53% and 33% mortality in the immediate postoperative and overall mortality exceeding 50%. Approximately 30% of patients undergoing a re-transplant survival did not reach a long [14].

In general, there are three different treatment modalities in cases of HAT: revascularization, re-transplantation and conservative treatment. The choice of one type of treatment depends on at what time the diagnosis was made (Figure 1).



The re-transplantation is the treatment of choice in most cases, showing better results, but much depends on the conditions under the patient. Attempting to emergency revascularization should be the first step in treatment, especially in cases of early diagnosis. Is successful in early cases of HAT in approximately 55% of the time, at which there is no significant damage to the graft, greatly minimizing the loss of grafts and the need to re-transplant [15].

Thrombolysis can be effective or can show the real cause of HAT, such as anatomical variations, which can eventually be corrected by interventional procedure, such as prosthesis, balloon angioplasty or surgical revascularization. Endovascular treatment should be individualized and depends on the experience of the transplant center. Recalling that is not effective in cases where the patient already has a severe dysfunction of the graft with related symptoms. In these patients should be given the re-transplant [16].

In cases of late HAT, the treatment of thrombosis in itself has no effect, since there is already an installed biliary injury

in these cases the re-transplantation is the treatment of choice [17]. It is of fundamental importance to reduce the incidence of HAT, especially the early HAT due to their high rates of mortality and morbidity, especially the graft loss. Minimizing risk factors, establish protocols for early diagnosis and proper surgical technique must be measured standard of excellence centers that wish to avoid this dreaded complication.

Conclusion

In conclusion, to reduce the incidence of HAT with their high rates of mortality, morbidity and loss of the graft, the liver transplant team needs the early diagnosis and best surgical technique to avoid this complication.

References

1. Stange BJ, Glanemann M, Nuessler NC, Settmacher U, Steinmuller T, et al. (2003) Hepatic artery thrombosis after adult liver transplantation. *Liver Transpl* 9(6): 612-620.
2. Zheng SS, Yu ZY, Liang TB, Wang WL, Shen Y, et al. (2004) Prevention and treatment of hepatic artery thrombosis after liver transplantation. *Hepatobiliary Pancreat Dis Int* 3(1): 21-25.
3. Mazzaferro V, Esquivel CO, Makowka L, Belle S, Kahn D, et al. (1989) Hepatic artery thrombosis after pediatric liver transplantation--a medical or surgical event? *Transplantation* 47(6): 971-977.
4. Drazan K, Shaked A, Olthoff KM, Imagawa D, Jurim O, et al. (1996) Etiology and management of symptomatic adult hepatic artery thrombosis after orthotopic liver transplantation (OLT). *Am Surg* 62(3): 237-240.
5. Tzeng YS, Hsieh CB, Chen SG (2011) Continuous versus interrupted suture for hepatic artery reconstruction using a loupe in living-donor liver transplantation. *Ann Transplant* 16(4): 12-15.
6. Proposito D, Loinaz Seguro C, Garcia Garcia I, Jimenez C, Gonzales Pinto I, et al. (2001) Role of anatomic variations and methods of hepatic artery reconstruction in the incidence of thrombosis following liver transplantation. *Ann Ital Chir* 72(3): 303-314.
7. Pareja E, Cortes M, Navarro R, Sanjuan F, Lopez R, et al. (2010) Vascular complications after orthotopic liver transplantation: hepatic artery thrombosis. *Transplant Proc* 42(8): 2970-2972.
8. Bekker J, Ploem S, de Jong KP (2009) Early hepatic artery thrombosis after liver transplantation: a systematic review of the incidence, outcome and risk factors. *Am J Transplant* 9(4): 746-757.
9. Silva MA, Jambulingam PS, Gunson BK, Mayer D, Buckels JA, et al. (2006) Hepatic artery thrombosis following orthotopic liver transplantation: a 10-year experience from a single centre in the United Kingdom. *Liver Transpl* 12(1): 146-151.
10. Warner P, Fusai G, Glantzounis GK, Sabin CA, Rolando N, et al. (2011) Risk factors associated with early hepatic artery thrombosis after orthotopic liver transplantation - univariable and multivariable analysis. *Transpl Int* 24(4): 401-408.
11. Pastacaldi S, Teixeira R, Montalto P, Rolles K, Burroughs AK (2001) Hepatic artery thrombosis after orthotopic liver transplantation: a review of nonsurgical causes. *Liver Transpl* 7(2): 75-81.
12. Vaidya S, Dighe M, Kolokythas O, Dubinsky T (2007) Liver transplantation: vascular complications. *Ultrasound Q* 23(4): 239-253.

13. Maceneaney PM, Malone DE, Skehan SJ, Curry MP, Miller JC, et al. (2000) The role of hepatic arterial Doppler ultrasound after liver transplantation: an 'audit cycle' evaluation. *Clin Radiol* 55(7): 517-524.
14. Stewart ZA, Locke JE, Segev DL, Dagher NN, Singer AL, et al. (2009) Increased risk of graft loss from hepatic artery thrombosis after liver transplantation with older donors. *Liver Transpl* 15(12): 1688-1695.
15. Scarinci A, Sainz-Barriga M, Berrevoet F, van den Bossche B, Colle I, et al. (2010) Early arterial revascularization after hepatic artery thrombosis may avoid graft loss and improve outcomes in adult liver transplantation. *Transplant Proc* 42(10): 4403-4408.
16. Singhal A, Stokes K, Sebastian A, Wright HI, Kohli V (2010) Endovascular treatment of hepatic artery thrombosis following liver transplantation. *Transpl Int* 23(3): 245-256.
17. Lin CC, Chuang FR, Wang CC, Chen YS, Chen CL, et al. (2004) Early postoperative complications in recipients of living donor liver transplantation. *Transplant Proc* 36(8): 2338-2341.