

Serum Serotonin as a Novel Marker for Hepatocellular Carcinoma

Elsayed Ibrahim Elshayeb^{1*}, Mohamed Abdel Raouf Korani¹, Nada Farag Elmaidany², Mohamed Ahmed Helwa³ and Ehab Ahmed Abd-Elatty¹

¹Internal Medicine Department, Menoufia University, Egypt

²Department of Clinical Pharmacology, MSA October University, Egypt

³Clinical Pathology Department, Menoufia University, Egypt

Submission: May 04, 2016; **Published:** May 19, 2016

***Corresponding author:** Elsayed Ibrahim Elshayeb, Internal Medicine Department, Faculty of Medicine, Menoufiya University, 477 Elhorria Street, Bolkiy, Egypt, Tel: 0021002502062; Email: elsayedib@yahoo.com

Abstract

Aim of the Work: To investigate the role of serum serotonin as a novel marker for diagnosis of Hepatocellular carcinoma In comparison with serum alpha fetoprotein.

Introduction: Hepatocellular carcinoma is the most common liver cancer and is a disease with poor prognosis. In addition to its function as a neurotransmitter and vascular active molecule, Serotonin is also a mitogen for hepatocytes and promotes liver regeneration and may be involved in tumorigenesis of HCC.

Methods: The study conducted on 136 patients and 20 healthy subjects as control group. Patients classified into two groups, 68 Cirrhotic with HCC as group I and 68 only cirrhotic without HCC as group II. Patients and controls underwent through history taking, full clinical examination with Child pugh score laboratory. Investigations including Complete blood count, Liver function tests, Creatinine, serum AFP and Serotonin levels in addition to abdominal ultrasound and Triphasic CT abdomen.

Results: Cirrhotic Patients presented with HCC showed significantly higher levels of serotonin, alpha fetoprotein, albumin and white blood cell count compared to pure cirrhotic group without HCC, however, HCC patients showed lower levels of AST, ALT, bilirubin and platelet count compared to cirrhotic patients. HCC patients were more in elder, associated with male gender and showed shorter prothrombin. A significant positive correlation between serum AFP and serotonin. $r=0.594$, $P<0.001$ AFP at 0.5 ng /ml is a cutoff with sensitivity 100%, specificity 70%, PPV 91.9% and Accuracy 97.6% respectively for diagnosis of HCC while Sr. Serotonin >510ng/ml is a cutoff with 89.71% sensitivity, 85% specificity, 95.3 % PPV, 70.8 % NPV and 96.6 % accuracy respectively for diagnosis of HCC.

Conclusion: Serotonin could be a novel maker for diagnosis of HCC and may be used together with serum AFP for screening of HCC in cirrhotic patients.

Keywords: Cirrhosis; HCC; Serotonin; AFP

Abbreviations: NASH: Non-Alcoholic Steatohepatitis; ALD: Alcoholic Liver Disease; 5-HT: 5-hydroxytryptamine; GI: Gastrointestinal; CNS: Central Nervous System; ANS: Autonomic Nervous System; SERT: Serotonin Transporter; MAO: Monoamine Oxidase; 5-HIAA: 5-Hydroxyindoleacetaldehyde; HCC: Hepatocellular Carcinoma; HGF: Hepatocyte Growth Factor; TGF- α : Transforming Growth Factor α

Introduction

Cirrhosis is a consequence of chronic liver disease characterized by replacement of liver tissue by fibrosis, scar tissue and regenerative nodules leading to loss of liver function. Cirrhosis is most commonly caused by hepatitis B and C, alcoholism, and fatty liver disease, but has many other possible causes [1]. In developing countries viral hepatitis is the leading cause of cirrhosis and in the developed countries alcoholic liver

disease (ALD), HCV and non-alcoholic steatohepatitis (NASH) are the most significant causes of cirrhosis [2]. Some studies have demonstrated that patients who present with cirrhosis related complications (for example, hepatic encephalopathy, esophageal varices, bleeding and HCC) have a decreased survival rate compared with those without complications [3].

Liver biopsy is the only definite method for confirming a diagnosis of cirrhosis. It also helps to determine its cause,

treatment possibilities, the extent of damage, and the long-term outlook. For example, hepatitis C patients who show no significant liver scarring when biopsied may have a low risk for cirrhosis. The histopathological landmarks of cirrhosis are nodularity (regenerating nodules), fibrosis (deposition of connective tissue creates pseudolobules), abnormal hepatic architecture, and hepatocellular abnormalities (pleomorphism, dysplasia, and regenerative hyperplasia) [4]. Because Liver Biopsy is an uncomfortable and sometimes risky procedure, it is unsuitable to incorporate it into the routine follow-up examinations of chronic liver disease patients. There is therefore a demand for serum markers that can routinely assess progression of liver fibrosis and reliably detect the stage of liver cirrhosis. Models such as Fibro test, which is based on a range of clinical chemistry analytes, have recently been intensively studied for these purposes [5].

Serotonin is known as 5-hydroxytryptamine (5-HT), a biogenic amine that function as a ligand for a large family of 5-HT receptors. [6] The majority of serotonin in the body (90%) is synthesized by enterochromaffin cells of the gastrointestinal (GI) tract, where it regulates intestinal motility [7]. It plays a major role in neurotransmission within the central nervous system (CNS) and the autonomic nervous system (ANS), In the CNS serotonin is known to control mood, behavior, learning, sleep and anxiety. Peripherally, serotonin is able to mediate vascular contraction and relaxation, cell proliferation, apoptosis and platelet aggregation [8]. Serotonin is actively taken up by cells expressing the Na⁺/Cl⁻ dependent serotonin transporter (SERT) where it is stored in intracellular vesicles and released in response to various stimuli. Once bound to target receptors or taken up by the SERT, internalised serotonin can be metabolised by monoamine oxidase (MAO) leading to the generation of 5-hydroxyindoleacetaldehyde (5-HIAA) which is excreted in urine [8]. Liver cirrhosis is one of various pathological conditions in which serotonin homeostasis can change. In cirrhotic patients, secondary changes in the GI tract occur. In the altered intestinal wall, disturbances in serotonin synthesis and metabolism are observed. Serotonin leakage to systemic circulation cannot be excluded. It could be manifested by anxiety, sleep disorders, and other emotional disturbances. Then, the liver should play the role of a filter, where serotonin is catabolized. This mechanism fails in the case of liver diseases [9].

The chronic hepatic insufficiency gives rise to serotonin system changes, contributing to the development of hepatic encephalopathy, portal hypertension, and hyperdynamic circulation. In patients with liver cirrhosis, low whole-blood serotonin levels depend probably on reduced uptake, retention of serotonin by platelets, and low platelet number. Also, concentration of circulating serotonin in liver cirrhosis can be influenced by other factors, such as altered serotonin co-oxidase and impaired metabolism of tryptophan, as a precursor of

serotonin [10]. Patients with cirrhosis are known to have platelet storage pool defects, significantly lower intraplatelet serotonin concentrations when compared to healthy individuals. It is therefore tempting to propose that the haemorrhagic tendency of cirrhotic patients [11]. Each year, hepatocellular carcinoma (HCC) (SEER 2010) is diagnosed in more than half a million people worldwide, including approximately 20,000 new cases in the United States. Liver cancer is the fifth most common cancer in men and the seventh in women. Most of the HCC cases (85%) are present in developing countries. [12] Incidence of HCC in Egypt is currently increasing, which may be the result of a shift in the relative importance of HBV and HCV as primary risk factors in addition to exposure to aflatoxin as an additional risk factor [13]. HCC is the second most frequent cause of cancer incidence and mortality among men in Egypt [14]. Egypt has the highest prevalence of HCV in the world, with estimates ranging from 6 to 28% and a reported average of ~ 13.8%, also investigations in Egypt have also shown the increasing importance of HCV infection in the etiology of HCC, account for 40-50% of cases [15].

Hence platelets are not expected to function properly in diseased liver. Platelets harbour important growth factors for liver regeneration, e.g. Hepatocyte growth factor (HGF). Platelets contain transforming growth factor α (TGF- α), which is required for termination of liver regeneration. Thus, it is plausible that platelets may participate in orchestrating liver regeneration through stimulation and inhibition of growth-related signals. The ability of serotonin to modulate all of these factors renders it crucial in times of hepatic injury and repair [16]. Platelet derived serotonin has been shown to be beneficial in terms of stimulating hepatocyte proliferation following hepatic ischaemia in mice [17]. In addition over proliferation of hepatocytes can lead to HCC and this would raise the possibility that serotonin may play a role in HCC pathogenesis [18]. Serotonin is emerging as a mediator of different pathological conditions. It contributes to liver fibrosis, mediates oxidative stress in nonalcoholic steatotic hepatitis, and aggravates viral hepatitis promoting the progression of steatohepatitis by oxidative stress [18]. It promotes tumor growth in a mouse model of subcutaneous colon cancer allografts. 5HT deficiency led to decreased vascularity and increased necrosis reflecting cell death of the tumor.

Subjects and Methods

This study conducted on 136 patients and 20 healthy subjects as control group, Subjects selected from the outpatient of our Menoufia University Hospital and after oral and written consent from all, Patients and control subjects classified into 3 groups

G1: 68 Cirrhotic patients

G2: 68 Cirrhotic patients with HCC

G3: 20 healthy control subjects

Exclusion criteria

- Patients with active gastrointestinal bleeding.
- Patients with other neoplasms
- Patients with any active infection including spontaneous bacterial peritonitis
- Patients with evident neurotic or psychiatric disorders other than Hepatic encephalopathy
- Patients who are taking benzodiazepines, narcotics, or other agents that can alter gastrointestinal motility such as prokinetic agents like metoclopramide, erythromycin, cisapride, opioids, adsorbents like bismuth subsalicylate and anti-emetic drugs like promethazine.
- Patients with cardiopulmonary, renal and endocrinal diseases.

All patients were subjected to the following:

I-Thorough history taking with special emphasis on the following:

- Age and Sex.
- Manifestations of liver cirrhosis history of bleeding, encephalopathy and previous medication

II-Thorough physical examination with special emphasis on:

- Signs of liver cell failure (e.g. jaundice, pallor, ascites, hepatomegaly, splenomegaly, and lower limb edema).

Signs of hepatic encephalopathy: all patients will be examined carefully for the presence of asterixis

2-Laboratory investigations including:

A- Complete blood count.

B-Kidney function tests (Urea, Creatinine)

C-Liver function tests (AST, ALT, bilirubin (total & direct), albumin, prothrombin time)

D – Viral marker HCV-antibodies & HBs-antigen

3-Special investigations:

a-Measurement of serotonin blood level (Using immunoenzymatic assays (ELIZA)).

b- Serum alpha fetoprotein

c-Abdominal ultra sound

d-Triphasic CT liver to identify site and size of HCC

Results

The present study was conducted 136 patient and 20 healthy

subjects as control group classified as follows:

G1: 68 Cirrhotic patients , 38 males and 30 females with age 53.51 ± 7.21 , classified according to child pugh classification into child A 11patients , child B 10 patients and child C 47 patients.

G 2: 68 patients Cirrhotic with HCC 55 males and 13 females with age 57 ± 8

G3: 20 health control subjects 14 males and 6 females with age 54 ± 10

Etiology of liver cirrhosis in cirrhotic group was HCV in 60 patients (88.24%), HBV in 8 patients (11.76%), 21 patients (30.8%) with history of melena, 10 patients (14.71%) had history of hematemesis and 2 patients (2.94%) had bleeding gum, 40 patients had history of encephalopathy, 10 patients (14.71%) had mild ascites, 15 patients (22.06%) had moderate ascites, 33patients (48.53%) had history of tense ascites, 64patients (92.65%) with enlarged spleen, 4 patients (5.88%) have normal size spleen, according to child pugh classification, there were 11 patients class A, 10 patients class B and 47 patients class C. Etiology of liver cirrhosis in HCC group HCV 78% (n=53) with schistosomiasis in 18% (n=12), hepatitis B virus in 4 %(n=3), 55 males and 13 females in HCC group, 43% child A (n=29), 38% (n=26) are child class B and 19 % (n=13) are child class C. In HCC group 76% (n=52) have focal lesion in R lobe, 22.5% (n=15) have focal lesion in left lobe and 1.5% (n=1) have focal lesions in both R and L lobes and 5 patients have distant metastases in lungs, colon and bone.

Patients presented with HCC showed significantly higher levels of serotonin, alpha fetoprotein, albumin and white blood cell count compared to cirrhotic groups. However, HCC patients showed lower levels of AST, ALT, bilirubin and platelet count compared to cirrhotic patients. However, HCC patients were of older age associated with male gender and showed shorter prothrombin time compared to cirrhotic patients (Table 1). Serum serotonin was significantly higher in HCC patients with metastases than patients without metastases (Table 2) with Mean \pm SD 1134 ± 140.641 compared to that of isolated HCC without metastases 852.524 ± 283.965 . Serotonin level in patients with isolated HCC and patients with metastasis are shown in Table 2. Serotonin level in different etiology of liver cirrhosis is shown in Table 3. Correlation between serotonin and different parameters in HCC patients are shown in Table 4. Comparison between Cirrhotic patients groups (A,B,C) according to Child classification as regard blood serotonin shown in Table 5. Sensitivity, specificity and accuracy for AFP and serotonin HCC group are shown in Table 6. ROC curve for α fetoprotein level in HCC patients is shown in Figure 1. AFP at cutoff 5 ng/ml in the area under ROC curve showing high sensitivity and specificity. ROC curve for serotonin level in HCC group is shown in Figure 2. Sr .Serotonin at cutoff > 510 under ROC curve showed high sensitivity and specificity in HCC group

Table 1: Comparison between HCC and cirrhotic patients as regard age, gender blood serotonin and other lab parameters.

Parameter	HCC	Cirrhosis	Control	P3	P2	P1
Blood serotonin Mean ±SD	973.221±385.091	730±168.405	210±98-810	<0.0001	0.001*	0.004*
Age Mean ±SD	57±8	53.515±7.216	54±10	0.0086*	0.932	0.638
Gender	55	38	14			
Male	13	30	6	0.0029*	0.326	0.319
female						
Hb (gm/dl): Mean ± SD	11.5± 1.7	9.686±1.911	12.6±1.6	<0.0001*	0.077	<0.001*
WBCs (103/cmm): Mean ± SD	33.735± 28.672	7.272±3.749	6.472±2.853	<0.0001*	0.040*	0.417
Platelets (103/cmm): Mean ± SD	109.8± 48.9	121.126±96.535	210.9±50.3	0.389	<0.001*	<0.001*
AST(U/dl): Mean ± SD	24.21± 18.9	27.116±20.461	22.14±11.87	0.3912	0.364	0.529
ALT(U/dl): Mean ± SD	30.9 ± 20.7	31.082±30.934	36.89±13.10	0.9679	0.733	0.47
Serum albumin (g/dl): Mean ± SD	3± 0,8	2.620±0.017	4.2±0.81	0.0001*	0.002*	0.030*
Serum total bilirubin (mg/dl): Mean ± SD	1.705± 1.368	2.748±1.803	0.8±0.49	0.0002*	0.043*	0.004*
Prothrombin time (sec): Mean ± SD	14.625± 1.586	15.885±5.125	12.52±3.61	0.054	0.0018*	0.002*
Alpha-fetoprotein (ng/dl): Mean ± SD	135.457±29.547	22.67±2.18	5.66±1.21	0.0019*	<0.001*	<0.001*

*Statistically significant at P≤0.05

P1 between control and Cirrhotic group

P2 between control and HCC group

P3 between HCC group and Cirrhotic group

Significant difference between HCC group and cirrhotic group regarding Hb, WBCs, sr. serotonin, bilirubin and AFP.

Table 2: A significant increase in sr. serotonin in in HCC patients with metastases than HCC patients without metastases.

Serotonin level							T-Test	
	Patients with isolated HCC			Patients with metastasis			t	P-value
Range	420	-	1350	980	-	1240	-2.184	0.033*
Mean ±SD	852.524	±	283.965	1134	±	140.641		

Table 3: shows that no significant difference in serotonin level in different etiology of liver cirrhosis (P= 0.374).

Etiology of HCC	Serotonin level					ANOVA	
	Range		Mean	±	SD	F	P-value
bilharziasis	550	1350	900	±	381.7	1.056	0.374
HCV	420	1250	882.2	±	271.1		
HB	510	750	590	±	138.6		
HCV & bilharziasis	650	1300	912.5	±	319.8		

Table 4: Shows There was a significant positive correlation between serotonin level and AFP (r=0.594, p<0.001*), total bilirubin (r=0.254, p=0.036*), prothrombin time (r=0.267, p=0.029*), spleen size (r=0.316, p=0.009*), portal vein diameter (r =0.315, p=0.009*), Child-Pugh score(r=0.254, p=0.037*)

	Serotonin leve	
	r	P-value
Alpha-fetoprotein (ng/dl)	0.594	<0.001*
Age (years)	0.084	0.498
T-bilirubin (ml/dl)	0.254	0.036*
Albumin (g/dl)	-0.076	0.535
PT (sec)	0.267	0.029*
AST(U/dl)	0.266	0.714
ALT(U/dl)	0.045	0.236
Urea (mg/dl)	0.055	0.658
Creatinine (mg/dl)	-0.166	0.175
HB (gm/dl)	-0.017	0.888
WBCS (10 ³ /cmm)	0.070	0.573
Platelets (10 ³ /cmm)	0.064	0.602
spleen size	0.316	0.009*
Size of tumour	0.163	0.215
Portal vein diameter (mm)	0.315	0.009*
Child-Pugh score	0.254	0.037*

Table 5: blood serotonin is significantly higher in child A than child C (p= 0.009), but there was no significant difference between child A and B, and child B and C.

Child	Serotonin level					ANOVA		
	Range		Mean	±	SD	F	P-value	
A	575	-	950	764.909	±	130.136	4.735	0.012*
B	460	-	950	623.200	±	180.749		
C	390	-	950	600.468	±	161.185		

Table 6: shows that sensitivity 100%, specificity 70%, PPV 91.9, NPV 100% and accuracy 97.6% for AFP and sensitivity 89.71%, specificity 85%, PPV 95.3, NPV 70.8% and accuracy 96.6% for serotonin.

	Cut off	Sens.	Spec.	PPV	NPV	Accuracy
AFP	0.5	100	70	91.9	100	97.6
Serotonin	>510	89.71	85	95.3	70.8	96.6

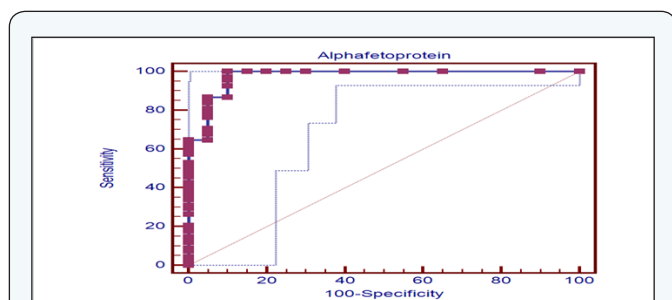


Figure 1: ROC curve for α fetoprotein level in HCC patients. AFP at cutoff 5 ng/ml in the area under ROC curve showing high sensitivity and specificity.

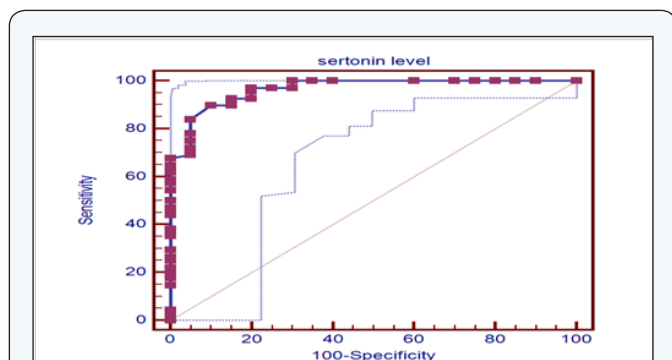


Figure 2: ROC curve for serotonin level in HCC group. Sr. Serotonin at cutoff > 510 under ROC curve showed high sensitivity and specificity in HCC group.

Discussion

Serotonin (5HT) a well known neurotransmitter within the central nervous system, also regulate a wide range of physiological actions in the gastrointestinal tract [19]. 5HT a potent mitogen for many different cell types including hepatocytes [20]. Within the liver 5HT has the ability to regulate hepatic blood flow at both portal vein and sinusoidal levels and it may play a role in hepatic regeneration [8]. Serotonin has been shown to mediate the pathology of many liver diseases, such as steatohepatitis, chronic cholestasis, viral hepatitis and liver cirrhosis [8]. All these conditions are involved in the tumorigenesis of HCC [21]. Although Serotonin promoting liver regeneration, it is involved in many liver diseases and tumors such as steatohepatitis, chronic cholestasis, development of portal hypertension, aggregation of viral hepatitis and progression of hepatic fibrosis and facilitate tumor growth as cholangiocarcinoma and HCC [22].

HCV infection was the main etiology of liver cirrhosis in the majority of our cases, about 60 patients (88.2%) and HBV in 8 patients (11.76 %) of cirrhotic group while 78% and 4% respectively in HCC group. In our study Serotonin level was correlated with degree of portal hypertension, splenic size and portal vein diameter as with statistically significant difference between serotonin level in cirrhotic patients and healthy control subjects and between cirrhotic and HCC groups. Abdu Elmoety

et al. [23] found that ROC curve for serotonin cut off 75ng /ml, 93.33 % sensitivity with 100% PPV and 100 % specificity with 83.3% NPV and 95% accuracy, in the present study sensitivity of serotonin 95.27 % and specificity 88.24%, PPV 97.1% and accuracy 97.6% for liver cirrhosis. Farintai et al. [24] concluded that AFP was not a sensitive marker to detect the presence of HCC. Also, the prognostic value of AFP is limited, but correlated with the overall survival in untreated patients. AFP is less specific and can be elevated in liver cirrhosis and other malignancies, it is recommended that it is no longer be used for diagnosis of HCC [25].

In our study, Sr. serotonin was significantly higher in Child A cirrhotic patients than child C ($p < 0.005$) and also with statistical significant difference between HCC group and cirrhotic patients. We found serum serotonin is also correlated with liver synthetic capacity, child score, sr. bilirubin and prothrombin time. Abdo – Elmoety et al. [23] found in the cirrhotic group that ROC for AFP at cut off 10 ng /ml the area under ROC curve was 0.733, $p = 0.074$ showing 51.11% sensitivity, 100% PPV and 31.25% NPV and 60 % accuracy .Found also serotonin AUROC with cut off 75ng /ml (0939) $p = 0.031$ showed 86.67% sensitivity and 100% specificity with 62.50 % NPV and 89.09% accuracy. And serotonin in the HCC group at cut off 75ng/ml by ROC the diagnostic performance arrived 100%. In the present study sensitivity of serotonin 89.71%and specificity 85%and sensitivity of AFP is 100% and specificity 70%.

Conclusion

Combined use of serotonin and AFP is better in diagnosis of HCC. A significant positive correlation was found between Sr. serotonin and AFP in HCC patients ($r = 0.954$), $p < 0.001$. So higher AFP is associated with higher serotonin and this signify the association between AFP and serotonin and so the importance of sr. Serotonin as marker of HCC and together with the result of ROC curve can be considered as a good marker for diagnosis of HCC.

References

1. Pinzani M, Rosseli M, Zuckemann M (2011) Liver cirrhosis. *Best Pract Res Clin Gastroenterol* 25(2): 281-290.
2. Wynn T (2008) Cellular and molecular mechanisms of fibrosis. *J Pathol* 214(2): 199-210.
3. Huo TI, Wu JC, Lin HC, Lee FY, Hou MC, et al. (2005) Evaluation of the increase in model for end-stage liver disease (Delta MELD) score over time as a prognostic predictor in patients with advanced cirrhosis: risk factor analysis and comparison with initial MELD and Child-Turcotte-Pugh score. *J Hepatol* 42(6): 826-832.
4. Garcia-Tsao G, Sanyal AJ, Grace ND, Carey WD, Practice Guidelines Committee of American Association for Study of Liver Diseases, et al. (2007) Practice Guidelines Committee of American Association for Study of Liver Diseases; Practice Parameters Committee of American College of Gastroenterology. Prevention and management of gastroesophageal varices and variceal hemorrhage in cirrhosis. *Am J Gastroenterol* 102(9): 2086-2102.
5. Halfon P, Munteanu M, Poynard T (2008) Fibro Test-ActiTest as a non-

- invasive marker of liver fibrosis. *Gastroenterol Clin Biol* 32(6 Suppl 1): 22-39.
6. Hoyer D, Clarke DE, Fozard JR, Hartig PR, Martin GR, et al. (1994) International Union of Pharmacology classification of receptors for 5-hydroxytryptamine (Serotonin). *Pharmacol Rev* 46(2): 157-203.
 7. Gershon MD (2013) 5-Hydroxytryptamine (serotonin) in the gastrointestinal tract. *Curr Opin Endocrinol Diabetes Obes* 20(1): 14-21.
 8. Ruddell RG, Oakley F, Hussain Z, Yeung I, Bryan-Lluka LJ, et al. (2006) A role for serotonin (5-HT) in hepatic stellate cell function and liver fibrosis. *Am J Pathol* 169(3): 861-876.
 9. Cools R, Roberts AC, Robbins TW (2008) Serotonergic regulation of emotional and behavioural control processes. *Trends Cogn Sci* 12(1): 31-40.
 10. Culafic DM, Mirkovic DS, Vukcevic MD, Rudic JS (2007) Plasma and platelet serotonin levels in patients with liver cirrhosis. *World J Gastroentero* 13(43): 5750-5753.
 11. Nocito A, Dahm F, Jochum W, Jang JH, Georgiev P, et al. (2008) Serotonin regulates macrophage-mediated angiogenesis in a mouse model of colon cancer allografts. *Cancer Res* 68(13): 5152-5158.
 12. El-Serag H, Rudolph K (2007) Hepatocellular carcinoma: epidemiology and molecular carcinogenesis. *Gastroenterology* 132(7): 2557-2576.
 13. Strickland GT, Elhefni H, Salman T, Waked I, Abdel-Hamid M, et al. (2002) Role of hepatitis C infection in chronic liver disease in Egypt. *Am J Trop Med Hyg* 67(4): 436-442.
 14. Freedman LS, Edwards BK, Ries LAG, Young JL (2006). Cancer incidence in four member countries (Cyprus, Egypt, Israel, and Jordan) of the Middle East cancer consortium (MECC) compared with US SEER. *Natl Cancer I Monogr*. Bethesda MD: NIH Pub, No. 06-5873
 15. El-Zayadi AR, Badran HM, Shawky S, Emara S, El-Bareedy A, et al. (2010) Effect of surveillance for hepatocellular carcinoma on tumor staging and treatment decisions in Egyptian patients. *Hepatol Int* 4(2): 500-506.
 16. Itoh H, Cicala C, Douglas GJ, Page CP (1996) Platelet accumulation induced by bacterial endotoxin in rats. *Thromb Res* 83(6): 405-419.
 17. Amitrano L, Guardascione MA, Brancaccio V, Balzano A (2002) Coagulation disorders in liver disease. *Semin Liver Dis* 22(1): 83-96.
 18. Ruddell RG, Oakley F, Hussain Z, Yeung I, Bryan-Lluka LJ, et al. (2008) A role for serotonin (5-HT) in hepatic stellate cell function and liver fibrosis. *Am J Pathol* 169(3): 861-876.
 19. Ni W, Watts SW (2006) 5-Hydroxytryptamine in the cardiovascular system: Focus on the serotonin transporter (SERT). *Clin Exp Pharmacol Physiol* 33(7): 575-583.
 20. Fanburg BL, Lee SL (1997) A new role for an old molecule: serotonin as a mitogen. *Am J Physiol* 272(5 Pt 1): L795-806.
 21. Schuppan D, Afdhal NH (2008) Liver cirrhosis. *Lancet* 371(9615): 838-851.
 22. Lesurtel M, Soll C, Humar B, Clavien BA (2012) Serotonin: A double-edged sword for the liver?. *Surgeon* 10(2): 107-113.
 23. Hoda Aly Abd El Moety, Dalia Aly Maharem, Salwa Hamdy Gomaa (2013) Serotonin: is it a marker for the diagnosis of hepatocellular carcinoma in cirrhotic patients?. *Alexandria Journal of Medicine* 49(4): 369-378.
 24. Farinat F, Marino D, De Giorgio M, Baldan A, Cantarini M, et al. (2006) Diagnostic and prognostic role of alpha-fetoprotein in hepatocellular carcinoma: both or neither?. *Am J Gastroenterol* 101(3): 524-532.
 25. Grizzi F, Franceschini B, Hamrick C, Frezza EE, Cobos E, et al. (2007) Usefulness of cancer-testis antigens as biomarkers for the diagnosis and treatment of hepatocellular carcinoma. *J Transl Med* 5: 3.