



Case Report

Volume 2 Issue 4 – January 2017  
DOI: 10.19080/ARGH.2017.02.555595

Adv Res Gastroentero Hepatol

Copyright © All rights are reserved by Deepankar Kumar Basak

# A Case of Successful Use of Biliary Duct Balloon Dilator in Repairing Postsurgical Esophageal Stricture in an Infant at the Age of 3 Months



Deepankar Kumar Basak<sup>1\*</sup>, Richmond Ronald Gomes<sup>2</sup> and Md Samsul Arfin<sup>3</sup>

<sup>1</sup>Specialist-Gastroenterology, Square Hospitals Ltd., Bangladesh

<sup>2</sup>Assistant Professor, Internal Medicine, Ad-din Sakina Medical College & Hospital, Bangladesh

<sup>3</sup>Consultant, gastroenterology, Square Hospitals Limited, Bangladesh

**Submission:** December 17, 2016; **Published:** January 25, 2017

\*Corresponding author: Deepankar Kumar Basak, MBBS, FCPS (Medicine), Specialist-Gastroenterology, Square Hospital Ltd., Dhaka, Bangladesh, Tel: 01760499475; Email: deepankarbasak@gmail.com

## Abstract

Esophageal atresia is an abnormality, or birth defect of the esophagus that occur early in pregnancy. One or more fistula may be present between the malformed esophagus and trachea. The lack of esophageal patency prevents swallowing. Congenital Esophageal Atresia (EA) needs to be surgically corrected as soon as possible. Some will present with post surgical stricture that needs to be dilated by a balloon dilator. This procedure is difficult in premature born due to infant esophageal size and availability of equipments. We hereby report the first case in a premature infant with post surgical esophageal stricture of esophageal atresia by the use of biliary duct balloon dilator.

**Keywords:** Balloon dilator; Esophagus; Stricture

## Introduction

The most common gastrointestinal atresia is congenital esophageal atresia (EA). Blind proximal esophagus with fistula between distal esophagus and the Tracheoesophageal Fistula (TEF) is the most common type. Treatment is by extra pleural surgical repair of the esophageal atresia and closure of the tracheoesophageal fistula. Development of post-surgical esophageal stricture is a common complication. These anastomotic strictures can cause dysphagia, feeding difficulties, feeding tubes (nasogastric or gastrostomy) dependency. For partial strictures conservative endoscopic management is preferred [1]. A major limiting factor to this approach is the esophageal abnormal anatomy and motility. Endoscopic dilatation can be performed successfully with over guide wire ante grade dilation using Savary- Gilliard bougies<sup>1</sup> or under direct visualization using cre balloon dilatation under fluoroscopic guidance [2]. Sever anastomotic stricture may not be traversed with a standard guide wire, for that a retrograde gastric endoscopy can be considered. This approach has been associated with many complications (infection, bleeding

and formation of fistula) especially in patients who require gastrostomy tube placement for this retrograde approach [3]. The use of biliary type guidewire in dilating strictures that are not traversable endoscopically has been reported [4]. The use of biliary-type guidewire in dilating sever anastomotic esophageal stricture post-surgical TEF repair has not been described in our country. We describe a safe, successful and feasible technique to dilate sever esophageal stricture in a three month- old male infant that was otherwise inaccessible by a standard antegrade endoscopic approaches.

## Case Report

A 3 months baby named Awsaf weighting 2.5 kg was born at 37 weeks of gestation by normal vaginal delivery. Just after delivery, baby was tried for breast feeding but regurgitation of milk occurs through mouth and nose. Then baby was admitted to hospital. By doing USG and barium swallow, it was found that boy had the most common variant of EA and TEF which was 3 mm from the tracheal wall. Prenatal sonogram was failed to show the most common variant of EA with TEF due to lack of good trained

sonologist. After 25 days, surgery was performed to correct TEF (right posterolateral 4<sup>th</sup> intercostals, transpleural thoracotomy with ligation of distal trachea esophageal fistula and end to end esophageal anastomosis was done) [5]. Post operative nasogastric feeding was started from 2<sup>nd</sup> day on wards. After one moth boy again developed regurgitation, after barium swallow it was found to develop stricture at the anastomotic site. Then patient was referred to Gastroenterologist for upper endoscopy and likely balloon dilation of his anastigmatic stricture that was seen on a barium study. The presumption was that the esophagus would have narrowing around the anastomosis area [6].

After doing endoscopy, tight narrowing of the esophagus is noted at 10 cm from the incisor teeth (about 5 cm from the upper esophageal sphincter) (Figure 1). Initially dilatation was tried by Savary Gilliard dilator up to size 5 mm but dilatation was not successful. Ultimately dilatation is done by hurricane balloon dilator under fluoroscopic control. Repeat endoscopy confirms adequate dilatation and allowed the scope to pass easily (Figure 2&3). Lower esophageal sphincter is at 15 cm from the incisor teeth.

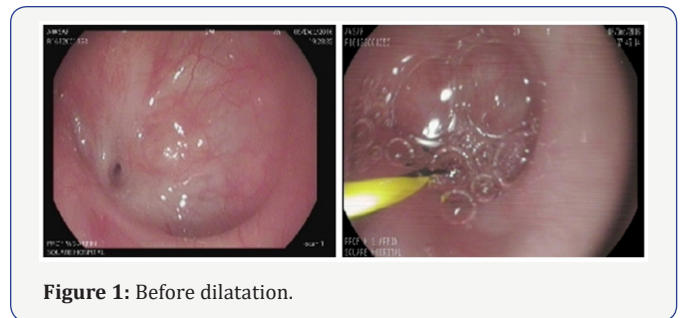


Figure 1: Before dilatation.

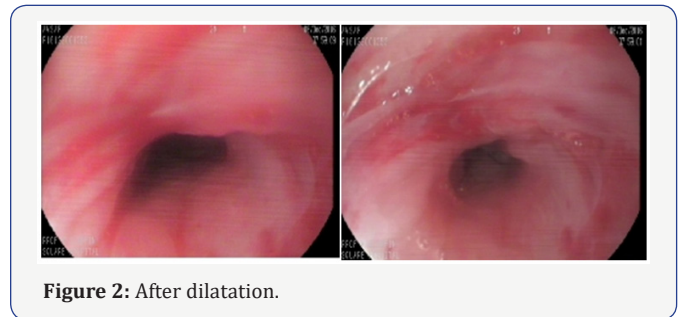


Figure 2: After dilatation.

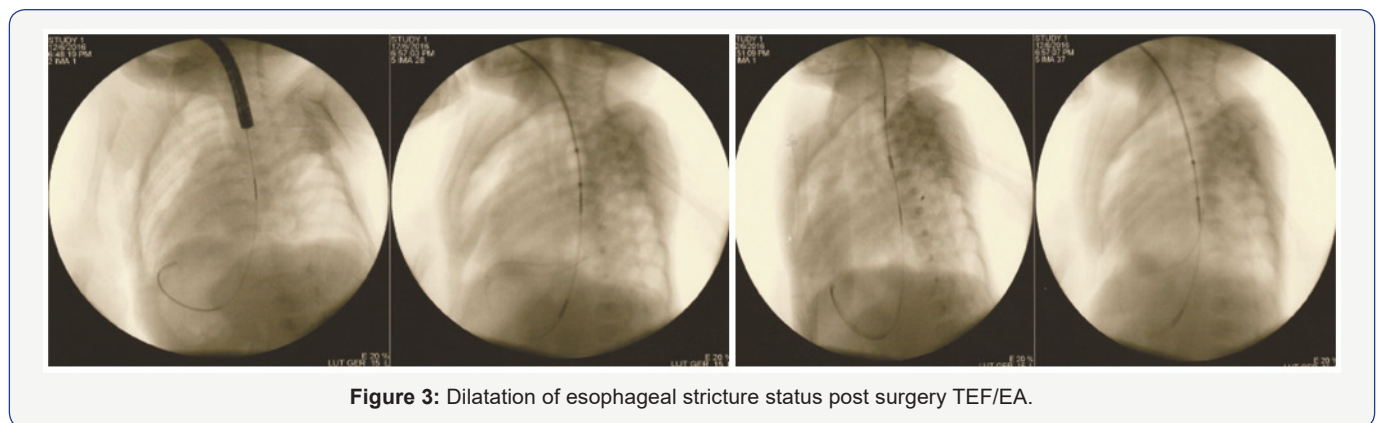


Figure 3: Dilatation of esophageal stricture status post surgery TEF/EA.

**Discussion**

Endoscopic management of postsurgical esophageal strictures is usually sufficient and successful, few cases of sever strictures or complete obstruction may need surgical interventions. In these cases the use of Biliary Balloon dilators can be the solution, before sending them for invasive surgical options like gastric or colonic interposition. Our case with a primary esophageal atresia repair complicated by subsequent anastomotic stenosis that underwent a successful procedure by using Biliary duct balloon dilator to dilate the esophageal lumen. The long-term patency and success of this procedure in this individual patient will need to be further evaluated with follow-up studies as clinically indicated. To our knowledge, there is no other case documented in the literature of an attempted esophageal dilatation using the biliary balloon before in our country). Inserting the wire under direct visualization through the scope confirms in the stomach decreases the risk of wire placement related perforation under fluoroscopy. After confirming the wire placement, biliary balloon dilators can be used in this setting to dilate sever esophageal strictures

successfully. The use of endoscopic biliary accessories in dilating sever esophageal strictures should be considered before sending these patients to invasive retrograde gastroscopy dilation or surgical interventions.

**Conclusion**

The use of biliary baloon dilators is safe and feasible in managing tight non traversable esophageal strictures (< 6 mm). This technique should be considered before sending all patients for more surgical portion.

**References**

1. Gallardo LM, Fragoso Arbelo T, Sagaró González E, Delgado Marrero B, Larramendi Rodes O, et al. (1995) Treatment of esophageal stenosis with Savary-Gilliard balloons in children. *G E N* 49(1): 15-22.
2. Cho YK, Shin JH, Kim BS, Yook JH, Song HY, et al. (2007) Fluoroscopically guided balloon dilation of anastomotic strictures after total gastrectomy: longterm results. *AJR Am J Roentgenol* 188(3): 647-651.
3. Sullivan CA, Jaklitsch MT, Haddad R, Goguen LA, Gagne A, et al. (2004) Endoscopic management of hypopharyngeal stenosis after organ sparing therapy for head and neck cancer. *Laryngoscope* 114(11): 1924-1931.

4. Parasher VK (2005) A novel approach to facilitate dilation of complex nontraversable esophageal strictures by efficient wire exchange using a stent pusher. *Gastrointest Endosc* 51(6): 730-731.
5. Harouchi A, Bellakhdar A (1978) Livaditis procedure used for repair of esophageal atresia type I (author's transl). *Chir Pediatr* 19(4): 279-281.
6. Ahlawat SK, Davidson BJ, Al-Kawas FH (2008) Successful use of biliary accessories in antegrade dilation of complex upper esophageal stricture due to chemoradiation and surgery. *Diseases of the Esophagus* 21(1): 86-89.



This work is licensed under Creative Commons Attribution 4.0 License  
DOI: [10.19080/ARGH.2017.02.555595](https://doi.org/10.19080/ARGH.2017.02.555595)

### Your next submission with Juniper Publishers will reach you the below assets

- Quality Editorial service
- Swift Peer Review
- Reprints availability
- E-prints Service
- Manuscript Podcast for convenient understanding
- Global attainment for your research
- Manuscript accessibility in different formats  
( Pdf, E-pub, Full Text, Audio)
- Unceasing customer service

Track the below URL for one-step submission

<https://juniperpublishers.com/online-submission.php>