



Case Report

Volume 3 Issue 1 – February 2017
DOI: 10.19080/ARGH.2017.03.555604

Adv Res Gastroentero Hepatol

Copyright © All rights are reserved by Kafil Akhtar

Adenomatoid Odontogenic Tumor with Radicular Cyst-A Rare Presentation



Kafil Akhtar*, Shivani Gupta and Afzal Anees

Cytopathology and Histopathology, India

Submission: February 01, 2017; **Published:** February 13, 2017

***Corresponding author:** Kafil Akhtar, Professor, Department of Pathology, Jawaharlal Nehru Medical College, Aligarh Muslim University, Aligarh. U.P, India, Tel: 9568467727; Email: drkafilakhtar@gmail.com

Abstract

Adenomatoid odontogenic tumor is a benign, slow growing lesion. It is a relatively uncommon lesion which mainly affects females in their second decade of life, exhibiting predilection for the anterior region of the maxilla. The lesion is usually associated with the crown of an unerupted tooth, most commonly the maxillary canine. We present a case of adenomatoid odontogenic tumor associated with a dentigerous cyst affecting the left maxillary region in a 18-year-old female, who presented with gingival swelling. Histopathologic examination showed round to plump to spindle-shaped epithelial cells forming aggregates with minimal connective tissue, and cuboidal or low columnar cells forming glandular duct-like structures. The diagnosis of adenomatoid odontogenic tumor should be considered in a case with a corticated radiolucency in the anterior jaw, especially in teens and young adults. The patient has shown no signs of recurrence after eleven months of follow up period.

Keywords: Adenomatoid odontogenic tumor; Odontogenic cyst; Odontogenic tumor

Introduction

Adenomatoid odontogenic tumor (AOT) is a slow-growing, rare oral lesion that arises from the odontogenic epithelium. It accounts for 2.2-13% of all odontogenic tumors [1,2]. It is a benign tumor that involves the anterior region of the maxillary bones, with a female preponderance. Usually occurs in the second decade of life and may be associated with odontogenic cystic lesions.

There are three variants of AOT: follicular, extra follicular and peripheral. The follicular type is a central intra-bony lesion associated with an unerupted tooth, which accounts for about 70% of all cases. The extrafollicular type is also an intra-osseous lesion, but unrelated to an unerupted tooth and represents 25% of all AOTs. The peripheral type is a rare form that arises in the gingival tissue [2,3]. All three variants have the same histological aspect and clinical behavior [4]. The present study reports an uncommon case of adenomatoid odontogenic tumor, associated with a dentigerous cyst.

Case Summary

An 18 year old female presented to the surgical clinics with a tense mass in the oral cortical bone of her maxilla for the last 7

months. Intra-oral physical examination revealed a firm, sessile, grey-brown, 3 x 2 cm swelling in the anterior right maxillary gingiva, with a focal, well-demarcated red-colored area in the region adjacent to the marginal gingiva. Panorama radiographic study revealed a well circumscribed radiolucent lesion with few radiopaque areas around the canine tooth. An intraoral surgical intervention from the alveolar and left central superior incisive gingiva was carried out, with removal of the tumor mass and the unerupted canine.

Histopathology of the mass showed of proliferation of fusiform cells, arranged as large islands, solid sheets and ducts, lined by cuboidal epithelial cells with hyperchromatic nuclei (Figure 1). Foci of eosinophilic amorphous material and calcification was also seen admixed with a cystic lesion coated by a stratified epithelium (Figure 2), showing a continuity with the neoplastic foci, encased with a connective fibrous capsule. A histological diagnosis of adenomatoid odontogenic tumor, associated with a dentigerous cyst was given. After 12 months of follow up, the patient showed no signs of clinical or radiographic evidence of tumor recurrence.

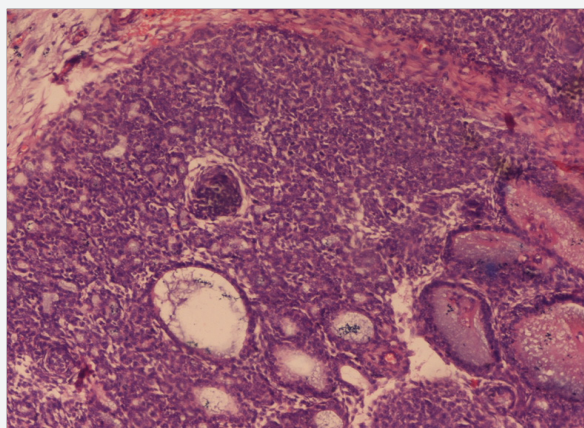


Figure 1: Histopathology of the mass showed of proliferation of fusiform cells, arranged as large islands, solid sheets and ducts, lined by cuboidal epithelial cells with hyperchromatic nuclei. Hematoxylin and Eosin x 40X.

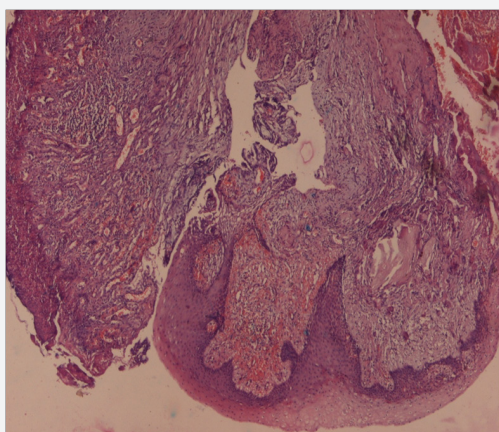


Figure 2: Tissue section showed foci of eosinophilic amorphous material and calcification was also seen admixed with a cystic lesion coated by a stratified epithelium, showing a continuity with the neoplastic foci, encased with a connective fibrous capsule. Hematoxylin and Eosin x 40X.

Discussion

AOT is a benign, slow growing, non-invasive odontogenic lesion. It is rightfully called as ‘Master of Disguise’ and ‘Perfect imitator of dentigerous cyst’ as noted in the present case [1-7]. Majority of AOTs are diagnosed in the second decade of life, with age range of 3 to 28 years and a mean age of 13 years [3,4]. AOT has a female preponderance with a female to male ratio of 2:1.5 AOT has been described as “two thirds Tumor” because two third cases occurs in the maxilla of young females and two third cases are associated with unerupted canine tooth [4]. Our case was seen in anterior maxilla associated with unerupted canine tooth.

All AOT variants have a common origin as they all show an identical histologic characteristics [6]. The pathogenesis of an odontogenic tumor appears to involve persistence of remnants of the dental lamina, especially after odontogenesis of the successional and accessional laminae. These remnants give rise

to epithelial rests that proliferate in response to an unknown stimulus [7].

The radiographic findings of AOT frequently resemble other odontogenic lesions such as dentigerous cysts, calcifying odontogenic cysts, calcifying odontogenic tumors, maxillary cysts, ameloblastomas and odontogenic keratocysts [8,9]. Intraoral periapical radiographs in AOT show focal radiopacities with discrete foci of radiolucency [10,11]. The radiographic findings in our case is typical of follicular variant of adenomatoid odontogenic tumor, presenting as a well-defined radiolucent unilocular lesion, associated to the crown of the unerupted tooth.

Few cases of adenomatoid odontogenic tumors associated with dentigerous cysts are reported in the literature. Santos et al. [5] reported a case of adenomatoid odontogenic tumor being developed in the fibrous capsule of the dentigerous cyst. Garcia-Pola et al. [4] described the proliferation of an adenomatoid odontogenic cyst in the epithelial border of a dentigerous cyst. We also noted proliferation from the cystic epithelial border and the fibrous capsule, as described by the aforementioned authors.

Immunohistochemically, the classical AOT shows positive staining with CK5, CK17, CK 19 and negative for CK 10, 13 and 18.11,12 Recently, Crivelini et al. [12] detected the expression of cytokeratin 14 in AOT and concluded its origin from the reduced dental epithelium which is also positive for cytokeratin 14 antibodies.

Conservative surgical enucleation with removal of the unerupted dental element is the treatment modality of choice, because of its low tendency to recur [4,5]. A more conservative approach to treatment is marsupialization of dentigerous cyst associated adenomatoid odontogenic tumor, and allow the later eruption of the dental element. Recurrence of AOT is exceptionally rare. Only three cases of recurrence in Japanese patients have been reported [5]. Therefore, the prognosis is excellent. No recurrence was seen in the present case.

To conclude, AOT is a relatively uncommon distinct odontogenic neoplasm and is rightfully called as ‘Master of Disguise’ and ‘Perfect imitator of dentigerous cyst’. It should be a part of differential diagnosis in any oral mass lesion in a young patient with unerupted tooth.

References

1. Miguel B, David W, Lili M, Robin C (2005) Adenomatoid odontogenic tumor mimicking a dentigerous cyst. *Int J Pediatr Otorhinolaryngol* 69(12): 1685-1688.
2. Alice EC, Edward JM, Valerie AM (2007) Adenomatoid odontogenic tumor presenting as periapical disease. *Oral Surg Oral Med Oral Pathol Oral Radiol Endodontol* 84(5): 557-560.
3. Batra P, Prasad S, Parkash H (2005) Adenomatoid odontogenic tumour: review and case report. *J Can Dent Assoc* 71(4): 250-253.
4. Leon JE, Mata GM, Fregnani ER, Carlos-Bregni R, Almeida OP, et al. (2005) Clinicopathological and immunohistochemical study of 39 cases of adenomatoid odontogenic tumour. *Oral Oncol* 41(8): 835-482.

5. Philipsen HP, Srisuwan T, Reichart PA (2002) Adenomatoid odontogenic tumor mimicking a periapical (radicular) cyst: a case report. *Oral Surg Oral Med Oral Pathol Oral Radiol* 94(2): 246-248.
6. Motamedi MH, Shafeie HA, Azizi T (2005) Salvage of an impacted canine associated with an adenomatoid odontogenic tumour: a case report. *Brit Dent J* 199(2): 89-90.
7. Lee JK, Lee KB, Hwang BN (2000) Adenomatoid odontogenic tumor: a case report. *J Oral Maxillofac Surg* 58: 1161-1164.
8. Cassiano F, Weege N, Lélia BS, Lêda BQ (2007) Adenomatoid odontogenic tumour associated with dentigerous cyst - unusual case report. *Rev Bras Otorrinolaringol* 73(1):135-137.
9. Robert EM and Diane Stern (2003) *Oral and Maxillofacial Pathology-A rationale for diagnosis and treatment*. Quintessence publishing co, USA, pp. 609-611.
10. Philipsen HP, Reichart PA, Zhang KH, Nikai H, Yu QX (2002) Adenomatoid odontogenic tumor mimicking a periapical (radicular) cyst: A case report. *Oral Surg Oral Med Oral Pathol Oral Radiol Endod* 94(2): 246-248.
11. Larsson A, Swartz K, Heikinheimo K (2003) A case of multiple AOT-like jawbone lesions in a young patient- a new odontogenic entity? *J Oral Pathol Med* 32(1): 55-62.
12. Jain MK and Oswal KS (2014) Adenomatoid Odontogenic Tumor of Mandible - 'Master of Disguise'. *J Dent App* 1(3): 40-42.



This work is licensed under Creative Commons Attribution 4.0 License
DOI: [10.19080/ARGH.2017.03.555604](https://doi.org/10.19080/ARGH.2017.03.555604)

Your next submission with Juniper Publishers will reach you the below assets

- Quality Editorial service
- Swift Peer Review
- Reprints availability
- E-prints Service
- Manuscript Podcast for convenient understanding
- Global attainment for your research
- Manuscript accessibility in different formats
(Pdf, E-pub, Full Text, Audio)
- Unceasing customer service

Track the below URL for one-step submission

<https://juniperpublishers.com/online-submission.php>