



Case Report

Volume 4 Issue 2 – March 2017
DOI: 10.19080/ARGH.2017.04.555635

Adv Res Gastroentero Hepatol

Copyright © All rights are reserved by Kashish Khanna

Milk Curd Syndrome: A Forgotten Entity



Kashish Khanna*, Vikram Khanna, Anjan Dhua and Veereshwar Bhatnagar

Department of Pediatric Surgery, All India Institute of Medical Sciences, India

Submission: February 12, 2017; Published: March 27, 2017

*Corresponding author: Kashish Khanna, Department of Pediatric Surgery, All India Institute of Medical Sciences, India, Tel: 9811866150; Email: kash.modern@gmail.com

Abstract

A full term neonatal baby girl presented with a lumbosacral meningomyelocele and underwent successful excision and repair. In the post-operative period, she developed abdominal distension, bilious vomiting and did not pass stools. Conservative management for ileus/intestinal obstruction failed. The abdominal exploration revealed milk curd syndrome (MCS) as a cause of intestinal obstruction. This article highlights the varied presentation of MCS and salient features to differentiate it from other causes of neonatal intestinal obstruction.

Keywords: Neonatal intestinal obstruction; Milk curd syndrome; Inspissated milk syndrome; Milk plug syndrome

Abbreviations: MCS: Milk Curd Syndrome; SBE: Small Bowel Obstruction; NEC: Necrotising Enterocolitis; MMC: Meningomyelocele; TCA: Total Colonic Aganglionosis

Introduction

Milk curd syndrome (MCS) is an unusual cause of neonatal small bowel obstruction (SBO) that was first described in 1969 [1]. Its incidence has decreased after the realization that avoiding formula feeds rich in calcium and fat can prevent it, especially in a premature baby. Lohn described 43 cases of lactobezoars upto 1980 but only 2 cases in the next 2 decades [2]. Even then, sporadic cases of MCS have been described in the literature since 2000, causing not only SBO but also presenting with caecal perforation [3], necrotising enterocolitis (NEC) [4] or gastric perforation [5]. Herein, we describe a case of MCS in a term neonate operated primarily for lumbosacral myelomeningocele (MMC).

Case Report

A full term baby girl weighing 2500 grams, delivered by a lower segment caesarean section presented with a cystic swelling in the lower back on her first day of life. The baby had already passed urine and meconium. The antenatal, perinatal and postnatal history was unremarkable. Clinically the child was diagnosed as a case of lumbosacral MMC without any neurological deficits or hydrocephalus. This was confirmed by an ultrasound of the spine and cranium. The child underwent excision of the MMC with laminotomy and detethering of the cord and she had an uneventful immediate postoperative period. Child could not be breast fed postoperatively as her mother was admitted at a

peripheral hospital post caesarean section delivery, so formula feeds (Lactodex) were started from the second postoperative day. On the fourth postoperative day the child developed intolerance to feeds with bilious vomiting, abdominal distension and constipation. Preoperatively the child had passed meconium on day one of life and had normal stool habits. A radiograph showed dilated small bowel loops and paucity of bowel gas in the central and right lower quadrant (Figure 1a & 1b).

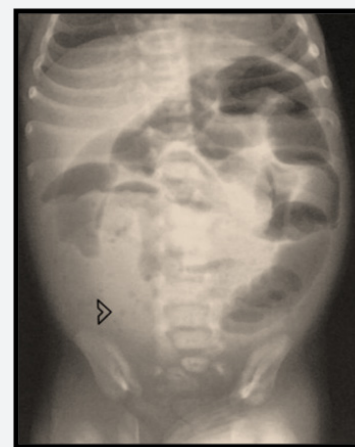

Figure 1a: Dilated small bowel loops and paucity of bowel gas in the central and right lower quadrant (arrow head).

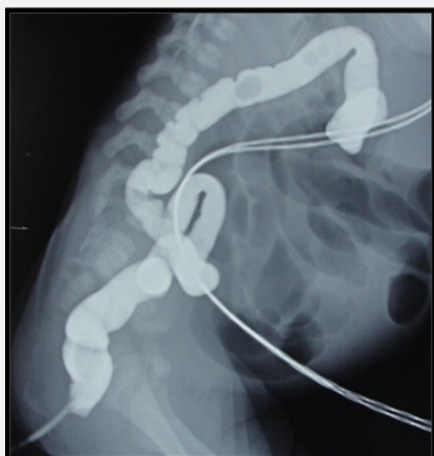

Figure 1b: A narrow caliber colon loaded with pellets.

A diagnosis of neonatal intestinal obstruction was made and the child was managed conservatively for 24 hours. NEC was unlikely as the baby was full term, appropriate for gestational age and the sepsis screen was negative. A contrast enema ruled out atresia but it showed a microcolon loaded with pellets. Since the child did not decompress with repeated attempts of enema and had progressively increasing abdominal distension, emergency exploratory laparotomy was planned.

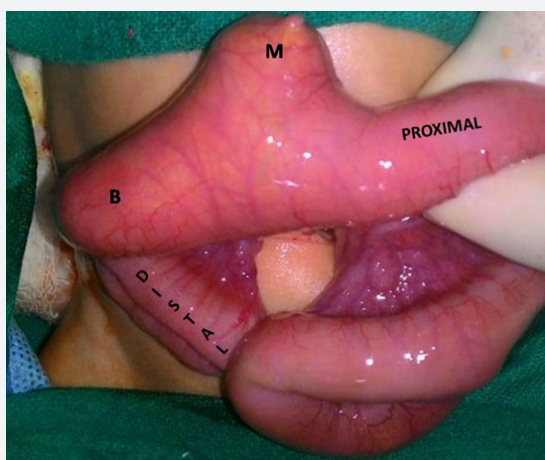


Figure 2: Intra-operative image (after decompression of proximal bowel through nasogastric tube) showing sudden cut-off at the level of the impacted bolus (B). The bolus was extending proximally inside the lumen of Meckel's diverticulum as well (M).

On laparotomy, the entire small bowel was grossly dilated up to 10 cm proximal to the ileo-cecal junction with an abrupt cut off, beyond which, terminal ileum and the entire colon was collapsed and empty. A Meckel's diverticulum present just proximal to the cut off was also distended. At the region of transition, a firm bolus of inspissated intra-luminal content was palpated that was extending proximally and was also filling the Meckel's diverticulum (Figure 2). An attempt was made to milk the contents distally but failed. Hence,

a longitudinal enterotomy at the distal most portion of the transition point was performed and the material (curdled milk) was extracted piece meal. Distal bowel patency was checked and the enterotomy was repaired transversely. A biopsy was also taken from the distal most enterotomy site (Figure 2).

In the postoperative period, the baby developed burst abdomen with fecal discharge from the wound and was therefore re-explored. The enterotomy had given way and a double barrel ileostomy with abdominal closure was done. Subsequently oral feeds were gradually initiated and the baby was discharged. A suspicion of total colonic aganglionosis (TCA) was raised. However, the colonic biopsy and a rectal biopsy both ruled out aganglionosis.

After 3 weeks, the baby was not thriving well despite adequate feeds due to the continued high stomal losses. Hence an early closure of the stoma was performed at the age of 3 months. The child was feeding well, had gained weight adequately and was asymptomatic at last follow-up at 8 months of age.

Discussion

MCS, inspissated milk syndrome, lacto bezoar, milk plug syndrome etc. are synonyms for a condition wherein the neonatal small bowel gets impacted by a plasticine like gritty bolus occurring possibly due to differential absorption of water and solid contents of milk [6]. Cook and Rickham first described this in 1969 and subsequently Cremin described the radiological aspects of this condition in 1970 [1,7]. This syndrome was fairly common during the era when formula feeds were manufactured by just drying of cow's milk with around 70 case reports in world literature by 1980. Subsequent understanding of the neonatal physiology and modification of the composition of formula have made this entity a rarity. Usually males are more commonly affected than females. The earliest report described term babies developing MCS as seen in our patient but, subsequent reports described nearly all cases in preterm babies in whom high calorie feeds were initiated soon after birth [4].

The usual presentation is with features of small bowel obstruction i.e. bilious vomiting, abdominal distension after the neonate has passed through the stages of passage of normal meconium followed by transition stools and normal milk stools. The peak incidence of MCS occurs between 5 to 14 days of life. Our case also had a very similar course and presented with frank features of SBO on day 6 of life after having passed normal stools in the initial 1 week of life.

Abdominal x ray usually shows the characteristic features of air intermixed with stools in the distal small bowel with proximal distended bowel loops. A feature also common with meconium ileus is the scarcity of air fluid levels. Paucity of air fluid levels and a soap bubble appearance in abdominal skiagram were also noted in this case.

A contrast enema should usually be done, both for diagnostic as well as therapeutic purposes. It should be able to distinguish the microcolon found in ileal atresia or proximal colonic atresia.

It can be therapeutic in cases of meconium ileus. In MCS, a trial of gastrograffin enema may be tried initially based on the same principle as that for treatment of meconium ileus. Generally however, conservative methods fail and this necessitates surgical intervention in the form of enterotomy and removal of the bolus. If diagnosed early, simple milking of the contents distally may be sufficient. In cases associated with perforation, resection and anastomosis may also be required.

TCA can have variable findings on contrast enema and the exact differentiation based on contrast enema alone may be difficult. Hence, apart from history and clinical examination, multiple bowel biopsy and/or rectal biopsy are needed for confirmation. In our case the contrast enema that was done prior to exploration did not have any suggestion towards TCA except for microcolon but the history of normal passage of stools initially and the intra-operative findings of inspissated curdled milk were so classical that a diagnosis of MCS was formed. Subsequently as the child developed a burst abdomen and dehiscence of the enterotomy, we realised the importance of intra-operative bowel and rectal biopsy. An appendectomy could also have been done and sent for biopsy to look for ganglion cells, though debatable in our case as the child had a prior surgery for neural tube defect and preserving the appendix for later use was also important.

In retrospect, our case had few features similar to meconium ileus, but on exploration, it turned out to be MCS. Though the diagnosis of MCS was low on our index of clinical suspicion, diagnosing it early in the course of treatment would not have changed the immediate therapeutic strategies. An intraoperative bowel biopsy and rectal biopsy ruled out TCA.

Conclusion

MCS though rare now days can still be a cause for neonatal intestinal obstruction especially in formula fed neonates. It is difficult to diagnose unless there is a high index of clinical suspicion. Secondly, to differentiate it from other causes of intestinal obstruction, a proper history of normal initial stool habits and intake of formula feeds apart from radiological investigations and rectal biopsy are of utmost importance in clinching the diagnosis.

References

1. Cook RC, Rickham PP (1969) Neonatal intestinal obstruction due to milk curds. *J Pediatr Surg* 4(6): 599-605.
2. Lohn JW, Austin RC, Winslet MC (2000) Unusual causes of small-bowel obstruction. *J R Soc Med* 93(7): 365-8
3. Karkiner A, Temir G, Hoşgör M, Günşar C, Karaca I (2003) Cecal perforation in a premature newborn infant complicating milk curd syndrome: case report. *Turk J Gastroenterol* 14(2): 148-150.
4. Jain A, Godambe SV, Clarke S, Chow PC (2009) Unusually late presentation of lactobezoar leading to necrotising ente-rocolitis in an extremely low birthweight infant. *BMJ Case Rep pii: bcr03.2009.*
5. Bos ME, Wijnen RM, de Blaauw I (2013) Gastric pneumatosis and rupture caused by lactobezoar. *Pediatr Int* 55(6): 757-760.
6. Lewis CT, Dickson JA, Swain VA (1977) Milk bolus obstruction in the neonate. *Arch Dis Child* 52(1): 68-71.
7. Cremin BJ, Smythe PM, Cywes S (1970) The radiological appearance of the "inspissated milk syndrome"; a cause of intestinal obstruction in infants. *Br J Radiol* 43(516): 856-858.



This work is licensed under Creative Commons Attribution 4.0 License
DOI: [10.19080/ARGH.2017.04.555635](https://doi.org/10.19080/ARGH.2017.04.555635)

Your next submission with Juniper Publishers will reach you the below assets

- Quality Editorial service
- Swift Peer Review
- Reprints availability
- E-prints Service
- Manuscript Podcast for convenient understanding
- Global attainment for your research
- Manuscript accessibility in different formats
(Pdf, E-pub, Full Text, Audio)
- Unceasing customer service

Track the below URL for one-step submission

<https://juniperpublishers.com/online-submission.php>