



Case Report

Volume 11 Issue 3 - October 2018  
DOI: 10.19080/ARGH.2018.11.555813

Adv Res Gastroentero Hepatol

Copyright © All rights are reserved by Valerii Giorgio

# Unexpected Delayed Rectal Perforation after Endoscopic Submucosal Dissection



Valerii Giorgio<sup>1\*</sup>, Hamanaka Jun<sup>1,2,3</sup>, Costamagna Guido<sup>1</sup> and Riccioni Maria Elena<sup>1</sup>

<sup>1</sup>Digestive Endoscopy Unit, Fondazione Policlinico Universitario Agostino Gemelli, Italy

<sup>2</sup>Department of Gastroenterology, Yokohama Minami Kyosai Hospital, Japan

<sup>3</sup>Department of Gastroenterology, Yokohama City University, Japan

**Submission:** October 05, 2018; **Published:** October 15, 2018

**\*Corresponding author:** Valerii Giorgio, Digestive Endoscopy Unit, Fondazione Policlinico Universitario Agostino Gemelli Catholic University, Rome, Italy, Tel:+393804533082; Email: gioval83@hotmail.it

## Abstract

Superficial gastrointestinal neoplasia may be removed endoscopically. ESD (Endoscopic submucosal dissection) is an effective and safe procedure which allows "en bloc" resection of superficial gastrointestinal lesions. The most common adverse events of ESD are perforation and bleeding. Late perforation are rare and occur in 0.22% according to literature. We report a case of delayed rectal perforation, occurring 16 days after ESD of a 65 x 35-mm laterally spreading tumor (LST) nodular mixed type (G-MIX), of the rectum. The perforation was completely unexpected because of absence of post-ESD risk factors and the long period of wellness of the patient after the procedure.

**Keywords:** Colorectal lesion; Endoscopic Submucosal; Dissection; Delayed rectal perforation

**Abbreviations:** LST: Laterally Spreading Tumor; G-MIX: Nodular Mixed Type; EMR: Endoscopic Mucosal Resection; ESD: Endoscopic Submucosal Dissection; NBI: Narrow Band Imaging; TEM: Trans anal Endoscopic Microsurgery

## Introduction

Superficial gastrointestinal tumor may be removed endoscopically. Endoscopic mucosal resection (EMR) is one of the most useful endoscopic technique to remove gastrointestinal superficial neoplasia, endoscopic submucosal dissection (ESD) is a new endoscopic technique to overcome EMR limits (en bloc resection of lesions larger than 20 mm or non-lifting lesions).

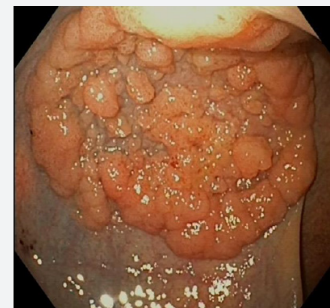
ESD is nowadays considered an effective and safe endoscopic technique. Colorectal ESD can be considered to perform en bloc resection of the large lesions (>20 mm) or to ensure an accurate histopathologic evaluation and a radical treatment with lower risk of relapse [1].

ESD, however, requires greater skill, longer operation time and higher costs than EMR with a higher incidence of serious adverse events such as immediate (4.2%) or delayed (0.22%) perforation [2]. We report a case of late rectal perforation, 16 days after endoscopic removal of a 65 x 35-mm laterally spreading tumor (LST) G-MIX (nodular mixed type) in the rectum using a standard ESD technique.

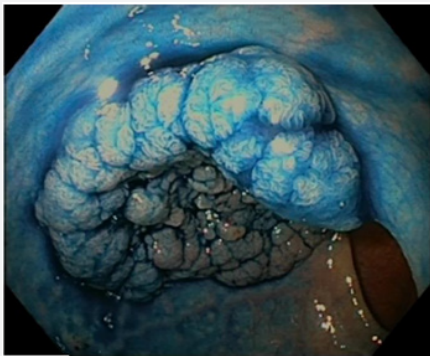
## Case Report

An 82-year-old woman without relevant past medical history except for high blood pressure on medication, underwent

colonoscopy due to the occurrence of rectal bleeding; colonoscopy revealed a rectal LST G-MIX, starting 15 cm from the anal canal and extending proximally, measuring 65 x 35 mm endoscopically (Figure 1a). Virtual chromoendoscopy (Narrow band imaging NBI) and after Indigo carmine (0.4%) were performed in order to characterize and to establish the feasibility for endoscopic treatment of the lesion (Figure 1b). The lesion had a type IV pit pattern (Figure 1b), according to Kudo classification. ESD was performed under deep sedation with propofol. Submucosal injection was performed with Glycerol 10% and sodium chloride 0.9% mixed with Adrenaline (1:10000) and indigo carmine.

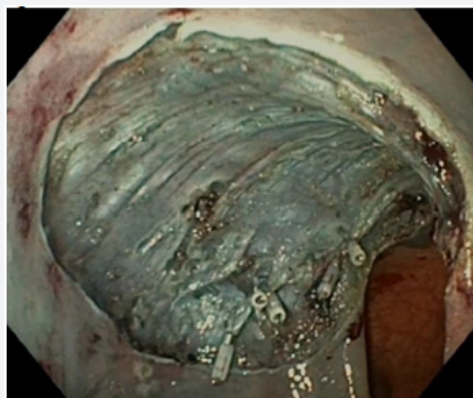


**Figure 1(a):** Laterally spreading tumor (LST) G-MIX (nodular mixed type) in the rectum.

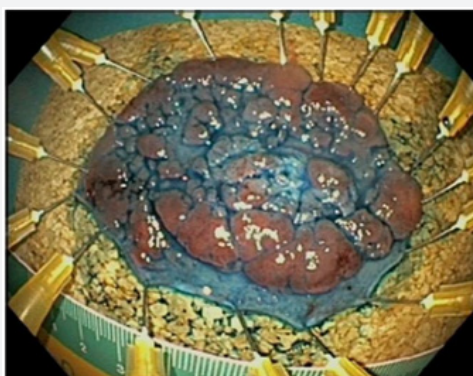


**Figure 1(b):** Laterally spreading tumor (LST) G-MIX (nodular mixed type) in the rectum after chromoendoscopy with indaco carmine.

Subsequently, circumferential incision to access the submucosa was performed beginning from the mucosa proximal to the tumor. Local injections were repeated with subsequent dissection of the submucosa over the muscular layer to distal side of the tumor (Figure 2). Submucosal dissection was performed with the Dual Knife (Olympus, Tokyo, Japan). Coagrasper (FD-410LR; Olympus) was performed to coagulate large visible vessels or bleeding sites. Finally, the submucosal layer was dissected, and the tumor was resected en bloc (Figure 3).



**Figure 2:** Post-ESD ulcer base with clips, clean without bleeding or severe coagulation injury.

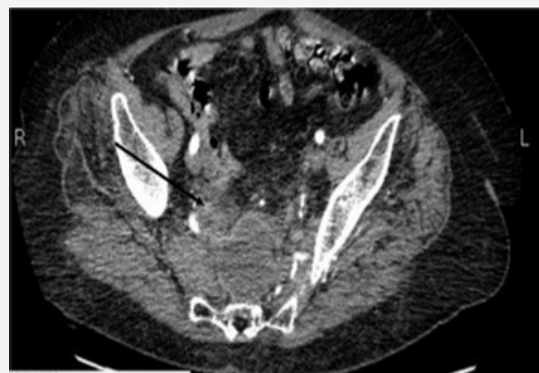

**Figure 3:** Endoscopic resection specimen with indaco carmine.

The procedure time required for ESD was 70 minutes. No immediate procedure-related complications were noted. To prevent late bleeding and perforation, clipping of visible vessel with hemoclip (Olympus, Tokyo, Japan) was performed.

The tumor measured 65×35 mm (Figure 3). Microscopic examination revealed a tubulovillous adenoma with high-grade of dysplasia, vertical and lateral margins were negative (Figure 3). There was no evidence of histological damage to the muscular layer by any cautery effect or air. The following morning her white blood cell count was normal. The first follow-up was scheduled, with phone contact, after 10 days.

However, 16 days after ESD the patient complained mild abdominal pain and fever with a slight leukocytosis. Ultrasonography revealed free fluid with specks of air in peritoneal cavity. CT scan of the abdomen and pelvis revealed intraperitoneal air and fluid in the pelvic region and mesorectum-mesosigmoid with an organized collection in the presacral space and irregularities at the endoscopic resection site (Figure 4).



**Figure 4:** Abdominopelvic computed tomography showing the site of perforation.

Broad spectrum antibiotics were administered, and CT-guided drainage of the pelvic collection was performed. CT-scan was performed 72 hours after the drainage, percutaneous drainage of the collection was not effective and due to the persistence of fever and increase of white blood cell the patient underwent surgery and a loop colostomy of the transverse colon was performed after thorough irrigation of the peritoneal cavity. Post-operative course was uneventful, and the patient was discharged after 7 days from surgery.

### Discussion

Colorectal ESD seems to be an extremely safe and effective procedure (1) providing en bloc resection with accurate histopathologic assessment particularly for lesions larger than 20 mm, with a relatively low risk of recurrence and 88% R0 resection rate [3,4]. Transanal endoscopic microsurgery (TEM) procedures have a higher recurrence rate than ESD (5.2 % versus 2.6 %) [5,6]. The most common adverse events after gastrointestinal ESD are immediate or delayed perforation and major bleeding [1].

Risk factors for ESD perforation are well known (fibrosis, lesion diameter (i.e.,  $\geq 50$  mm), low endoscopist experience in ESD) [7].

The reported rates of immediate and delayed major bleeding after colorectal ESD, are 0.75% (95% CI, 0.31–1.8 %) and 2.1% (95% CI, 1.6–2.6 %); immediate perforation are reported in 4.2% of the cases (95% CI, 3.5–5.0 %) whereas delayed perforation is very rare (0.22%, 95% CI, 0.11–0.46 %) [5] and in one-third of the cases diagnosed within 24 hours [4]. Thirty studies reported delayed perforation after colorectal ESD in 3887 lesions [4].

Abdominal pain, fever and an inflammatory response are signs and symptoms of supposed delayed perforation, often caused by an electrical or thermal injury after electrocoagulation, also named Coagulation Syndrome (CS) [8,9]. The diagnosis of delayed perforation is performed by CT-scan with contrast [8]. CS is an electrocoagulation injury to the muscularis propria and serosa during polypectomy, EMR or ESD that induces a transmural burn without perforation [7,8,10]. Delayed perforation caused by CS is usually severe and often requires surgery. In the current case the rectal perforation was diagnosed 16 days after ESD of an LST in the rectum and furthermore unexpected.

The patient was healthy, and the only risk factor was hypertension but well controlled with medication; there were no ESD-associated risk factors for perforation except tumor size ( $> 50$  mm), no severe coagulation damage was apparent at the post-ESD ulcer base. Therefore, endoscopists should closely evaluate patient also after clean ESD, and in case of suspicious abdominal pain perform CT scan with contrast. Delayed perforation, after 16 days from an uneventful procedure, is a rare but possible serious adverse event of ESD.

### Conflict of Interests

Guido Costamagna has received grant/research support from Olympus Japan, is a member of advisory committees or review panels for Cook, Inc., Boston Scientific Corp., and Taewoong

Medical, Inc., and has been a speaker and teacher for Boston Scientific, Corp. and Given Imaging.

### References

1. Pimentel-Nunes P, Dinis-Ribeiro M, Ponchon T, Repici A, Vieth M, et al. (2015) Endoscopic submucosal dissection: Endoscopic submucosal dissection: European Society of Gastrointestinal Endoscopy (ESGE) Guideline. *Endoscopy* 47(9): 829-854.
2. Tamegai Y, Saito Y, Masaki N, Hinohara C, Oshima T, et al. (2007) Endoscopic submucosal dissection: a safe technique for colorectal tumors. *Endoscopy* 39(5): 418-422.
3. Repici A, Hassan C, De Paula Pessoa D, Pagano N, Arezzo A, et al. (2012) Efficacy and safety of endoscopic submucosal dissection for colorectal neoplasia: a systematic review. *Endoscopy* 44(2): 137-150.
4. Akintoye E, Kumar N, Aihara H, Nas H, Thompson CC (2016) Colorectal endoscopic submucosal dissection: a systematic review and meta-analysis. *Endoscopy International Open* 4(10): E1030-E1044.
5. Maslekar S, Beral DL, White TJ, Pillinger SH, Monson JRT (2006) Transanal endoscopic microsurgery: where are we now? *Dig Surg* 23(1-2): 12-22.
6. Arezzo A, Passera R, Saito Y, Sakamoto T, Kobayashi N, et al. (2014) Systematic review and meta-analysis of endoscopic submucosal dissection versus transanal endoscopic microsurgery for large noninvasive rectal lesions. *Surg Endosc* 28(2): 427-438.
7. Kim ES, Cho KB, Park KS, Lee KI, Jang BK, et al. (2011) Factors predictive of perforation during endoscopic submucosal dissection for the treatment of colorectal tumors. *Endoscopy* 43(7): 573-578.
8. Isomoto H, Nishiyama H, Yamaguchi N, Fukuda E, Ishii H, et al. (2009) Clinicopathological factors associated with clinical outcomes of endoscopic submucosal dissection for colorectal epithelial neoplasms. *Endoscopy* 41(8): 679-683.
9. Yamashina T, Takeuchi Y, Uedo N, Hamada K, Aoi K, et al. (2016) Features of electrocoagulation syndrome after endoscopic submucosal dissection for colorectal neoplasm. *J Gastroenterol Hepatol* 31(3): 615-620.
10. Saito Y, Uraoka T, Yamaguchi Y, Hotta K, Sakamoto N, et al. (2010) A prospective, multicenter study of 1111 colorectal endoscopic submucosal dissections (with video). *Gastrointest Endosc* 72(6): 1217-1225.



This work is licensed under Creative Commons Attribution 4.0 License  
DOI: [10.19080/ARGH.2018.11.555813](https://doi.org/10.19080/ARGH.2018.11.555813)

#### Your next submission with Juniper Publishers will reach you the below assets

- Quality Editorial service
- Swift Peer Review
- Reprints availability
- E-prints Service
- Manuscript Podcast for convenient understanding
- Global attainment for your research
- Manuscript accessibility in different formats  
( Pdf, E-pub, Full Text, audio)
- Unceasing customer service

Track the below URL for one-step submission  
<https://juniperpublishers.com/online-submission.php>