



Research Article

Volume 7 Issue 4 - October 2017
DOI: 10.19080/CTOIJ.2017.07.555718

Canc Therapy & Oncol Int J

Copyright © All rights are reserved by Masao Sugamata

Mast Cell Infiltration and Leukotriene Receptor Expression in Colorectal Adenoma: Preventive Application of Malignant Transformation Based on Common Pathological Findings



Masao Sugamata^{1*}, Tomomi Ihara¹, Miho Sugamata¹, Yasunari Mano² and Ken Takeda³

¹Department of Pathology, Tochigi Institute of Clinical Pathology, Tochigi, Japan

²Department of Clinical Drug Informatics, Tokyo University of Science, Japan

³Department of Hygiene Chemistry, Tokyo University of Science Sanyo Onoda Yamaguchi, Japan

Submission: October 05, 2017; **Published:** October 25, 2017

***Correspondence Address:** Masao Sugamata, Department of Pathology, Tochigi Institute of Clinical Pathology, Tochigi, 2308-3, Minamiakatsuka, Nogi, Tochigi, 3290112, Japan, Tel: +81-280-56-1278; Fax: +81-280-56-2792; Email: mspathol@beige.ocn.ne.jp

Abstract

The prevention of the malignant tumor is thought to be early detection, because the mechanism that tumor cells result, and progresses has not been yet made clear. We have already identified leukotriene receptor expression and mast cells infiltration; these are common pathologic findings in various malignant tumors. In this time, we detected a similar common pathologic finding for polyp of colon suggestive of the precancerous change in the purpose of preventing malignant tumor and examined a malignant transformation risk and the association of these findings. Thirty samples of colorectal adenoma (colonic polyp) tissues obtained from patients with high-grade dysplasia (n=15) or low-grade dysplasia (n=15). These samples were observed mast cells and detected of leukotriene receptors under a light microscope, and were compared using statistical analysis. Mast cells infiltration and the expression of leukotriene receptor were common in the colonic polyp tissues and, similar to malignant tumors, were found.

The tendency with difference had these findings between histopathology classifications. Especially, the number of mast cells was significantly greater within high-grade than within low-grade ($P < 0.0001$). From these results, the possibility that mast cells and leukotriene receptor were associated with the transitional mechanisms from benign tumor to malignant tumor was shown. The chronic hypersensitivity through leukotriene was thought to have influence on the malignant transformation of colonic polyps. Leukotriene receptor antagonist may have high effect of malignant transformation prevention in colonic polyps.

Keywords: Colorectal adenoma; Mast cell; Leukotriene receptor; Low-grade dysplasia; High-grade dysplasia

Abbreviations: LT: Leukotriene; CysLT: Cysteinyl Leukotriene; SD: Standard Deviation

Introduction

The main therapies for malignant tumors are surgery, chemotherapy, and radiotherapy. However, we cannot save all patients with these therapies. Therefore, early detection and early treatment are thought to be the most important factors for managing malignant tumors. Furthermore, benign tumors are treated by surgical removal, if necessary, and the patient then receives periodic examinations to detect malignant transformation early. Why is there only this method? It is because the mechanisms of development and of the extension of tumor cells have not yet been made clear.

We have already detected mast cell infiltration and leukotriene (LT) receptors as common pathologic findings in various kinds of tumor tissues, particularly malignant tumor

tissues. Based on these pathologic findings, we proved that a leukotriene receptor antagonist had a treatment effect for malignant tumors using rat spontaneous mammary tumor tissue [1]. Until then, there had been some reports indicating the relationship with LT and tumor that focused on LTB₄, which is related to neutrophils and monocytes. LTs that we paid our attention to this time are said to include LTC₄, D₄, and E₄, which is cysteinyl leukotriene (CysLT), and it is closely associated with mast cells and eosinophils. Taking into account the results of this therapeutic investigation, it was thought that a growth factor associated with chronic hypersensitivity was present in malignant tumor tissue, and it was related to histamine, prostaglandin, LTs, and some stromal growth factors. The LT receptor antagonist of interest induced apoptosis in the cells

in the rat spontaneous mammary tumor tissue and inhibited angiogenesis and peripheral nerve formation. Thus, we were able to conclude that it had a high antitumor effect.

Colonic polyps (colorectal adenomas), which are benign tumors, are considered precancerous lesions. This study focused on colorectal adenomas from the perspective of preventing malignant tumors, and the presence of a common pathologic finding similar to a malignant tumor and its association with grade was confirmed. This report is the first to indicate that the presence of mast cell infiltration and leukotriene receptors is associated with the transitional mechanisms from a benign tumor to a malignant tumor.

Materials and Methods

Tissue Samples

Thirty samples of colorectal adenoma tissues obtained from patients who were diagnosed with high-grade dysplasia (HG: n=15) or low-grade dysplasia (LG: n=15) confirmed by surgical pathology were evaluated. Tissues were sampled after the patients gave their informed consent in accordance with the Helsinki Declaration.

Histopathology, Localization of Mast Cells, and Detection of Leukotriene Receptors using Immunohistochemical staining

The tissue samples from colon adenomas were fixed with 10% buffered formalin, and after routine dehydration, they were embedded in paraffin. Sections 5- μ m-thick were stained with hematoxylin and eosin and examined under a light microscope.

To identify mast cells in each specimen, the paraffin sections were stained with toluidine blue. Because the granules within mast cells contain heparin and sulfated glycosaminoglycan, they were stained metachromatically with toluidine blue. The 5- μ m-thick sections were stained for 30 minutes with a staining solution containing a 0.05% concentration of toluidine blue O (Kanto Chemical Co., Inc., Tokyo, Japan) in a citric acid phosphate buffer (pH 2.5), and they were then examined by

light microscopy. Immunohistochemical staining for cysteinyl leukotriene receptors (CysLT) 1 and 2 was performed to detect the expressions of the leukotriene receptors in the tissues under a light microscope. The 5- μ m-thick tissue sections were stained immunohistochemically using the streptavidin-biotin method (Histofine SAB-PO Kit; Nichirei, Tokyo, Japan). The primary antibodies used were polyclonal antibody to CysLT1 and polyclonal antibody to CysLT2 (Acris Antibodies, Inc., San Diego, CA, USA).

Tabulation of Mast Cells and Statistical Analysis

On all sections stained with toluidine blue, mast cells were observed by light microscopy. In each sample, the number of mast cells per field (20 objective, 10 ocular) was counted throughout the specimen, and then the mean number and standard deviation (SD) were calculated. The mean mast cell numbers in the HG and LG adenomas were compared using Welch's test. Statistical analysis was performed using a software program, and significance was defined as $P < 0.05$.

Results

Localization of Mast Cells and Detection of Leukotriene Receptors

Localization of Mast Cells and Detection of Leukotriene Receptors by Immunohistochemical Staining Mast cell infiltration and expression of CysLTs were found in all cases of colorectal adenoma that were examined, and these findings were common to HG and LG adenomas. These mast cells were diffusely distributed within the adenomas (Figure 1), and such a diffuse distribution was very similar to that of mast cells in lesions of malignant tumor patients that we previously studied [1]. CysLT-positive cells that were diffusely distributed within the adenoma were observed in all cases (Figure 2). Positive reactivity to the anti-CysLT antibodies was detected not only in tumor cells, but also in fibroblasts, mast cells, and endothelial cells within the adenoma. In both HG and LG adenomas, there was a strong tendency for CysLT1 to show a more positive reaction than CysLT2.

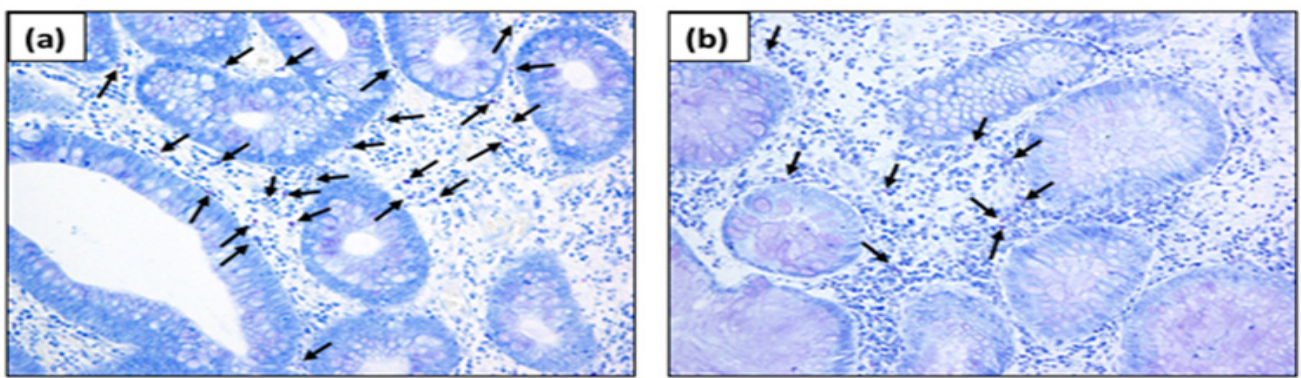


Figure 1: Detection of mast cells in colorectal adenomas by toluidine blue staining.

Positively stained cells (Violet color: arrows) are mast cells.

(a) HG adenoma (Mag: 200x).

(b) LG adenoma (Mag: 200x).

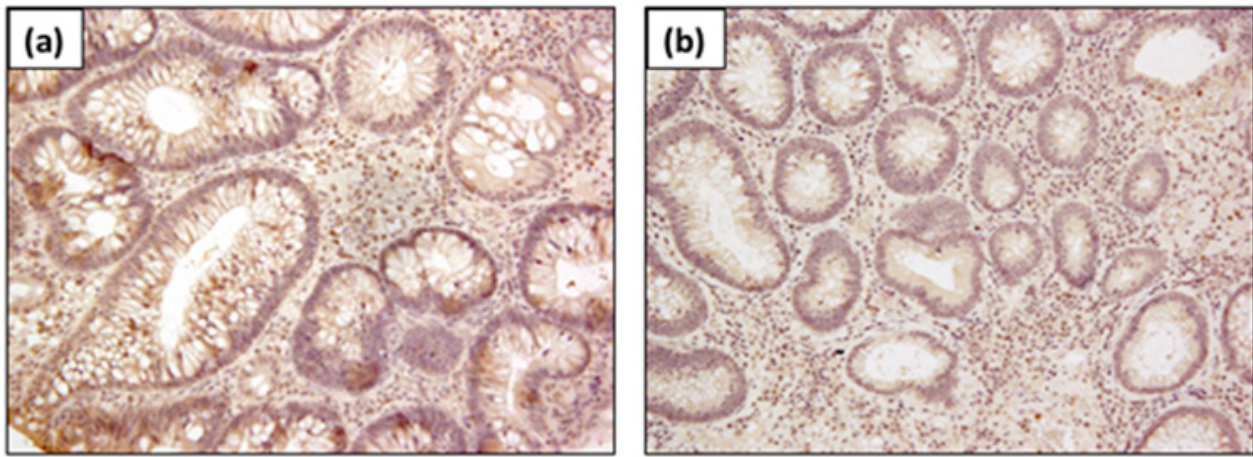


Figure 2: Detection of CysLT expression in colorectal adenomas by immunohistochemical staining. The brown colour denotes positive staining.
 (a) HG adenoma (Mag: 200x).
 (b) LG adenoma (Mag: 200x).

Tabulation of Mast Cells and Statistical Analysis

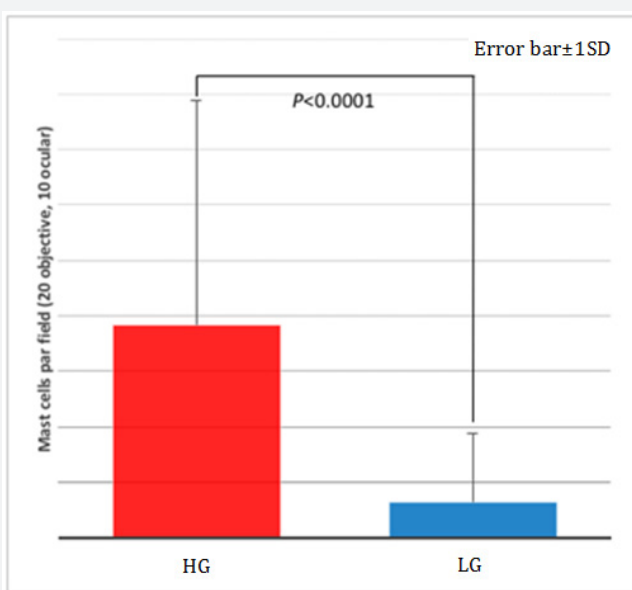


Figure 3: Association between histopathology classification and mast cells infiltration in colorectal adenoma. The number of mast cells was significantly greater within HG adenomas than within LG adenomas ($P < 0.0001$, errors bar: $\pm 1SD$).

The number of counted fields per specimen was 26.87 ± 10.96 in HG adenomas and 20.50 ± 6.97 in LG adenomas. The mean $\pm SD$ mast cell counts were 1.28 ± 2.50 in 7.67 ± 7.08 in HG adenomas and 1.28 ± 2.50 in LG adenomas; the number of mast cells was significantly greater within HG adenomas than within LG adenomas (Figure 3); $P < 0.0001$.

Discussion

Given common findings in the tumor tissues, the following mechanism of oncogenesis and its extension can be proposed (Figure 4). First, with various stimuli (biologic, chemical, or

mechanical), a hypersensitivity reaction is caused, and then this hypersensitivity reaction becomes chronic when the stimulation continues. With this chronic inflammation, the tissue cells repeatedly undergo damage and repair. Normal cell division and reproduction are not performed while the cells repeatedly undergo repair and reproduction (gene mutations may also be caused then). The cells continue multiplying, and their cell cycles become abnormal, and, as a result, the cells acquire the properties of tumor cells.

Current antitumor treatment is basically intended to target tumor cells. Surgery, radiation, and anticancer drugs remove tumor cells or cause their necrosis. However, our mechanism suggests that the tumor will soon recur if we do not block chronic hypersensitivity inflammation. It is basically impossible to remove a carcinogen. In other words, the carcinogen varies, and the presence of chronic hypersensitivity inflammation is greatly associated with the occurrence of tumors and their extension, and with respect to the control of factors associated with this hypersensitivity reaction (inflammatory factors and growth factors), it is pivotal to the strategy for tumor control.

Several reports have suggested that prostaglandin is one of the inflammatory factors and is related to tumors [2-6]. However, prostaglandin is present in various organs, and it has widespread effects. On the other hand, the LT receptor that we identified has an antagonist, and it is easy to control. In addition, LT receptors are present in all benign tumors and malignant tumor tissue and we have already shown the effect of treatment for the spontaneous rat mammary tumor, as shown by our conventional study [1]. And the effect of treatment for animal models of colon cancer is actually reported [7], too. Interestingly, we confirmed the leukotriene receptor expression of tumor tissue by immunostaining, and whereas they confirmed the receptor of tumor cells by Western blot. In other words, if a

tumor tissue can confirm the LT receptor because any method is enough, the patients with those tumors will obtain a sufficient antitumor effect from this antagonist.

After our report, an epidemiological analysis using Taiwanese large healthcare database (medical big data) were reported, this is the cohort study with which cancer incidence of the users of LT receptor antagonist and non-users is compared. According to that report, LT receptor antagonist administration significantly

decreased the risk of various malignant tumors (total cancer incidence hazard ratio in 0.31, individual: lung cancer; 0.34, colorectal cancer; 0.35, liver cancer; 0.34, breast cancer; 0.09, etc.) [8]. Besides, some similar cohort studies are conducted about the prostaglandin, however, the reduce of cancer incidence like the LT receptor antagonist is not obtained (for example, colon cancer; 0.74, rectal cancer; 0.90) [9]. From the comparison of these reports, the leukotriene receptor antagonist is shown to be superior to prostaglandin as tumor preventive medicine.

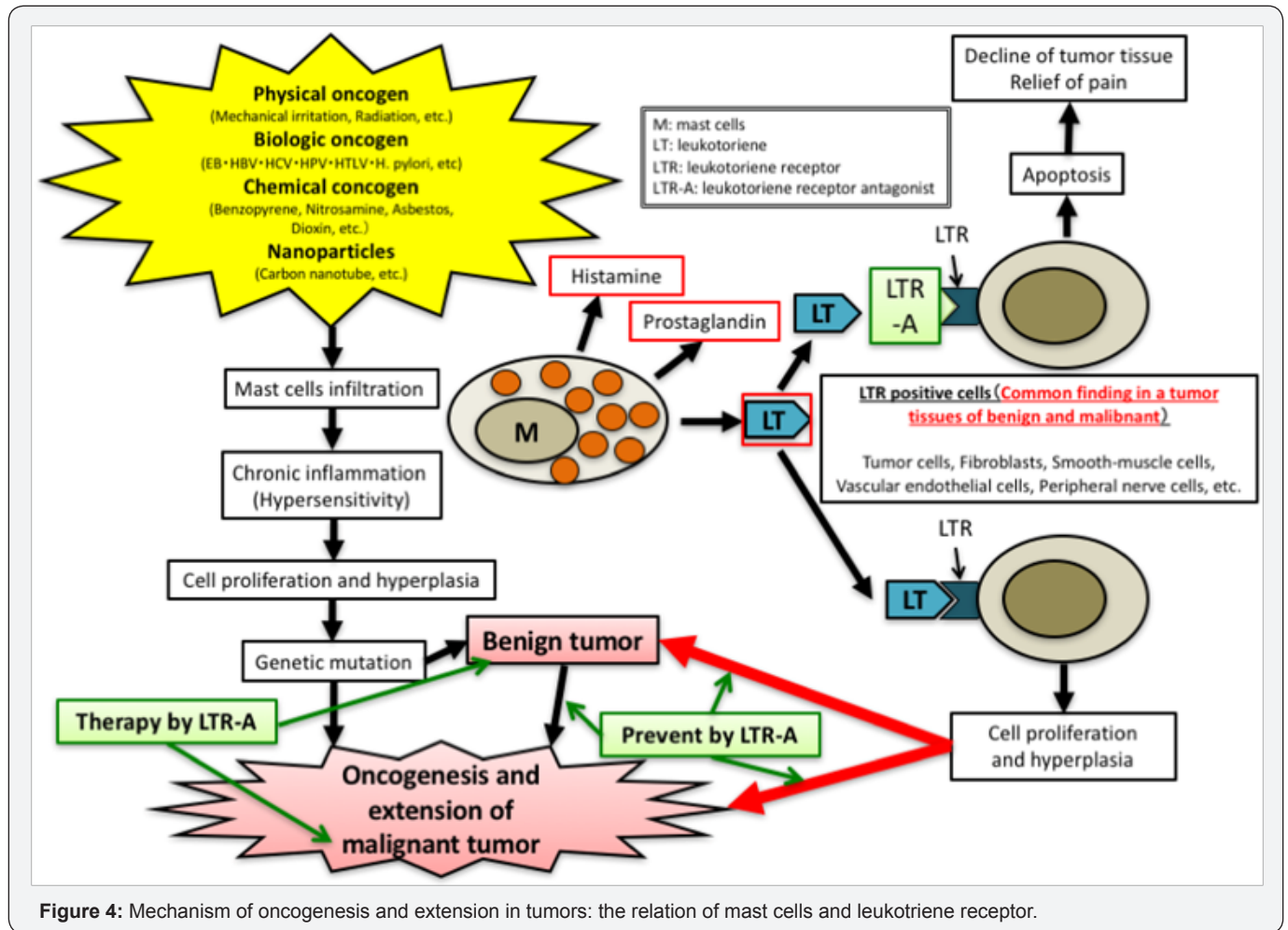


Figure 4: Mechanism of oncogenesis and extension in tumors: the relation of mast cells and leukotriene receptor.

The mechanism involved shows high similarity to that seen in the remodeling of asthma, and it is also found in endometriosis, as we have already reported [10]. Furthermore, the antagonist's effect in treating endometriosis is very high [11,12]. This shows that the mechanism of this response is the basis for the development and extension of various proliferative lesions. The LT receptor antagonist may become a therapeutic drug for many proliferative lesions, if LT receptor expression by the lesion tissue can be confirmed.

With respect to colorectal adenoma, there is thought to be a difference in the risk of malignant transformation between LG and HG adenomas. In the present study, a difference was found in the severity of mast cell infiltration (distribution) between

LG and HG adenomas. Furthermore, a tendency for a difference in the expression of LT receptors was found in the comparison between colorectal adenomas and colorectal cancer tissue (in a previous report). This shows the possibility that mast cells and LT receptors are involved in the transitional mechanisms from benign to malignant tumors. Further data accumulation is necessary to appreciate the details.

Based on the results of this study, chronic hypersensitivity inflammation through mast cells and LT receptors appears to have a strong influence on the malignant transformation of benign adenomas. An LT receptor antagonist may prevent malignant transformation, as well be useful as treatment for colorectal adenomas. There is as yet no drug that can prevent

malignant tumors. The subjects in whom this LT receptor antagonist could be used to as a drug to prevent malignant tumors are the following: patients with a high-risk gene with malignant tumor, who were diagnosed with a benign tumor on medical examination, and who were diagnosed as having a boundary region variant with benign and malignant parts on histopathology. Only early detection of malignant transformation through follow-up can be done, and these patients cannot escape from anxiety. However, aggressive preventive treatment is enabled if they can take an LT receptor antagonist, and they will be freed from anxiety.

Conclusion

We discovered mast cells infiltration and LT receptor expression as the evidence that was common to tissue of colonic polyps, and the severity of findings correlated with the grade of adenomas. Therefore, chronic hypersensitivity inflammation through mast cells and LT receptors appears to have serious effects the malignant transformation of benign adenomas.

References

1. Masao Sugamata, Ihara T, Miho Sugamata (2015) Mast cell infiltration and leukotriene receptor expression in various tumors: possible clinical application of common pathological findings concerned with tumor development. *J Cancer Therapy* 6: 606-612.
2. The Lancet (2010) Preventable cancer in USA. *Lancet* 375(9727): 1665.
3. Thun MJ, Henley SJ, Patrono C (2002) Nonsteroidal anti-inflammatory drugs as anticancer agents: mechanistic, pharmacologic, and clinical issues. *J Natl Cancer Inst* 94(4): 252-266.
4. Elwood PC, Gallagher AM, Duthie GG, Mur LAJ, Morgan G (2009) Aspirin, salicylates, and cancer. *Lancet* 373(9671): 1301-1309.
5. Cuzick J, Otto F, Baron JA, Brown PH, Burn J, et al. (2009) Aspirin and non-steroidal anti-inflammatory drugs for cancer prevention: an international consensus statement. *Lancet Oncol* 10(5): 501-507.
6. Patrignani P, Patrono C (2016) Aspirin and cancer. *J Am Coll Cardiol* 68(9): 967-976.
7. Savari S, Liu M, Zhang Y, Sime W, Sjölander A (2013) CysLT1R antagonists inhibit tumor growth in a xenograft model of colon cancer. *PLoS ONE* 8(9): e73466.
8. Ming Ju Tsai, Ping Hsun Wu, Chau Chyun Sheu, Ya Ling Hsu, Wei An Chang, et al. (2016) Cysteinyl leukotriene receptor antagonists decrease cancer risk in asthma patients. *Sci Rep* 6: 23979.
9. Pothwell PM, Wilson M, Elwin CE, Norrving B, Algra A, et al. (2010) Long-term effect of aspirin on colorectal cancer incidence and mortality: 20-year follow-up of five randomized trials. *Lancet* 376(9754): 1741-1750.
10. Sugamata M, Ihara T, Uchiide I (2005) Increase of activation mast cells in human endometriosis. *Am J Reprod Immunol* 53(3): 120-125.
11. Ihara T, Uchiide I, Sugamata M (2004) Light and electron microscopic evaluation of antileukotriene therapy for experimental rat endometriosis. *Fertil Steril* 81(1): 819-823.
12. Masao Sugamata, Tomomi Ihara, Ichiro Uchiide (2015) A new therapy for human endometriosis: the therapeutic value of leukotriene receptor antagonist for endometriosis. *Open J Obstet Gynecol* 5: 313-318.



This work is licensed under Creative Commons Attribution 4.0 License
DOI: [10.19080/CTOIJ.2017.07.555718](https://doi.org/10.19080/CTOIJ.2017.07.555718)

Your next submission with Juniper Publishers will reach you the below assets

- Quality Editorial service
- Swift Peer Review
- Reprints availability
- E-prints Service
- Manuscript Podcast for convenient understanding
- Global attainment for your research
- Manuscript accessibility in different formats
(Pdf, E-pub, Full Text, Audio)
- Unceasing customer service

Track the below URL for one-step submission
<https://juniperpublishers.com/online-submission.php>