



Is three-Dimensional CT based Conformal Radiotherapy Superior to Two-dimensional X ray-based Radiotherapy for Neoadjuvant Radiotherapy in Locally advanced Carcinoma Rectum?



Chandana Sanjee^{1*}, Prasanna Kumar², Mayur Mayank³, MS Beliappa⁴, B Krishnamoorthy Reddy⁵, Natraj Veera Raghavan⁶, Vinay Ural⁷, Vijay Bhaskar⁸ and Karthik Vittal⁹

¹Senior registrar, DNB (Radiation oncology) Apollo Hospitals, Bangalore

²Chief Medical physicists (Radiation oncology) Apollo Hospitals, Bangalore

³Associate consultant DMRT, MD, DNB (Radiation oncology) Apollo Hospitals, Bangalore

⁴Senior consultant DMRT, MD, DNB (Radiation oncology) Apollo Hospitals, Bangalore

⁵Senior consultant MD (Radiation oncology) Apollo Hospitals, Bangalore

⁶Senior consultant DNB (Radiation oncology) Apollo Hospitals, Bangalore

⁷Senior consultant DMRT, DNB (Radiation oncology) Apollo Hospitals, Bangalore

⁸Senior consultant MD (Radiation oncology) Apollo Hospitals, Bangalore

⁹Junior medical physicist (Radiation oncology) Apollo Hospitals, Bangalore

Submission: December 25, 2019; **Published:** January 24, 2020

***Correspondence Author:** Chandana Sanjee, Department of Radiation Oncology, Apollo Hospitals, No 1455, 25th main, BTM layout, 2nd stage, Bengaluru, Karnataka, India

Abstract

Aim: Estimate deficiency in target volume coverage when using conventional X ray-based planning using bony landmarks in carcinoma rectum.

Methods and Material: The study consists of 86 biopsy proven patients of carcinoma rectum. The planned area of treatment was demarcated as per 2D bony landmarks in AP and lateral portals were used following which a 3-field plan was created. This plan was projected on a CT scan in which gross tumour volume, clinical target volume and planning target volume were delineated as per RTOG guidelines, thus comparing 2 dimensional vs. 3 dimensional techniques of treatment. Geographic miss of the nodal target when using conventional technique was estimated in comparison to 3D volume planning on the CT scan.

Statistical analysis used: Data were statistically described in terms of mean \pm standard deviation, median, and range. Comparison between the study plans was done using Chi square test. $P < 0.05$ was considered statistically significant. All statistical calculations were done using computer programs SPSS (Statistical Package for the Social Science; SPSS Inc., Chicago, IL, USA) version 15 for Microsoft Windows.

Results: When the PTV was superimposed on digital reconstructed radiograph (DRR), 32 out of 86 patients had geographical miss at the superior border, hence missing to cover the internal iliac group of lymph nodes when conventional 2-dimensional techniques were used to delineate target volume. When 2D plan coverage was superimposed on 3D volume DRR, volume receiving 95% of dose was 93% in the 2D plan whereas the coverage of V95 was 98% (p value 0.01) in 3DCRT plan. The geographic miss of nodal target volume was 1.4cm superiorly. When this missed volume was included into the target and planned, PTV coverage was achieved and small bowel dose was within the planned constraint of $V40 < 30\%$.

Conclusion: CT based planning should be encouraged and in radiation departments where 2-dimensional treatment is practiced, a diagnostic CT scan should be recommended, and the radiation portals should be revised as per the findings of the scan.

Keywords: Two-dimensional radiotherapy vs. Three-dimensional radiotherapy; L5/S1 for Rectum Cancer; Radiotherapy in cancer rectum

Introduction

Rectal cancers are the second most common (28%) cancers in large intestine after proximal colon cancers (42%). Colorectal

carcinoma is the third most common cancer in men and the second in women in the world with a lifetime probability of 4.7-

5%. It has also been reported as the third leading cause of cancer death in men and women in the United States [1]. In India, the incidence rate for rectal cancer in men is 4.1 per 100000. Rectal cancer ranks 9th among men [2]. The most common complaints

presented by carcinoma rectum patients are altered bowel habits, bleeding per rectum, appetite and weight loss, constipation, pain while passing stools, mucous discharge, and pain abdomen. Assessment of the extent of the primary disease is evaluated using colonoscopy with biopsy, imaging such as CT or MRI pelvis. MRI pelvis is considered gold standard for staging of rectal carcinoma. Blood investigations such as complete blood count, liver function and tumor marker carcinoembryonic antigen (CEA) is often performed at the baseline.

The standard of care for locally advanced Stage II (T3-T4, N0, M0) and Stage III (T any, N+, M0) rectal carcinoma, based on the results of a randomized German rectal cancer trial, [3] is preoperative chemoradiation therapy, followed by total mesorectal excision (TME) and additional adjuvant chemotherapy-with the goal of achieving greater than 60% of 5-year disease-free survival. Neoadjuvant radiotherapy, R0 resection, nodal disease and concurrent chemotherapy are considered the most important prognostic factor for local control and 5-year survival [4]. Rectum is divided into upper(<6cm), mid(7-11cm) and lower rectum (>11cm) depending on the distance of the lower border from anal verge. Perirectal, presacral and internal iliac lymph nodes are considered regional lymph nodes of rectum, hence included into the radiation portal. Pelvic lymph nodes outside mesorectum-internal iliac, external iliac and obturator are termed as lateral pelvic lymph nodes. Dissection of these lymph nodes electively is still a matter of debate in locally advanced N0 disease. Involvement of pelvic lymph nodes other than internal iliac lymph nodes is considered as systemic metastases and requires chemotherapy. Japanese colorectal surgeons perform total mesorectal excision (TME) and lateral pelvic lymph node dissection upfront and American oncologists consider neoadjuvant radiotherapy and TME as treatment standard if pre-treatment imaging does not show metastatic internal iliac lymphadenopathy.

Lateral pelvic LN metastases are reported in 10–25% of advanced rectal cancers. Risk factors for lateral pelvic lymph node positivity are tumour diameter greater than 5 cm, advanced tumour infiltration, poor tumour differentiation, large number of regional LN metastases, and lower tumour location. The internal iliac and obturator regions are most considered as pelvic lateral LN metastases. Radiotherapy helps to increase local control and improve survival. Hence it is imperative to accurately delineate treatment volume. Two-dimensional radiotherapy uses bone landmarks in the Anterior-Posterior and Lateral ports to localize the treatment volume. Advances in imaging, radiotherapy techniques and computer applications have led us to evolve

into 3-dimensional conformal radiotherapy (3-DCRT). Wide fluctuation in pelvic anatomy like that of aortic bifurcation, altered sacral curvature, and varying course of pelvic vessels have further led us to realize 'Not everyone fits the mould', hence requiring customization.

In 3-DCRT a Computed tomography scan and multi leaf collimators are used to conform treatment volume. These newer techniques have reported decrease in normal tissue toxicity, along with decrease in the chances of geographic miss. Developing countries prefer to use conventional X-ray-based planning using the standard bony landmarks due to unavailability of newer technologies, lack of training to use CT based planning, high number of cases; ease of X-ray-based planning, less time consuming, and cost-effective as compared to three-dimensional CT-based planning. However, whether CT based planning is superior in terms of local control and survival is yet to be proven by randomized trials.

Subjects and Methods

A single institutional dosimetric observational study of 86 biopsy proven carcinoma rectum patients who received radiotherapy treatment at Apollo Hospitals, Bangalore. Patients of locally advanced rectal carcinoma without clinical or radiological evidence of external iliac or inguinal lymph nodes were included into the study. 2D planning was done as per Dutch rectal cancer trial Posterior field

Upper border: L5-S1

Lower border: 2cm margin from the lowest extent of the tumour

Lateral border: 2 cm from the widest part of the pelvic brim

Lateral field

Upper and lower: were the same as posterior field

Anterior border: Posterior to symphysis pubis except in T4 cases where anterior border extends to include whole symphysis pubis

Posterior border: cover the whole sacral curve

Planning was done using 10MV energy photons using the above portal borders a three-field plan was designed using 10 MV X-rays with apertures shaped to the 2D portal field borders. The fields consist of posterior, right, and left lateral beam with 2:1:1 weightage given to the radiation fields. Wedges were used in the lateral fields.

3-dimensional conformal radiotherapy(3DCRT)

Positioning and Immobilization

Patients were positioned supine with arms above the head and aligned with laser. Immobilization achieved using a thermoplastic

pelvic cast foot board. Bladder protocol (500ml of water to be consumed half hour before simulation and treatment) was followed in all cases. Treatment-planning computed tomography (CT) with IV contrast (IOPROMIDE) was performed 2mm slice thickness axial, saggital and coronal planes after reconstruction were obtained. The CT scans were obtained from the T10 vertebral body to mid-thigh. These simulation images were transferred in digital imaging and communication (DICOM) format to the Eclipse planning system (Varian Medical Systems) for delineation of target volumes and organs at risk.

Delineation of Target Volumes

Three targets were delineated in all the patients based on ICRU 50

The GTV comprised of all gross primary tumour sites and enlarged lymph nodes i.e. visible part of the tumor with macroscopically visible metastasis in lymph nodes obtained by

clinical, colonoscopy and imaging methods. CTV Node is contoured as per RTOG guidelines which have recommended the inclusion internal iliac, peri rectal and pre sacral lymph nodes. Elective nodal irradiation uses contrast enhanced vessels plus a 7mm margin to define the internal iliac nodal regions. The presacral region was included up to the bottom of the sacral vertebra to cover the presacral lymph nodes.

CTV Primary was contoured by adding a margin of 2 cm to the gross tumor superiorly or up to recto sigmoid (whichever is more cephalic), 2cm margin inferiorly following which entire mesorectum is covered with an anterior extension of 1cm into bladder/vagina/prostate considering bladder/rectum to account for bladder/rectum filling uncertainty. Then a PTV of 7-10mm can be considered to the combination of Nodal and primary CTV. Organs at risk which were contoured were femoral head, bowel bag and urinary bladder.

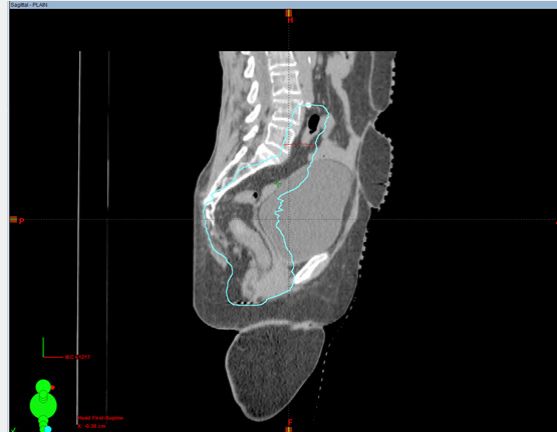

Figure 1: In this image black arrow shows the superior border (L5/S1) as per conventional X ray radiotherapy. White arrow shows the superior border as contoured on 3D image using the bifurcation of common iliac vessel as the superior extent.

Figure 1 In this image black arrow shows the superior border (L5/S1) as per conventional X ray radiotherapy. White arrow

shows the superior border as contoured on 3D image using the bifurcation of common iliac vessel as the superior extent.

Dose Prescription

Table 1: A dose of 50.4Gy Gy in 1.8 Gy per fraction was prescribed to the PTV.

Organ at risk (OAR)	Constraint
Small Bowel	V30Gy<40%
Bladder	V40Gy<45%
Femoral heads	V40Gy<5%

A dose of 50.4Gy Gy in 1.8 Gy per fraction was prescribed to the PTV (Table 1).

Treatment Planning

On Eclipse treatment planning system (Varian Medical Systems), 2D plans were generated. The plan generated for the

2D fields were superimposed on the DRR. The coverage of PTV as contoured on a CT scan was evaluated on a DVH. A separate 3DCRT plan was created to fulfil the above constraints.

Plan Evaluation and DVH Analysis

Each plan was evaluated both quantitatively and qualitatively. Quantitative evaluation involved an assessment of both PTV and normal tissue DVHs. Qualitative evaluation involved a slice-by-slice evaluation of the dose conformity and of all hot and cold spots. To ensure at least 95% PTV is covered by 100% of the prescription dose. No portion of PTV should get less than 95% of prescribed dose. To ensure underdose to any part of PTV shall not exceed 5% of prescription dose. To ensure overdose to any part of PTV shall not exceed 7% of prescription dose. Conforms to target volume and normal tissues are not excessively irradiated. PTV receives uniform dose. Doses to OARs do not exceed tolerance value.

Results

Data were statistically described in terms of mean ± standard deviation, median, and range. Comparison between the study

plans was done using Chi square test. $P < 0.05$ was considered statistically significant. All statistical calculations were done using computer programs SPSS (Statistical Package for the Social Science; SPSS Inc., Chicago, IL, USA) version 15 for Microsoft Windows. Totally 86 patients were analysed, of which 55 patients were males and 31 patients were females. 13 patients had NO status, 70 patients had perirectal and presacral lymphadenopathy and 20 patients had metastatic internal iliac lymph nodes. We found that 32 out of 86 cases had inadequate coverage of internal iliac lymph nodes when using standard bony landmarks. When 2D plan coverage was superimposed on 3D volume DRR, volume receiving 95% of dose was 93% in the 2D plan whereas the coverage of V95 was 98% in 3DCRT (p value >0.01). The geographic miss of nodal target volume was 1.4cm superiorly. When this volume was included into the target and planned the PTV coverage was achieved and small bowel dose was within the planned constraint of $V40 < 30\%$.

Gender

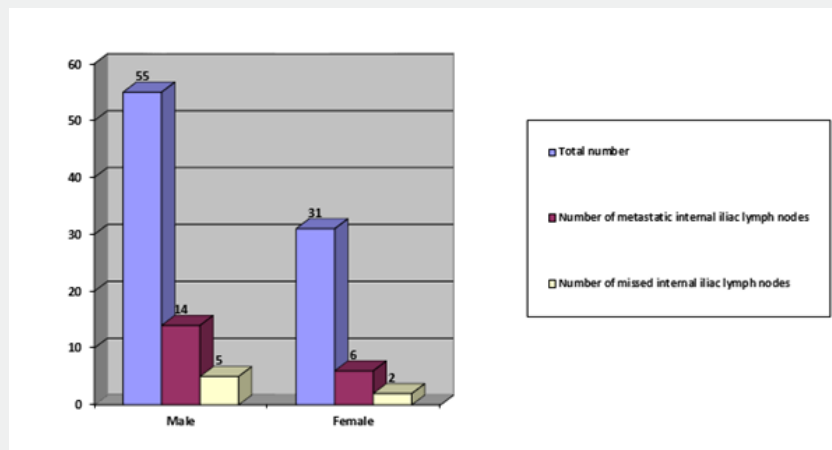


Figure 2: Chances of missing metastatic internal iliac lymph node in male and female population.

Lymphadenopathy

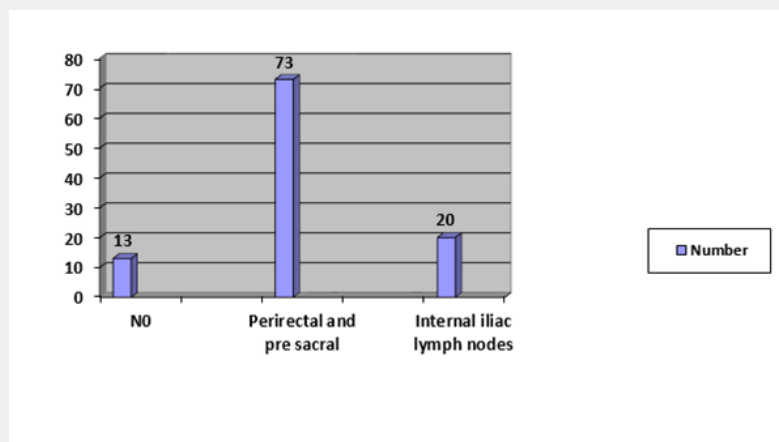


Figure 3: Lymph node status.

Location

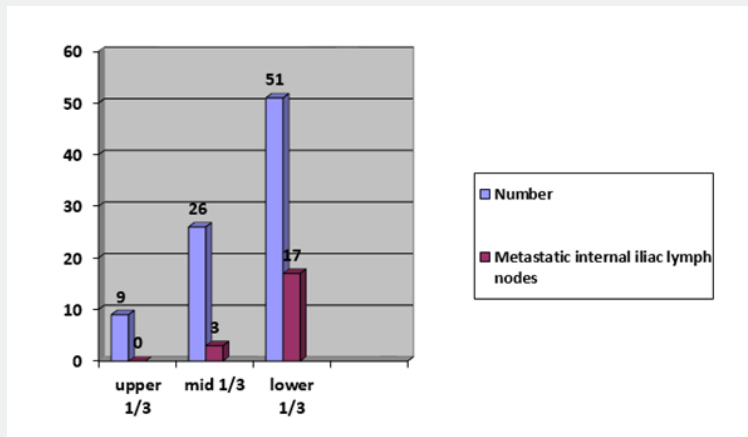


Figure 4: Location wise distribution of ca rectum.

Coverage of PTV

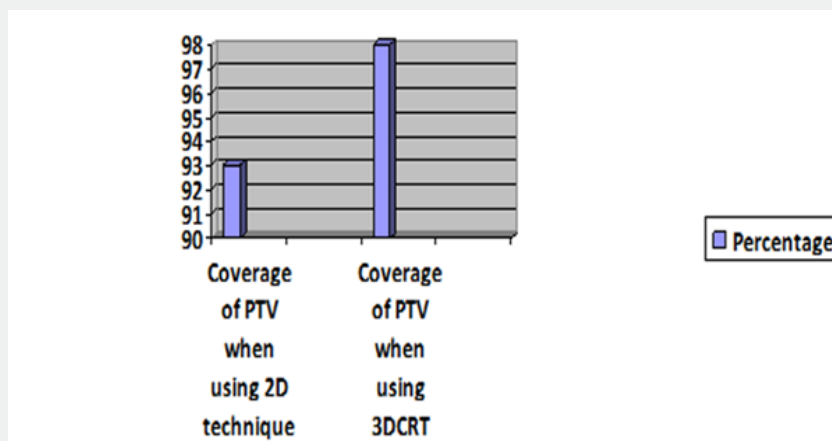


Figure 5: 2D coverage vs. 3D coverage (p value 0.01).

The coverage of actual PTV when a conventional bony landmark plan is evaluated on a CT scan versus PTV coverage when using CT image is used to plan radiotherapy.

Discussion

The treatment of rectal carcinoma has changed paradigm with the advent of total mesorectal excision and neoadjuvant radiotherapy. An analysis of 2916 cases of rectal cancer in the project study by the JSCCR showed that the lateral lymph node metastasis rate in patients who's lower tumor border was located distal to the peritoneal reflection and whose cancer invaded beyond the muscularis propria was 20.1% [5]. Colorectal surgeons generally have two schools of thought in locally advanced rectal carcinoma, Japanese colorectal surgeons believe lateral pelvic lymph nodes which include internal iliac and obturator lymph

nodes are regional lymph nodes. Lateral lymph node dissection is indicated when the lower border of the tumour is located distal to the peritoneal reflection and the tumour has invaded beyond the muscularis propria. After performing lateral lymph node dissection for the above-mentioned indication, it is expected that the risk of intrapelvic recurrence decreases by 50%, and the 5-year survival rate improves by 8-9%. Western surgeons do not use pelvic lymph node dissection regularly due to risk of injury to the autonomic nerves causing of sexual and urinary dysfunction. This might increase risk of local recurrence in the pelvic sidewall especially in patients operated on without preoperative RT. Thus, including the internal iliac and obturator lymph nodes in the radiation portal is important in locally advanced cases of rectal carcinoma to decrease locoregional recurrence in the pelvis.

In our study we had 55 male patients and 31 female patients. 13 patients had N0 status, 73 patients had perirectal and presacral lymphadenopathy, 20 patients had metastatic internal iliac lymph nodes and 4 patients had inferior mesenteric lymph nodes. We found that 32 out of 86 cases had inadequate coverage of internal iliac lymph nodes when using standard bony landmarks. Of the 32 patients who had inadequate internal iliac lymph node coverage 7 of them had metastatic internal iliac lymph nodes on imaging. When 2D plan coverage was superimposed on 3D volume DRR, volume receiving 95% of dose was 93% in the 2D plan whereas the coverage of V95 was 98% in 3DCRT. Randomized studies to prove the superiority of 3DCRT in terms of improved local control and overall survival are yet to be done.

Weir et al. [6] investigated if L5-S1 as the superior border is enough to cover internal iliac lymph nodes, 60 patients' CT scans were evaluated following which it was concluded that 66% of patients missed internal iliac lymph nodes. In this study 37% (n=32) of patients missed internal iliac lymph nodes if L5-S1 was considered as superior border in A-P and lateral portal. In the 32 patients, 7 (22%) of them had metastatic internal iliac lymph nodes. Likewise, in study of 50 cancer cervix cases showed that 48 cases had aortic bifurcation above L4-5 and had geographic miss of tumor when using conventional 4 field bony landmark based radiotherapy. It is now clear that the trend to describe treatment target volume in terms of bony landmarks lead to missing nodal volume in pelvic malignancies [7]. This is a dosimetric study which shows geographic miss of target volume in 32 patients, based on this study and on prior studies done we recommend

a CT based conformal treatment planning for all rectal cancer patients receiving radiation therapy. The effect of the same in improvement of recurrence free survival or overall survival is yet to be evaluated.

Acknowledgement

To the department of radiation oncology, Apollo hospitals, Bangalore.

References

1. Fazeli MS, Keramati MR (2015) Rectal cancer: a review. Med J Islam Repub Iran 29: 171.
2. Indian Council of Medical Research (2014) Consensus Document for management of Colorectal Cancer. India, P. 89.
3. Sauer R, Becker H, Hohenberger W, Claus Rödel, Christian Wittekind, et al. (2004) Preoperative versus postoperative chemoradiation therapy in rectal cancer. N Engl J Med 351: 1731-1740.
4. Li Y, Wang J, Ma X, et al. (2016) A Review of Neoadjuvant Chemoradiotherapy for Locally Advanced Rectal Cancer. Int J Biol Sc 12(8): 1022-1031.
5. Watanabe T, Itabashi M, Shimada Y, Tanaka S, Ito Y, et al. (2015) Japanese Society for Cancer of the Colon and Rectum (JSCCR) Guidelines 2014 for treatment of colorectal cancer. Int J Clin Oncol 20(2): 207-239.
6. RA Weir, AR Bhirud, NR Bennion, CA Enke, AO Wahl, et al. (2014) L5/S1 as the superior border of radiotherapy fields in rectal cancer misses internal iliac lymph nodes International Journal of Radiation Oncology Biology Physics.
7. Gulia A, Patel F, Rai B, Bansal A, Sharma SC (2013) Conventional four field radiotherapy versus computed tomography-based treatment planning in cancer cervix: A dosimetric study. South Asian J Cancer 2(3): 132-135.



This work is licensed under Creative Commons Attribution 4.0 License
DOI: [10.19080/CTOIJ.2020.15.555915](https://doi.org/10.19080/CTOIJ.2020.15.555915)

Your next submission with Juniper Publishers will reach you the below assets

- Quality Editorial service
- Swift Peer Review
- Reprints availability
- E-prints Service
- Manuscript Podcast for convenient understanding
- Global attainment for your research
- Manuscript accessibility in different formats
(Pdf, E-pub, Full Text, Audio)
- Unceasing customer service

Track the below URL for one-step submission

<https://juniperpublishers.com/online-submission.php>