



Case Report

Volume 25 Issue 3 - October 2023  
DOI: 10.19080/CTOIJ.2023.25.556162

Cancer Ther Oncol Int J

Copyright © All rights are reserved by Ana Sofia Gonzalez Izaguirre

# Nodular Anal Melanoma in HIV Positive Patient: Case Report



Ana Sofia Gonzalez Izaguirre<sup>1\*</sup>, Angel Padron Rivera<sup>1</sup>, Fernando Carballar Mejia<sup>1</sup>, Evelia Ana Florencia Ponce Horta<sup>2</sup>, Maria Fernanda Gonzalez Castillo<sup>1</sup> and Alondra Gabriela Mercado Mendiola<sup>1</sup>

<sup>1</sup>Department of Surgery at Hospital Regional Leon, ISSSTE, Leon, Mexico

<sup>2</sup>Department of Anesthesiology at Hospital Civil De Guadalajara Fray Antonio Alcalde, Guadalajara, Mexico

**Submission:** October 10, 2023; **Published:** October 26, 2023

**\*Corresponding author:** Ana Sofia Gonzalez Izaguirre, Department of Surgery at Hospital Regional Leon, ISSSTE, Leon, Mexico

## Abstract

Anorectal melanoma (AM) is a rare malignancy, characterized by aggressive behavior and a poor prognosis. AM is more frequent in patients aged over 50 years. There are many theories regarding AM pathogenesis. Some consider that AM may be related to oxidative stress in the region and to immunosuppression. Most frequently, the signs and symptoms are obstruction, rectal bleeding, pain, or rectal tenesmus. There is currently no consensus about the most appropriate systemic treatment.

**Keywords:** Anorectal melanoma; Immunotherapeutic strategies

## Introduction

Anorectal melanoma (AM) is a rare malignancy which is often difficult to diagnose due to the hidden site. This malignancy is characterized by aggressive behavior, and patients often have a very poor prognosis, which is related to the frequent delay in the diagnosis, as well as biological differences in malignant melanocytes of this anatomic area compared to other sites. Since AM accounts for only 1% of all anorectal malignant tumors [1]. The US National Cancer Database stated that mucosal melanoma represents the third most common site of primary melanomas after the skin and eye [2-4]. Melanin synthesis is the principal function of melanocytes, its role in mucosal areas is mainly characterized by antioxidant activity and contributing to the regional immune response, the malignant transformation in anorectal areas may be related to oxidative stress in these regions and to immunosuppression [5,6]. The main reasons that lead to a diagnosis of AM are the late and nonspecific signs and symptoms, which occur usually when tumoral masses are large (3-4 cm), and when the neoplasia involves the rectum, anus, or both. The most common clinical presentations of AM are changes in bowel habits, bowel obstruction, rectal bleeding, anal pain, and/or rectal tenesmus [7,8]. Emphasized to use endoscopic ultrasounds and magnetic resonance imaging (MRI), to supplement colonoscopy

in preoperative settings, allowing for the evaluation of the bowel wall in all five layers, assessing tumor infiltration, radial extension, and the total thickness of the neoplasia [5]. In the last few years, most of the commonly used international clinical guidelines around the globe have considered the standard of care two immunotherapeutic strategies: anti-PD1 single therapy (nivolumab or pembrolizumab) and the combination of anti-CTLA4 and anti-PD1 (ipilimumab plus nivolumab) [9,10].

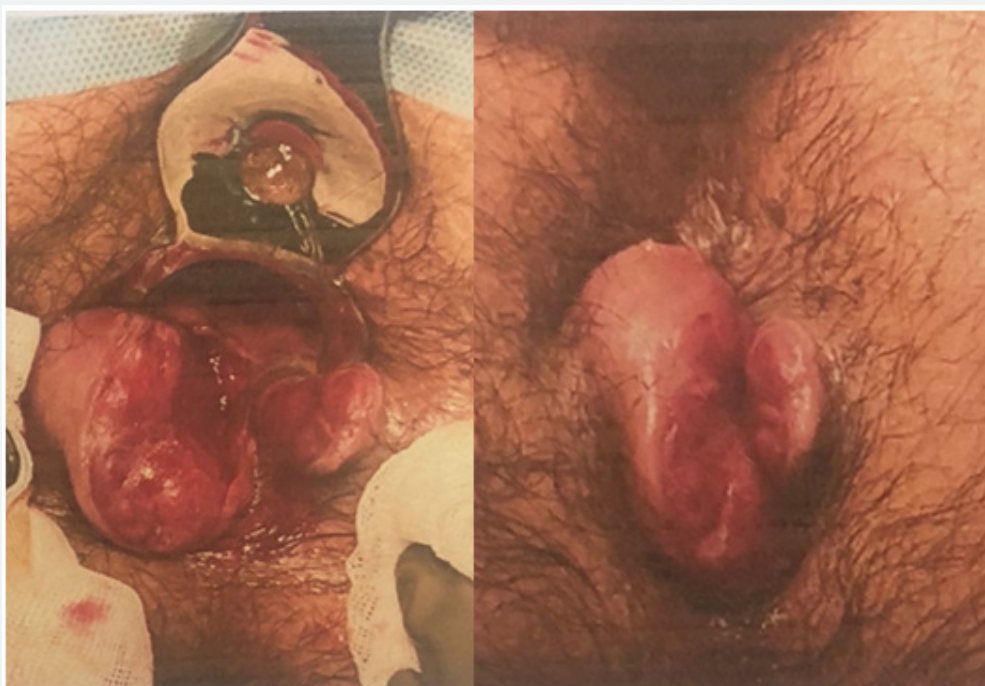## Case Report

This is a 37-year-old male patient with HIV positive serology for 1 year of diagnosis under treatment with the BIKTARVY antiretroviral regimen (bictegravir, emtricitabine, tenofovir alafenamide) as well as polycystic kidney disease for 9 years of diagnosis under treatment with spironolactone and alphacetoanalogues. without hereditary family history of importance for the condition. His condition began with the release of hyaline, fetid transrectal exudate accompanied by perianal pain, rapidly evolving volume increase and progressive rectal bleeding, which is why he went to a doctor who found a productive anterior anal ulcer with purulent fluid, which is why he initially concluded with anal ulcer associated with

STD (sexually transmitted disease) and started treatment with ceftriaxone, azithromycin, acyclovir and metronidazole, without specifying dose, reported partial improvement. In October 2022, he presented a sudden increase in perianal volume, which is why he went to the emergency department where drainage of the perianal abscess was performed. Due to the progressive increase in volume at the perianal level despite the treatment, laboratory studies and viral panel were requested, reporting positive anti-HIV antibodies and the patient was referred to the coloproctology service where an anal fistula was found with an adjacent increase in volume, upon palpation it was found. He perceived an indurated lesion with purulent material coming out, and little bleeding, so he was scheduled for a biopsy.

Physical examination revealed an exophytic tumor at the perianal skin level, predominantly right lateral, ulcerating skin of 6x4 cm, infiltrating the anal canal, without adenopathies at

the inguinal level (Figure 1). A biopsy of the anal and rectal tumor was performed, which reported a neoplastic lesion below the lining epithelium, confirmed by a proliferation of medium-sized ovoid cells, showing central ovoid nuclei, with regular contours, moderate pleomorphism with open chromatin and very evident eosinophilic nucleoli. Scanty, eosinophilic cytoplasm, arranged in a solid, infiltrative histologic pattern. Numerous atypical mitoses with immunohistochemistry: HMB45: positive in malignant neoplastic cells; PS100: positive in malignant neoplastic cells; HHV-8: negative; CD34. Cytokeratins AE3/AE6, CK5/6, P40, Chromogranin and CD45: negative, with definitive histopathological diagnosis: by morphology and with support of immunohistochemical markers compatible with nodular melanoma. To stage the melanoma, a PET/CT study was requested which reported a hypermetabolic anal lesion highly suggestive of tumor activity, pelvic adenopathies, bone and lung lesions probably as secondary deposits (Figure 2).



**Figure 1:** Physical examination revealed an exophytic tumor at the perianal skin level, predominantly right lateral, ulcerating skin of 6x4 cm, infiltrating the anal canal, without adenopathies at the inguinal level.

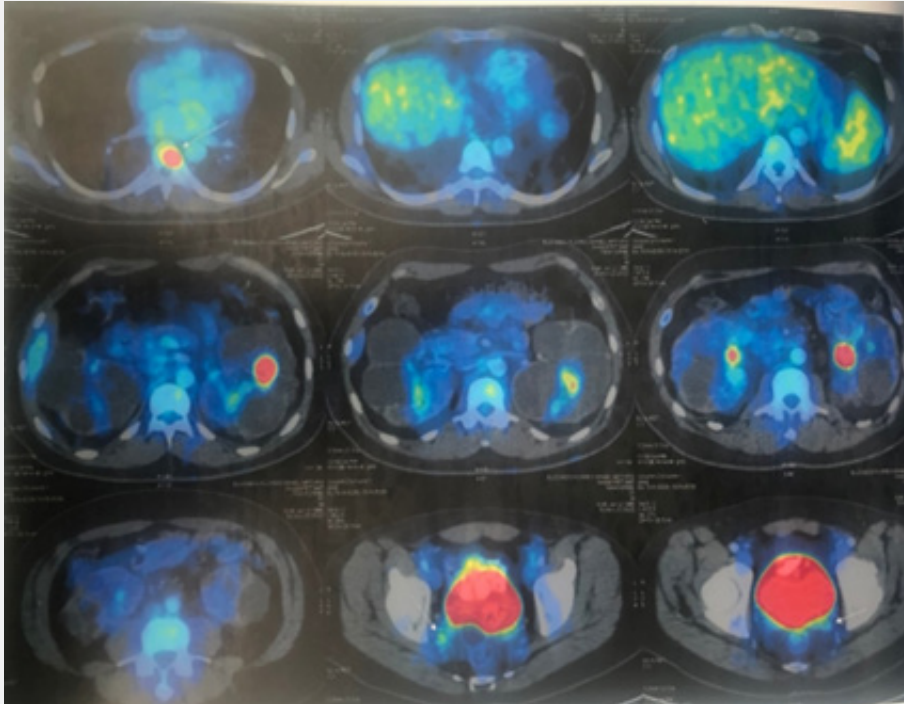
The medical oncology department started systemic therapy with nivolumab 285 mg every 21 days and ipilimumab 95 mg every 21 days (4 cycles). Due to histology and location of the tumor, he is not a candidate for radiotherapy or surgical management initially. Currently the patient continues with conservative treatment with immunotherapy with favorable results at 3 months, with significant reduction of the tumor and absence of bleeding (Figure 3).

### Discussion

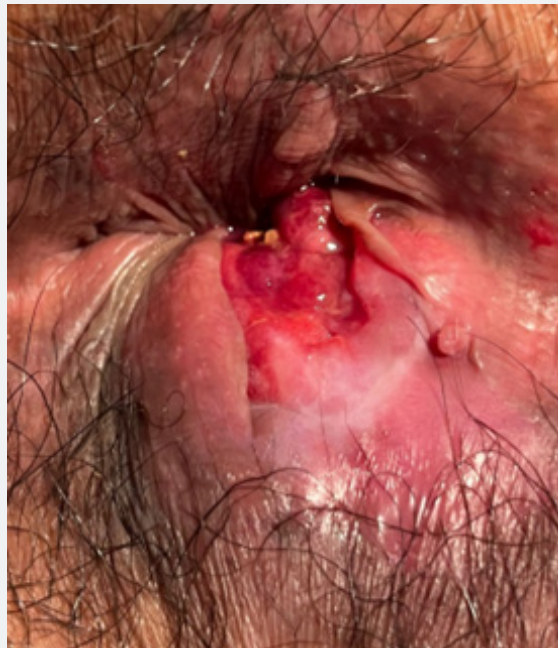In the review of this case we noted that since this is a young patient who is outside the statistics described in the literature, he presents with a melanoma of advanced evolution and timely primary treatment is delayed due to confusion with differential diagnoses and other treatments, however, he responded favorably to conservative treatment; We currently have immunotherapies

such as the combination of the monoclonal antibodies Nivolumab and Ipilimumab, recently approved for the treatment of metastatic

melanoma in stages III or IV, which have been shown to improve symptoms and increase survival considerably.



**Figure 2:** PET/CT study was requested which reported a hypermetabolic anal lesion highly suggestive of tumor activity, pelvic adenopathies, bone and lung lesions probably as secondary deposits.



**Figure 3:** The conservative treatment with immunotherapy with favorable results at 3 months, with significant reduction of the tumor and absence of bleeding.

It is of vital importance that first contact physicians, despite the low incidence and prevalence, can recognize or suspect the diagnosis of melanoma through a directed anamnesis and a complete physical examination in any patient presenting with lesions in the anorectal region and other compatible symptoms to make an early diagnosis and provide timely treatment.

## Conclusion

The role of medical therapy in the treatment of anorectal melanomas is another topic of debate. There is little data to suggest its efficacy; however, as more is discovered about the pathophysiology of the malignancy, targeted therapies are an effective option. By far the most widely used chemotherapy is with dacarbazine. Immunotherapy modalities such as IL-2 and ipilimumab have shown efficacy in some patients with unresectable diseases.

## Conflicts of Interests

The authors declare no conflict of interest.

## Acknowledgement

Ana Sofia Gonzalez Izaguirre

Fernando Carballar Mejia

Angel Padron Rivera

## References

- Schaefer T, Satzger I, Gutzmer R (2017) Clinics, prognosis and new therapeutic options in patients with mucosal melanoma. A retrospective analysis of 75 patients. *Medicine* 96(1): e5753.
- Parra RS, Almeida AL, Badiale BG, Moraes MM, Rocha JJ, et al. (2010) Melanoma of the anal canal. *Clinics (Sao Paulo)* 65(10): 1063–1065.
- Micu E, Juzeniene A, Moan J (2011) Comparison of the time and latitude trends of melanoma incidence in anorectal region and perianal skin with those of cutaneous malignant melanoma in Norway. *J Eur Acad Dermatol Venereol* 25(12): 1444–1449.
- Cagir B, Whiteford MH, Topham A, Rakinic J, Fry RD (1999) Changing epidemiology of anorectal melanoma. *Dis Colon Rectum* 42(9): 1203–1208.
- Jensen C, Kin C (2017) Black is the new black: Prolapsing primary anorectal melanoma. *Dig Dis Sci* 62(11): 2991–2993.
- Zecca L, Zucca FA, Wilms H, Sulzer D (2003) Neuromelanin of the substantia nigra: A neuronal black hole with protective and toxic characteristics. *Trends Neurosci* 26(11): 578–580.
- McBrearty A, Porter D, McCallion K (2015) Anal melanoma: A general surgical experience. *J Clin Case Rep* 5: 493.
- Van Schaik P, Ernst M, Meijer H, Bosscha K (2008) Melanoma of the rectum: A rare entity. *World J Gastroenterol* 14(10): 1633–1635.
- Tawbi HA, Schadendorf D, Lipson EJ, Ascierto PA, Matamala L, et al. (2022) Relatlimab and nivolumab versus nivolumab in untreated advanced melanoma. *N Engl J Med* 386(1): 24–34.
- Robert C, Long GV, Brady B, Dutriaux C, Maio M, et al. (2015) Nivolumab in previously untreated melanoma without BRAF mutation. *N Engl J Med* 372(4): 320–330.



This work is licensed under Creative Commons Attribution 4.0 License  
DOI: [10.19080/CTOIJ.2023.25.556162](https://doi.org/10.19080/CTOIJ.2023.25.556162)

### Your next submission with Juniper Publishers will reach you the below assets

- Quality Editorial service
- Swift Peer Review
- Reprints availability
- E-prints Service
- Manuscript Podcast for convenient understanding
- Global attainment for your research
- Manuscript accessibility in different formats  
( Pdf, E-pub, Full Text, Audio)
- Unceasing customer service

Track the below URL for one-step submission

<https://juniperpublishers.com/online-submission.php>