

# Adenoid Cystic Carcinoma of the External Auditory Canal Rare Case Report

**Faisal Dibsi\***

*Department of Otolaryngology-Head and Neck Surgery, AL AHAHBA Private University, Aleppo City, Syria*

**Submission:** July 6, 2016; **Published:** July 14, 2016

**\*Corresponding author:** Faisal Dibsi, Department of Otolaryngology-Head and Neck Surgery, AL-KALIMAT HOSPITAL, Al-Sabil Area, Rezq-Allah Tahan Street, P.O.Box: 862, Aleppo city - Syria, Tel: 00963 21 2645909/00963944 488980; Email: [prof.dr.faisal.dibsi@gmail.com](mailto:prof.dr.faisal.dibsi@gmail.com)

## Abstract

Adenoid cystic carcinoma (ACC) of the external auditory canal (EAC) is extremely rare tumor. A wide excisional biopsy should be performed. Its propensity for Perineural invasion and slow growing, but highly invasive cancer with a high local recurrence rate. Lymphatic spread to the local lymph nodes is rare. It is not uncommon for distant metastasis, mainly to the lungs, to occur over the course of many years. Aggressive surgical resection with adjuvant radiotherapy is the standard treatment for local disease control.

A 45 year old male (M.M.) applied 06.04.1999 with a tumor in the left external auditory canal. The pathology of wide excisional biopsy was adenoid cystic carcinoma. The patient refused having a surgery. He had decided to go only for irradiation, which helped to stop the growth of the tumor for years. In 05.02.2008 he applied with progressive growth of tumor, extending and diffusing, with bloody pus discharge from the meatus and peripheral left facial palsy. The CT scan showed an involvement of the mandible. Otoscopy with photography showed the middle & lateral wall of Inner ear involvement. The patient died after several months.

**Keywords:** Adenoid cystic carcinoma; Malignant tumors of the external auditory canal; Head and neck neoplasms; Salivary neoplasm; Cylindroma

## Introduction

Primary malignancies of the external auditory canal (EAC) are extremely rare with more than 80% being squamous cell carcinomas and adenoid cystic carcinoma (ACC) accounting for approximately 5% [1,2] Adenoid cystic carcinoma (ACC) is a rare epithelial tumor entity and comprises about 1% of all malignant tumours of the oral and maxillofacial region [3]. (ACC) first described as "Cylindroma" by Billroth [4], is commonly classified with the salivary gland tumors. (ACC) of the head and neck is usually found in the salivary glands, oral cavity, palate, nasal cavity, and nasopharynx [2].

Since 1894, there have been only 106 cases of (ACC) involving the (EAC) reported the English literature [2]. Although it presents a widespread age distribution, peak incidence occurs predominantly among women, between the 5<sup>th</sup> and 6<sup>th</sup> decades of life [5]. It is a slow growing but highly invasive cancer with a high recurrence rate. Lymphatic spread to the local lymph nodes is rare too. It is not uncommon for distant metastasis, mainly to the lungs, to occur over the course of many years [6]. The natural history of (ACC) of the (EAC) is characterized by an indolent clinical course, which usually leads to a late diagnosis [2].

Earlier diagnosis of these tumours is of utmost importance, in view of the fact that delays in diagnosis may increase the risk of distant metastasis [6]. The long natural history of this tumor, its propensity for Perineural invasion, and its tendency for local recurrence are well known [7]. The treatment goal includes complete surgical extirpation and a clear margin because of the high risk of repeat local recurrence. Aggressive surgical resection with adjuvant radiotherapy is the standard treatment for local disease control [6-8]. Because of the rarity of (ACC) of the (EAC), most of the observations drawn from various reports lack detailed comparisons of pathological findings and long-term outcome follow-up [2].

We present our own case along with a review and discussion of the literature to date.

## Classifications of the epithelial tumors of the external auditory canal

### Benign

- Ceruminous Adenoma (Ceruminoma)
- Pleomorphic adenoma (Mixed Tumor)
- Syringocystadenoma papilliferum

- Cylindroma

**Malignant**

- Adenoid Cystic Carcinoma
- Mucoepidermoid Carcinoma
- Adenocarcinoma

**Case Report**

**Early consultations**

During my practice Otolaryngology-Head & Neck Surgery since 1966 until present time, I meet only this case.

In 06.04.1999 male patient M.M. 45 year old applied with a tumor in the left external auditory meatus (Figure 1). He used to work as an employee in the agricultural bank in the countryside of Aleppo city-Syria. He had presented himself at my private clinic while taking an excision biopsy. The pathology was Adenoid Cystic Carcinoma (Figure 2). The patient refused having a surgery when he knew that growth of tumor is very slow and takes many years. He had decided to go only for the irradiation, which helped to stop the growth of the tumor for a few years (Figure 3).

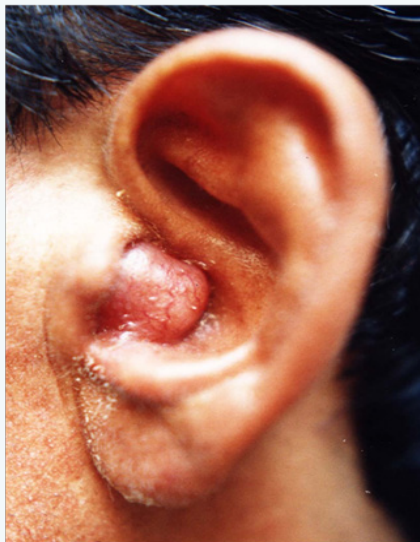

Figure 1: M.M. 45 year old (06.04.1999).

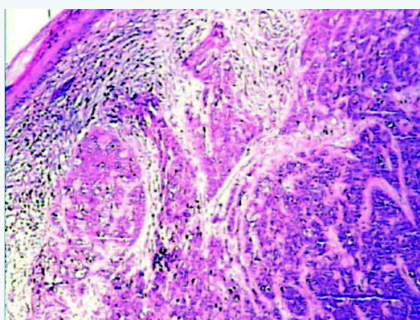


Figure 2: Micrographic Pathology (ACC).

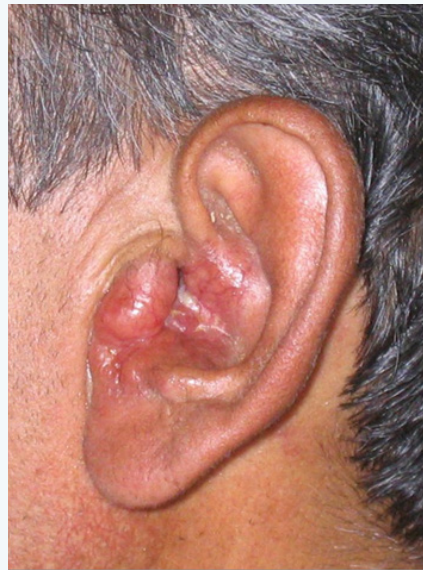

Figure 3: After irradiation.

**Clinical follow-up and progress**

Patient used to visit clinic from time to time for flew up. He suffered from ear bloody pus discharge and hearing loss. In 05.02.2008 he applied with a progressive growth in the pinna, behind the pinna and tragus. He kept refusing the surgery and used a herbal therapy. With a diffuse tumor that extended from the entrance to the external auditory meatus in his left ear: These tumors had also extended into front and behind of the pinna with a bloody pus discharge from the meatus and peripheral left facial palsy (Figure 4). The CT scan showed an involvement of the mandible (Figure 5), and erases the temporal bone (Figure 6). Otoscopy and photography showed the middle & lateral wall of Inner ear involvement (Figure 7). No lymphatic spread to the local lymph nodes or to lungs found. The patient died after several months.

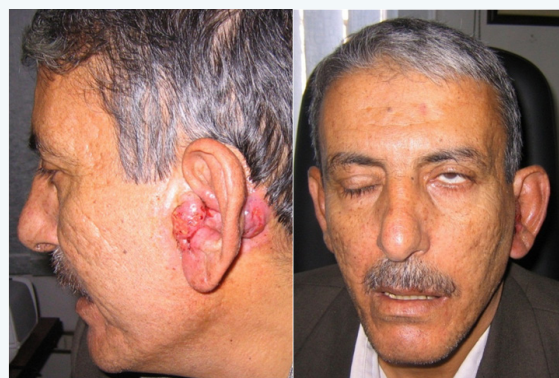

Figure 4: M.M. 54 year old (05.02.2008).  
(Extended Tumor and Involves the Left Facial Nerve)



Figure 5: 3DCT scan showed an involvement of the mandible.

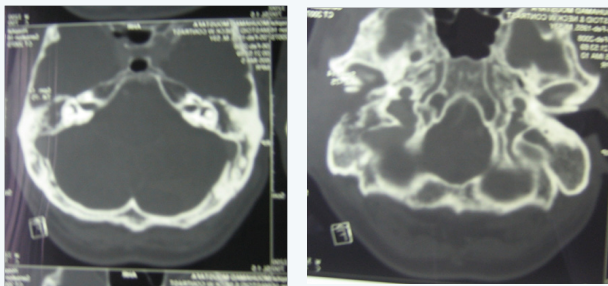


Figure 6: 3DCT scan. Eroses of temporal bone (04.03.2008).

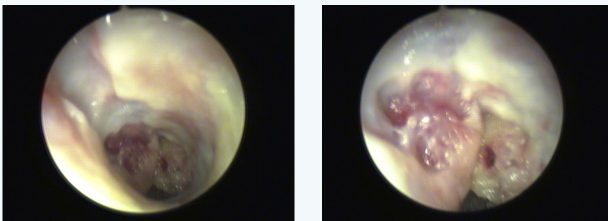


Figure 7: Otoscopy and photography showed the middle & lateral wall of Inner ear involvement and erases.

### Conclusion

Adenoid Cystic Carcinoma of the External Auditory Canal is:

- Very rare Malignant Tumor.

- Morphologically Similar to Salivary Gland Tumors.
- Have a propensity for perineural growth.
- This tendency accounts for most cases of Intracranial Involvement
- As the neoplasm grows along the nerves and by direct extension involves the central nervous system.
- Grows slowly, so patients can live with the tumor for a long time.
- Diagnosis is frequently missed because of the superficial nature of biopsies.
- A wide excisional Biopsy should be performed in every external auditory canal lesion.
- It is necessary to do both Aggressive Surgery (Complete surgical resection with clear surgical margins) & Postoperative Irradiation.

### References

1. Safinaz Zainor, Hamidah Mamat, Sakina Mohd. Saad, Mohd. Razif Mohamad Yunus (2013) Adenoid cystic carcinoma of external auditor canal: A case Report. *Egyptian Journal of Ear, Nose, Throat and Allied Sciences* 14(1): 41-44.
2. Shao-Cheng Liua, Bor-Hwang Kanga, Shin Niehb, Junn-Liang Changc, Chih- Hung Wangd (2012) Adenoid cystic carcinoma of the external auditory canal. *Journal of the Chinese Medical Association* 75(6): 296-300.
3. Kokemueller H, Eckardt A, Brachvogel P, Hausamen JE (2004) Adenoid cystic Carcinoma of the head and neck - a 20 years' experience. *Int J Oral Maxillofac Surg* 33(1): 25-31.
4. Billroth T (1859) Beobachtungen Uber Geschwulste der Speicheldrusen. *Archiv für pathologische Anatomie und Physiologie und für klinische Medicin* 17(5): 357-375.
5. Waldron CA, el-Mofty SK, Gnepp DR (1988) Tumours of the intraoral minor Salivary glands: a demographic and histologic study of 426 cases. *Oral Surg Oral Med Oral Pathol* 66(3): 323-333.
6. Dong F, Gidley PW, Ho T, Luna MA, Ginsberg LE, et al. (2008) Adenoid cystic Carcinoma of the external auditory canal. *Laryngoscope* 118(9): 1591-1596.
7. Spiro RH (1986) Salivary neoplasms: overview of a 35 year experience with 2807 Patients. *Head Neck Surg* 8(3): 177-184.
8. Bhagat S, Varshney S, Bist SS, Mishra S, Aggarwal V (2012) Case Report: Adenoid Cystic Carcinoma of External Auditory Canal. *Online J Health Allied Scs* 11(1): 19.