

Ingested Marble Impacted in Unusual Site (Nasopharynx)

Ahmed Ezzat*

Assiut university hospital, Egypt

Submission: September 10, 2016; **Published:** October 03, 2016

***Corresponding author:** Ahmed Ezzat, Ear Nose Throat, Head & neck surgery department, Assiut university hospital, Egypt

Abstract

Cases of foreign body ingestion are common among children. But impaction of ingested foreign body in nasopharynx is extremely rare. We present a male patient 4 months old with ingestion of foreign body (marble) impacted in the nasopharynx. The patient came after suspicion of his mother that he ingested marble ball but the patient had no symptoms, the patient diagnosed by X-ray head, neck and chest, the was removed immediately under general anaesthesia using finger and magill forceps.

Keywords: Foreign Body Ingestion; Nasopharynx; X-ray Head and Neck; Marble

Introduction

Foreign body ingestion especially in children is a very common case that presents daily in Ear Nose and Throat departments worldwide. Foreign body ingestion can occur in any age group but more common in children as they have more tendencies to explore objects and usually they play during ingestion [1]. Most of the ingested foreign bodies pass downward either to esophagus or to trachea [2,3]. Foreign bodies may impact in certain sites. One of the most common sites is crico-esophageal junction [2,4]. It is extremely rare to find ingested foreign body impacted in the nasopharynx [2,5]. Impaction of foreign body in nasopharynx is dangerous and may be fatal as it can easily be dropped, inhaled and cause sudden airway obstruction [6]. Swallowed foreign bodies may impact in nasopharynx although this is against gravity, some authors attribute that due to forceful cough or vomiting or due to penetrating trauma [2,7]. We present this case of swallowed foreign body impacted in the nasopharynx which is extremely rare site of impaction of ingested foreign bodies.

Case Presentation

4 months old male child arrived to our department with history of foreign body swallow (marble) 6 hours ago, on his mother's words he was laying down in his bed holding a marble in his hand and suddenly he had attack of cough she hurried up to her child and she didn't find the marble ball and she suspected that he had swallowed it. she brought him directly to our department, on examination of the patient he was calm no dyspnea, stridor or drooling of saliva. oral examination was free

and nasal examination was free, X-ray head, neck and chest post anterior view and lateral view was requested. X-ray head, neck and chest lateral view shows a radio-opaque spherical foreign body impacted in the nasopharynx (Figure 1).

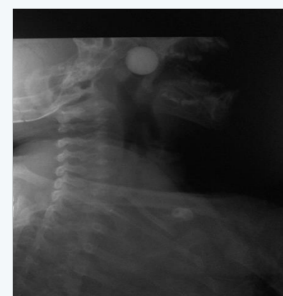

Figure 1: X-ray head, neck and chest lateral view shows radio-opaque spherical foreign body in nasopharynx.




Figure 2: Extracted marble from the nasopharynx with diameter more than 1.5 cm.

Urgently the patient was carried to operation room and the foreign body was removed under general anesthesia. Boyel Davis mouth gage was applied and pack applied in hypopharynx around the endotracheal tube to prevent swallow or inhalation of the foreign body during extraction. The foreign body was removed by finger from the nasopharynx to the throat and then picked up by magill forceps (Figure 2).

Results

Impaction of ingested foreign body in nasopharynx is rare but it should be kept in mind in all the case of foreign body ingestion especially when the foreign body not found in chest and abdominal x-ray. Urgent intervention is must to avoid drop of the foreign body in tracheal causing fatal complications.

Discussion

Nasopharynx is extremely rare site for foreign body impaction, in chevalier Jackson's study which includes 2000 patients who had aero digestive foreign bodies, Only 2 patients have foreign body impacted in nasopharynx [8,9]. Most of foreign bodies in aero digestive track take pathway downward to either esophagus or trachea. Upward movement of ingested foreign bodies is prevented by strong nasopharyngeal isthmus and by effect of gravity [8]. But in few cases foreign bodies move upward to nasopharynx. Authors attribute this due to forceful cough or vomiting or direct trauma [2,10]. In our case the patient has history of cough upon ingestion of marble which may be the cause of abnormal passage of the foreign body to the nasopharynx. There are documented cases of coin, metallic hair clips, marble, fish and rubber beads were found in the nasopharynx [2,5,7,10-12].

All of these foreign bodies are dangerous as they can easily be dropped and being inhaled causing sudden airway obstruction and death. Marbles are more dangerous as they have smooth surface and can be dropped easier. Foreign bodies in nasopharynx may be presented by difficulty of breathing, dyspnea and nasal discharge but may also be asymptomatic as our patient [2,7]. X-ray head, neck, chest and abdomen are mandatory to located ingested foreign bodies. Nasopharynx shouldn't be missed in cases of foreign body ingestion especially when chest and

abdominal X- rays are free. Urgent intervention is mandatory in these cases and extraction under general anesthesia is more safe, application of pack in hypopharynx around endotracheal tube to prevent inhalation or swallowing of foreign body upon removal may be helpful.

Conclusion

Nasopharynx is not a common site for foreign body impaction after ingestion but it should be kept in mind in cases of foreign body ingestion. X-ray head neck and chest should be a routine investigation in cases of foreign body ingestion.

References

1. McGuirt WF, Holmes KD, Feehs R, Browne JD (1988) Tracheobronchial foreign bodies. *Laryngoscope* 98(6 Pt 1): 615-618.
2. Kashyap SK (2016) Foreign Body (Coin) in the Nasopharynx of a child and its Management. *Glob J Otolaryngol* 1(5): 1-2.
3. Jagdish Kumar Athmaram Gupta Sunkum (2011) Nasopharyngeal Foreign Body in an Young Child. *Indian J Otolaryngol Head Neck Surg* 63(3): 285-286.
4. Muhammad Asif TH, Zakir Khan, Raza Muhammad, Sohail Malik, Farida Khan (2013) Foreign Body Esophagus: Types and Site of Impaction. *Gomal Journal of Medical Sciences* 11(2): 163-165.
5. Satheesh Kumar Bhandary, Biniyam Kolathingal, Vadisha Srinivas Bhat, Balakrishna Padubidri Srinivas (2011) Common foreign body, unusual site. *Otolaryngol Head Neck Surg* 145(6): 1060-1061.
6. Jagdish Kumar Athmaram Gupta Sunkum (2011) Nasopharyngeal Foreign Body in an Young Child. *Indian J Otolaryngol Head Neck Surg* 63(3): 285-286.
7. Sanjeev Gupta, Surya Kanta Pradhan (2015) Unexpected Nasopharyngeal Foreign Body. *Online J Otolaryngol* 5(2): 136-166.
8. Rakesh Kumar SV, Sampan Bist (2008) A Rare Nasopharyngeal Foreign Body. *Online Journal of Health and Allied Sciences*.
9. Briggs RD, Pou AM, Friedman NR (2001) An unusual catch in the nasopharynx. *Am J Otolaryngol* 22(5): 354-357.
10. Gupta M (2014) Endoscopic removal of an unusual foreign body from nasopharynx.
11. Mudunuri RKR, Gannavarapu DP, Mukkamala ANM, K M J (2015) Unusual Foreign Body in Nose and Nasopharynx - A Rare Case. *Journal of Clinical and Diagnostic Research: JCDR* 9(4): MD01-MD2.
12. Oysu C, Yilmaz HB, Sahin AA, Külekçi M (2003) Marble impaction in the nasopharynx following oral ingestion. *Eur Arch Otorhinolaryngol* 260(9): 522-523.

Your next submission with JuniperPublishers
will reach you the below assets

- Quality Editorial service
- Swift Peer Review
- Reprints availability
- E-prints Service
- Manuscript Podcast for convenient understanding
- Global attainment for your research
- Manuscript accessibility in different formats
(Pdf, E-pub, Full Text, Audio)
- Unceasing customer service
- Track the below URL for one-step submission

<http://juniperpublishers.com/online-submission.php>