

Get Rid of Snoring



Novak Vukoje¹ and Jon Garito^{2*}

¹ENT office “dr Vukoje”, Petrovaradin, Serbia

²PhD, Inventer the dual Frequency device and the RF electrodes, USA

Submission: September 11, 2017; **Published:** September 19, 2017

***Corresponding author:** Jon Garito, PhD, Inventer the dual Frequency device and the RF electrodes, 1111 Crandon, BLVD, FL 33149, USA, Tel: 516 375 7204; Email: drjgarito@aol.com

Abstract

For more than three decades, Dr. Vukoje was working on the issues of snoring and night choking. He is an author of many books that deal with these problems. One named Snore and how to get rid of it and the other *Snore and night choking - problems and solutions, Cut for silent night, Snoring and sleep apnea* etc. In the former Yugoslavia, he was the first one to operate on a patient suffering from notorious night snoring and performed more than a thousand surgical interventions on loud sleepers. Dr Vukoje is an author of an innovative technique for the solution of uvulo-palatinal obstruction. He is convinced that the future does not belong to surgical interventions, although in present development of medical science, they stay on top. Dr Vukoje is employed in ENT office “dr Vukoje” in Petrovaradin, Serbia.

Keywords: Causes of Snoring’s urgical procedures; CPAP; Ellman Sugitron

Introduction

Do you snore? If an answer is positive, you should know that you are not alone. More than two billion people around the world suffer from this problem. Just imagine how noisy our planet is during the night. If there is one syndrome that can be described as “fascinating” it should be snoring. During his loud sleep, composer Johan Brahms imitated the music of the complete orchestra. Snoring is proclaimed the second unpleasant noise produced by a human organism. This problem is old as the sleep itself, it is out of control of our will, and we cannot establish control over it [1]. When the obstruction of upper airway parts appears, the primary factor of snoring arises from the defect in the airway, from the nose up to the trachea [2]. During the transition from alert phase via NREM and REM phase of sleep, diameter of airway is instable. Sleeping and dreaming directly cause a loud breath phenomenon. What furthermore contribute are the soft tissues in throat that are highly disproportional compared to the airspace where they are settled [2,3]. Obstructions arise mostly in oral part of the throat, on Velopharyngeal Sphincter.

The mechanism consists of the repeated apposition of the lateral wall of throat, collapse of soft palate and the backward move of the tongue basis. If during that time occlusion of air way appear snore begins, and if the passage is completely blocked, condition is defined as apnea. Instability of respiratory control system, upset

of mechanic and reflex sensitivity are identified as possible co-factors in pathogenesis of the syndrome. For snoring we say that it is common but not normal. Snoring is the biggest killer of a quiet bedroom because of snoring, otherwise successful marriages fell apart [4]. We can conclude that snoring is the illness of marriage partner, illness of the listener, romance killer, and a destroyer of idyll, but at the same time the most critical test of love for the partner. I can hardly remember one woman saying that her partner never once snored. On the contrary, more and more men complain that their wives snore loudly. The truth is that they produce a snore of less intensity than men. Rhonchopathy (snoring) is the biggest test of a marriage and statistics show that it comes forth on the scale of reasons that romantic relationships fall apart [5,6].

Asked whether they would like to have an unfaithful man or man who snores loudly, 30% of women in France answered that they would prefer the first option. Women whose partners snore also complain that they are not satisfied with the love making in the relationship. One of polls about sexuality done in United States also covered permanent snoring and persons with apnea problem, and it showed that approximately 25 adults above the age of 30 were not interested in having sex because of a diminished libido and impotence. The conclusion was that those and not snoring that prevents peaceful sleep are primary reasons for the split between partners (Figure 1).



Figure 1: Terror for ears, Men that snore do not hear themselves, but snore irritates the person close to them. Chronic snores and those with apnea problems spend little time in deep sleep that is essential for good rest, so that daily dizziness appears to be one of the leading symptoms.

Are there more horrible weaknesses than loud snoring?

Snoring is present in both genders, among all races and on all continents. Some 30-35% of adults snore from time to time, and 20 to 25 per cent snore permanently. Somewhere between 60% of men and 40% of women above 60 tend to snore, and the phenomenon is two to three times bigger among men [6,7]. There are opinions that the reasons for this lay in the distribution of greasy tissue and imbalance of hormones. What is more, the airway among women is less collapsible than among men. After a certain period, the difference diminishes. Hormonal substitution therapy in the menopause reduces the frequency of ronhopathy. Even 10-15% of children between the age of 3 and 6 snore frequency of snoring rises with the overdose of food before sleep, alcohol intake during the evening, excess of weight, intake of sedatives, sleeping on the back, etc.

Two thirds of those confronted with the symptom are at least 20% overweight. There is a clear connection between fatness and snoring. BMI (index of weight) and anatomy dimensions of the neck are essential. The wider the neck, the bigger is the problem. Some men do not snore even with these characteristics. This shows us the existence of predisposition factors in a man, or some anomalies that are considered an illness, but permanent condition that mobilizes itself during sleep. During the alert condition it does not pose any problem to the patient, but in connection with above mentioned co-factors that activate during sleep, they represent *locus minoris* of resistance and together, they make a pathophysiologic base for the obstruction and thus snoring happens.

Today, nearly all etiologic factors connected with that notion are known, but what remains unclear is when somebody will began to snore, whether they will begin to snore at all, and when snoring turns to apnea. Many studies of those patients did not give answers to the above questions. Dilemma about surface sleep has been settled, but enigma remains about why they do not hear their music, although it can reach the intensity of over 90 decibels. Snoring is not common only with the humans, some domestic animals snore

as well, especially cats and dogs. If left without medical care, snoring will last throughout lifetime end with gradually tendency of deterioration and entrance to the terminal phase called “sleep apnea”. At that phase, usually it leaves repercussions on other organs and systems. Patients, and medical persons as well, often minimize the seriousness of the condition, saying that many people live up to a 100 years with this problem.

The main risk factor of the syndrome lays in bigger body weight [7,8]. Besides, the constitution, age and sex are some of other factors that account for appearance of loud sleeping. It is well known that sleeping on the back increases snoring. Snorers sleep on their back more that 80 per cent of the time, and during one hour of sleep they change position 4 times. Abundant alcohol intake before sleep, greasy and heavy food during evening times as well as use of sedatives, makes snoring even worse. Analyzing the frequency of snoring in relation to the period of sleeping, it was found that in the period between 10 and 12 PM and 4 to 6 AM snoring is mostly present. Some start with loud snore during the first sleep, continuing throughout the night. More that one half of inhabitants in Serbia has a weight problem, and almost every fifth belongs in the overweight category the wider the neck, the longer the belt, the bigger the problem.

What Causes Snoring

More than 40% of people that snore complain about hard breathing through the nose. Clinical survey shows that a scope of pathological situations in the nose such as a curved nose bones, large nostrils, allergic rinitis, polyp and other deformations, contribute to patophysiology of rhonchopathy (snoring). Every fifth person suffers from some kind of a respiration allergy. If allergies are present, the risk of snoring is much higher. That shows the connection between breath through nose and loud sleep. By elimination of that state in almost 20% of cases reduction of noise during sleep is accomplished or limited to an acceptable level. Orofaringeal occlusion that arises after the sudden collapse of the palate muscle, uvula and throat, is supposed to be one of the most frequent factors guilty for restless sleep [7,8]. Obstructions on that level are most responsible for the rise of those disadvantages.

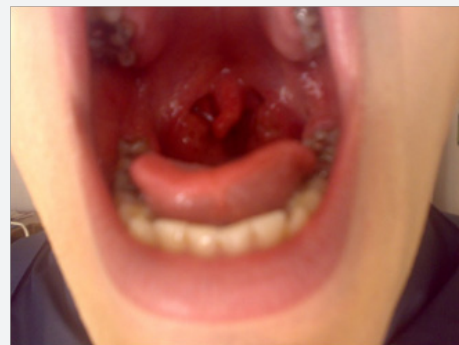


Figure 2: Orofaringeal find by notorious snore. Enlarged tonsils, long Uvula, large palate and medium-lowered walls of throat are the most frequent etiologic factors of ronhopaty and apnea.

Namely, when large quantity of air gets into a narrowed air passage, it causes flit-flicker of structures mentioned, similarly to lose sails on the wind, producing a noise that can remind us on lion roar, cows bleat-low, etc. Noise intensity depends on the structures that vibrate. With children, although not with adults, bloated tonsils are main causers of those obstructions and if eliminated, the struggle ceases to exist. With adults, long uvula, wide palate and slouch velopalatinal segment usually lead to a retropalatinal obstruction. By examination, so rarely, regular ORL is found, but examination has been done in state of weakness. Contrary, during sleep, especially in REM phase, abrupt weakness of these muscles causes the collapse, obstruction, snoring and apnea (Figure 2).

With patients that snore, retro lingual obstruction is caused by too large tongue basis, enlarged lingual tonsils, tongue relocated backwards and retro position of the bottom jaw is more than rare findings. Occlusions on that level are usually the hardest for surgical intervention. The condition worsens when sleeping on back, when bottom jaw and tongue, due to gravitation and hipotony of muscles fall backward and reduce more air way. Besides, there are also some other abnormalities, which can contribute to a loud snore during sleep.

Exterior compression of upper airways caused by big tumors on the neck can also contribute to pathology of snore. Although notorious snore is seen as side effect, it influences human life in different ways. Aside from loud and restless snoring during night, accompanying syndromes are extensive daily dizziness, chronic tiredness (in the morning patients feel more tired than before going to sleep), dry lips, frontal headaches, changes in the mood etc. If snoring is accompanied with apnea (pause in breath) some other symptoms can appear as well, such as high blood pressure, incorrect heart function, brain stroke, diabetes, and with children night peeing etc.

Diagnosis

(Figure 3) In evaluation of the patients condition, diagnosis requests the use of Polysomnography as the "golden standard". This examination can be done in the Department for Breath Problems during sleep, in Sremska Kamenica, led by Dr Kopitovic (Figure 4).

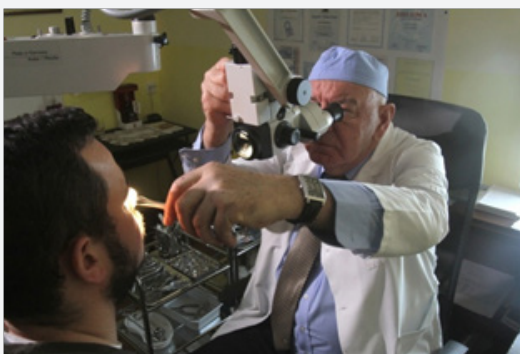

Figure 3: Every case of loud snoring must pass through detailed clinical examination.



Figure 4: Patient prepared for polysomnography.

During such examinations some parameters can be found and among them degree of oxygenation, longitude and number of breath brakes, oscillations of heart and blood pressure, clamor intensity, stand as the most important. To find the narrowest airway, technique (APNEA GRAPH) is used, and it gives us information on time, occlusion level and scale. Depending on the results, patients for surgical and non-surgical treatment are chosen. Even through a clinical examination in respectable cases the cause for above-mentioned problems can be detected. Namely, by healthy persons distal end of soft palate and ovulate lays above horizontal plane of tongue, that is not the case by loud snores. Using faringoscopy in some cases, immediately after sleep, some cyanotic and bloated deformations on uvula can be seen, as signs of abundant night activity. Beginning of examination must always start from the nose. When the case is about bone deformations and abnormalities, cefalometric analyses can be of help.

Therapy

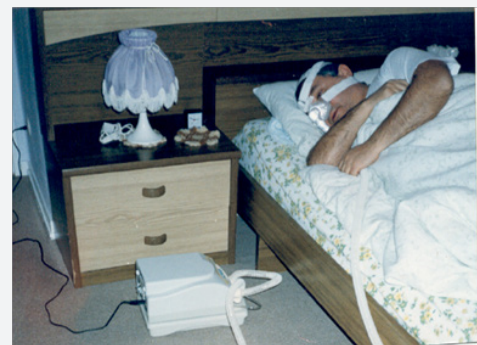

Figure 5: Patient using CPAP device that brings air in lungs under pressure. In treatment of apnea it represents a "golden standard".

To relieve from the unpleasant feature, some measures of self-help can be of use. In the case of milder snores and temporary appearance of rhonchopathy, first, reduction of weight, avoidance of abundant evening meals and drinks, drugs and sedatives, as well as evening walks, sleeping on side with a highly positioned pillow etc., can bring to prosperous results. In the case of loud snores in every position of the body, even on stomach, treatment needs some gadgets and instruments, or a surgical intervention. Dental stretch

that pushes upper and lower jaw towards the front, helping the airway open, can also prevent snoring. Devices that bring air by pressure in lungs are primary used by patients with apnea, and are seen as the best option of non-surgical treatment of those patients. During use, patients feel well, when they stop using, state of health detonates back to the previous level (Figure 5).

Surgical treatment

Obstructions that are of anatomic-pathologic problem belong to a surgical domain. Today, there is only one way of healing the patient completely, not temporarily, and it is called "a cut for a silent sleep". This does not mean that every patient with rhonchopathy has to go under scalpel. Surgical intervention may not be an ideal option for every patient, but it is an option that every person willing to get rid of snoring permanently, deserves. Surgical clutch consists of widening the airway, leaving it open enough and stable during the whole night, every night. Sometimes, it is impossible to modify all narrow ways with one clutch, so the strategy is that the first place with the most narrowness must be dilated, and afterwards the need for post-intervention is decided on. If snoring lowers and does not pose a problem, it can be said that the intervention was successful. Every patient must be treated separately, because every case is unique.

There is not one and only intervention for all patients and there is not one and only surgical intervention that can be used on all of them. Always and first, nasal obstruction must be solved, and after that, depending on diagnostic criteria, other places of occlusion are eliminated. Solving the nasal pathology only helps in some 20 per cent cases [9,10]. If the case is only about permanent snoring, intervention on velopharynx complex of uvulopalatopharyngoplastic type will give solid results in 80% of cases, and with sleep apnea, in approximately 60 per cent cases/. The best surgical results are achieved by maxilo-mandibular osteotomy, i.e. by moving upper and lower jaw forward [11,12]. Method is a morbid one, heavy, and needs special working conditions, and special experts profile.

Interventions on the base of the tongue, hyoid bone and muscle of throat dilators are intended for solving of retro lingual obstruction [13]. If the place of occlusion is base of tongue, success of intervention covers approximately 70% of cases (Figure 6). Operations of uvulopalatopharyngoplastic type last approximately 40 minutes. During the intervention, tonsils, uvula, part of free pair of soft palate and forward arch are eliminated. Back palate arches are reduced. Orofaringeal air way is widened. During the intervention, radio-wave laser of 4.0 MHz is in use, helping precise, solid and almost bloodless work. Velopfaringeal insufficiency and pfaringeal stenosis are the most frequent complications that arise during intervention, and request additional treatment [13,14]. During several days after surgical intervention, pain, infection, changes in tone of voice, and hard engulf can arise. Bleeding that could be premature or in later phase of intervention could cause complications.

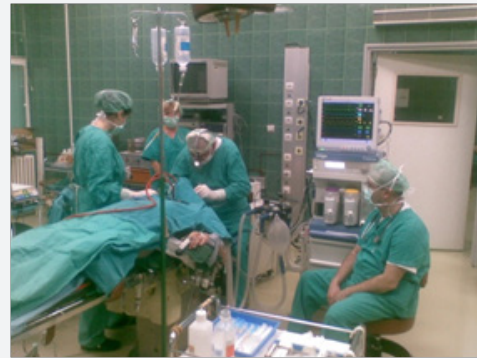

Figure 6: Stiffening uvulopalatoplasty and glossoptasty assisted RF. Operation without cut and sutures with combination of intervention on palate and base of the tongue, results are even better. When in comply with diagnostic-surgical protocol, which understands marking of the obstruction place and then its surgical extension, success could not escape.

Unstable results are the main problems of such interventions. In the beginning, success is much bigger. With years that pass, for unknown reasons, success decreases. Prediction is that such trend is caused by bigger weight and weakness of jaw and throat muscles during aging. Surgical intervention of that type is not recommended to persons with less than 20 and more than 70 years. Surgical intervention can be done by a classic cut using laser or radio-frequency waves. We use Surgitron Ellman 4.0 MHz, convinced that it has numerous advances comparing to other electro-surgical devices [15,16].

Conclusion

There are several ways in which the patients can be cured from rhonchopathy. Regulation of body weight, sleep discipline, avoiding sedatives, alcohol, heavy meals etc. may have a favorable effect on the reduction of snoring. Application of the CPAP apparatus, dental prostheses and other devices serve as a prevention of but not the cure from this syndrome. Surgical treatment of this pathology involves multiple operational methods and techniques, aimed at removing the obstruction of the upper airway at the level of the nose to the trachea. The selection of the method itself is not always easy, as there are different arguments for and against each method. What is more important is whether the surgery is the right option for you. This does not mean that everyone diagnosed with noisy sleeping should hurry under the knife. The operation should extend the narrow airways and leave them open and stable enough throughout the night, every night. If there is an obstruction on multiple levels (nasal, oropharyngeal, retrolingual etc.), we first expand the largest obstruction, and if the result fails, other ones are treated. Each patient must be considered individually because each case is different. There is not one single treatment for all patients, nor all patients can be treated with the same operation. The author concludes that the operation does not have to be the best option for everyone, but is indicated in the cases when other methods have failed.

References

1. Riley RW, Powell NB, Li KK, Troell RJ, Guilleminault C (2000) Surgery and obstructive sleep apnea: long-term clinical outcomes. *Otolaryngol Head Neck surg* 122(3): 415-421.
2. Rombaux Phamoir M, Bertrand B (2003) Postoperative pain and side effects after uvulopalatopharyngoplasty, laser-assisted uvulopalatoplasty, and radiofrequency tissue volume reduction in primary snoring. *Laryngoscope* 113: 2169-2173.
3. Kuhnel T, Hein G, Hohenhorst W (2005) Soft Palate Implants; A New Option For Treating Habitual Snoring. *Eur Arch Otorhinolaryngol* 262(4): 277-280.
4. Enoz M (2005) Cautery-assisted stiffening operation for the treatment of obstructive sleep apnea syndrome. *Otolaryngol Head Neck Surg* 133: 648-649.
5. Magne Tvinnereim, Svetislav Mitic, Rolf Hansen (2007) Plasma Radiofrequency Preceded by Pressure Recording Enhances Success for Treating Sleep-Related Breathing Disorders. *Laryngoscope* 117: 731-736.
6. Jan Wedman, Harald Miljeteig (2002) Treatment of Simple Snoring Using Radio Waves for Ablation of Uvula and Soft Palate: A day-Case Surgery Procedure. *Laryngoscope* 112: 1256-1259.
7. Croft CB, Golding-Wood DG (1990) Uses and complications of uvulopalatopharyngoplasty. *J Laryngol Otol* 104: 871-875.
8. Carenfelt C (1991) Laser uvulopalatoplasty in treatment of habitual snoring. *Ann Otol Rhinol Laryngol* 100: 451-454.
9. Carenfelt C, Haraldsson PO (1993) Frequency of complications after uvulopalatopharyngoplasty. *Lancet* 341: 437-440.
10. Ellis PD, Fowes Wiliams JE, Sheerson JM (1993) Surgical relief of snoring due to palatal flutter:a preliminary report. *Ann R Coll Surg Eng* 75: 286-290.
11. Vukoje N (1998) Snoring and how to prevent 1998, book, Prosveta, Novi Sad.
12. Vukoje N (2008) Rez za miran san, knjiga, Izdavacka knjizarnica Zorana Stojanovica, Novi Sad, 2008 god.
13. Vukoje N (2015) Hrkanje i slup apneja -uzroci i lečenje.Med. knjiga, Petrovaradin.
14. Vukoje N (2008) Significance of surgical solution of the palatal obstruction in the therapy of chronical snoring(demonstration of authors innovative technique) 13th congress of Balcan Military Medical Committee, Kushadasi, Turkiye.
15. Murat Enoz, Jose Florencio Lapena, Hasan Mete Inanch, Gunter Hafiz (2010) Modified sling snoreplasty: double triangle shaped suture uvulopalatopexy; *Kulak Burun Bogaz Ihtis Derg* 20(1): 51-55.
16. Dr Jon C Garito US Patent reference number #5.954.686 Inventor the dual Frequency device, USA.



This work is licensed under Creative Commons Attribution 4.0 License
DOI: [10.19080/GJO.2017.10.555792](https://doi.org/10.19080/GJO.2017.10.555792)

Your next submission with Juniper Publishers will reach you the below assets

- Quality Editorial service
- Swift Peer Review
- Reprints availability
- E-prints Service
- Manuscript Podcast for convenient understanding
- Global attainment for your research
- Manuscript accessibility in different formats
(Pdf, E-pub, Full Text, Audio)
- Unceasing customer service

Track the below URL for one-step submission
<https://juniperpublishers.com/online-submission.php>