

Tuberculosis of the Cervical Spine Morb Pott Cervicalis our Experience



Cristina Otilia Laza^{1*}, Gina Enciu¹ and Simona Andreea Dinu²

¹ENT Clinic SCJU, SF APOSTOL ANDREI", Constanta, Romania

²Department of Orthopaedic for skeletal tuberculosis, Agigea

Submission: January 17, 2018; **Published:** February 06, 2018

***Corresponding author:** Cristina Otilia Laza, ENT Head and Neck surgery, ENT/OMF Clinic, SCJU SF "APOSTOL ANDREI" Constanta, B-dul Tomis, 145,8700, Constanta, Romania, Email: cristinaotilia@gmail.com

Abstract

Tuberculosis disease is commonly caused by Mycobacterium tuberculosis and is a serious health problem particularly in countries with poor medical system but even in most developed countries immigrants caused problems, also in AIDS or immune-depressant patients. There are rare types of TB difficult to diagnose, We would like to present 3 patients with Morb Pott, 2 with retropharyngeal abscess, one patient 71 year old with classical type of retropharyngeal collection the other one much younger 43 years old the lesions were extremely advanced with myelitis and tetraplegia and death. The third case is a 56- year-old man patient with cervical spine tuberculosis and cold abscess in the posterior neck triangle the diagnosis was mainly based on symptoms like neck pain, dysphagia, dyspnea and non specific complaints such as weight loss and fever but really the diagnostic is mainly based on, imagistics, biopsy and microbiology, cultures Before the advent of chemotherapy in 1994, treatment was basically bed rest, but now .treatment implicate a multidisciplinary team-first we evacuate the collection repeatedly till healing ,than chemotherapy program will be impose and follow-up by an ftisiologist and un orthopedic surgeon must immobilized the spine Surgical treatment is considered in cases of severe spinal instability or progressive neurological symptoms with evidence of cord compression or deformation.

We insist to present the cases to remember that Tuberculosis is near us, with a lots of surprising faces masks, and is a great challenge to physicians because of the nonspecific and wide spectrum of clinical presentations. That result in delay of diagnosis and the risk of significant potential morbidity and mortality due to several complications. Early diagnosis and treatment avoid long-term disability.

Keywords: Tuberculosis of the cervical spine; Morb Pott; Retropharyngeal abscess

Introduction

Tuberculosis, is an infection with Mycobacteria tuberculosis: -an aerobic slender, non motile, non capsulated, non sporing, rod shaped organism 2-5µ in length. Complex fatty substance in their wall Zielh Nielsen staining bright red Auramine and rhodamine dyes are also helpful to identify the organisms by fluorescence

Primary infection is typically an asymptomatic lower lobe lesion, and a calcified lung lesion and a draining lymph node are often present, thus forming a Ghon complex. Secondary involvement manifests with night sweats, fever, weight loss, and chronic, nonproductive cough. It also affects apical segments. Clinical and radiographic features: Primary tuberculosis is usually asymptomatic-occasionally fever & pleural effusion is seen Low grade fever malaise, anorexia, weight loss, & night sweats, Haemoptysis, chest pain, Wasting syndrome called as consumption.

Extra pulmonary TB

In AIDS pt. 50% will have extra pulmonary TB any organ can be affected. Most common extra pulmonary sites of head and neck are the cervical lymph nodes followed by the larynx,

oropharynx and middle ear. Much less common sites include the nasal cavity, nasopharynx, oral cavity, parotid gland, oesophagus and spine. Other head and neck sites can be involved.

Tuberculosis of the cervical spine

TB of the cervical spine also called Morb Pott disease, or tuberculous spondylitis, is one of the oldest demonstrated diseases of humankind, having been documented in bony spinal remains from the Iron Age in Europe and in ancient mummies from Egypt and South America. In 1779, Percivall Pott, for whom the disease is named, presented the classic description of spinal tuberculosis.. Tuberculous involvement of the spine cause serious morbidity, including permanent neurologic deficits and severe deformities.

Epidemiology

Since the advent of antituberculous drugs and improved public health measures, spinal tuberculosis has become rare in industrialized countries, although it is still a significant cause of disease in developing nations. Approximately 1-2% of total tuberculosis cases are attributable to Pott disease

musculoskeletal tuberculosis affects primarily african, hispanic, asian Americans, and foreign-born individuals. As with other forms of tuberculosis, the frequency of Pott Disease is related to socioeconomic factors and historical exposure to the infection. Pott disease does not have a sexual predilection, but is more common in males. Pott disease occurs primarily in adults, but poor countries young adults and older children are more exposed Mycobacterium tuberculosis ,as result of haematogenous dissemination from a primary focar reaches the skeletal system through vascular channels, generally the arteries, as a result of bacillema, or rarely in the axial skeleton through Batson’s plexus of veins. The infection spreads to the adjacent vertebral bodies under the longitudinal ligaments. The most common site is the thoracolumbar junction, but any segment of the spine can be involved; TB of the cervical region accounts for 10% of all cases of spinal TB. As the infection progresses, the periosteal and the

longitudinal ligament is lifted off the surface of the vertebral body with destruction of the vertebrae, necrosis, caseum abscess formation .The cold abscess formed sometimes remains close to the vertebrae, or extend in prevertebral or paravertebral spaces creating abscess in those dangerous spaces.. The abscess is prominent into the pharynx resulting in odynophagia, dysphagia, pharyngeal discomfort and airway obstruction, respiratory distress and twelfth-nerve palsy. The retropharyngeal area is a potential space in the facial planes, located between the Pharyngeal fascia and the prevertebral fascia. The contents among others include retropharyngeal Gillette lymph nodes (in children) and fat tissue. The former forms part of the lymphatic drainage of the head and neck region, which may explain why retropharyngeal abscess is common in children, but very rare adults, except as a consequence of trauma to the head and neck region or a Morb Pott disease (Figures 1 & 2).

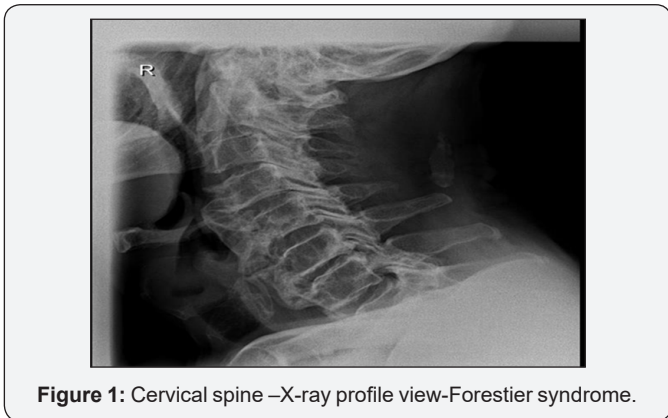


Figure 1: Cervical spine –X-ray profile view-Forestier syndrome.

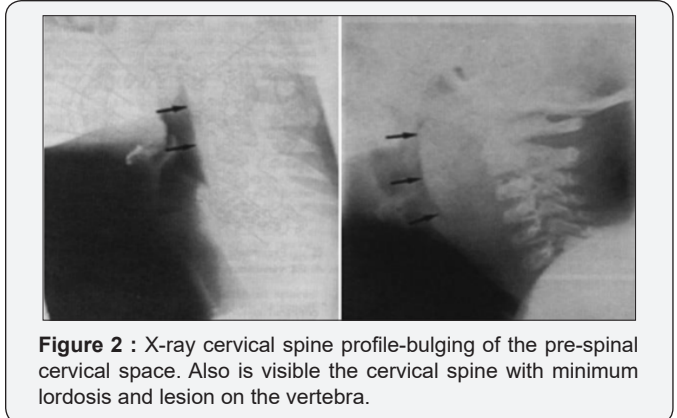


Figure 2 : X-ray cervical spine profile-bulging of the pre-spinal cervical space. Also is visible the cervical spine with minimum lordosis and lesion on the vertebra.

Clinical Presentation

Anamnesis

History of the disease progressive onset, dominant symptoms, response to treatment neurologic acuses like paraplegia, paresis,

History of the family, other diseases of the patient, especially Pulmonary tuberculosis, chronic diseases like diabetes, renal liver failure History of chronic medication but also we have to insist on intoxication with tobacco ,alcohol ,drugs Symptoms are intricated general, primary focar, secondary localization. The reported average duration of symptoms at diagnosis is 4 months but can be considerably longer due to the nonspecific presentation of chronic neck pain

The presentation of Pott disease depends on the following:

- Stage of disease
- Affected site

Presence of complications such as neurologic deficits, abscesses, or sinus tracts Potential constitutional symptoms of Pott cervical disease include fever and night sweets fatigue, anorexia, weight loss neck pain is the earliest and most common symptom of Pott disease, with patients usually experiencing this problem for weeks before seeking treatment. The pain in Pott

disease can be spinal or radicular. -Neurologic abnormalities occur in 50% of cases and can include spinal cord compression with -paraplegia -paresis -impaired sensation, nerve root pain, and/or cauda equina syndrome.

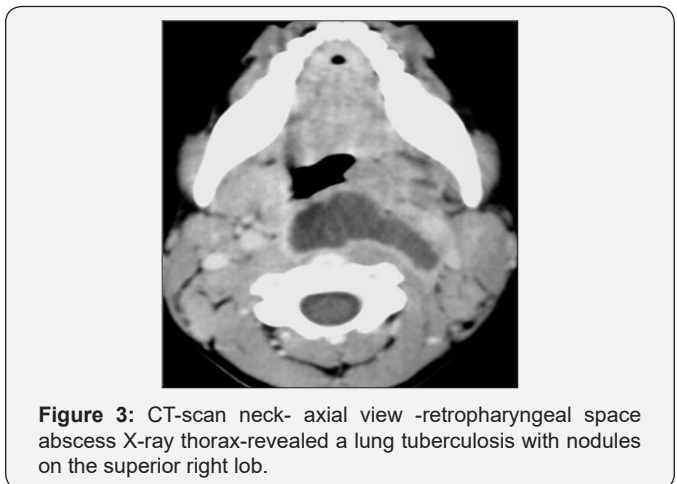


Figure 3: CT-scan neck- axial view -retropharyngeal space abscess X-ray thorax-revealed a lung tuberculosis with nodules on the superior right lob.

Cervical spine tuberculosis is a less common presentation but is potentially more serious because severe neurologic complications are more likely. This condition is characterized by pain and stiffness. Patients with lower cervical spine disease can

present with dysphagia or stridor. Symptoms can also include torticollis, hoarseness, and neurologic deficits (Figures 3-5).

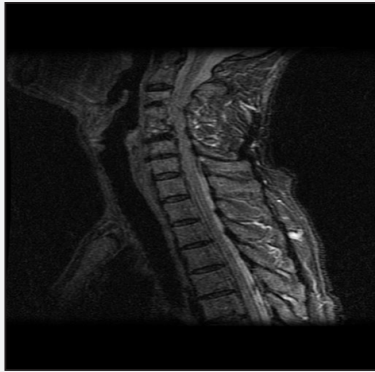


Figure 4 : MRI-sagittal view -Tuberculosis of the cervical spine =MORB POTT =with retropharyngeal collection but already drained.

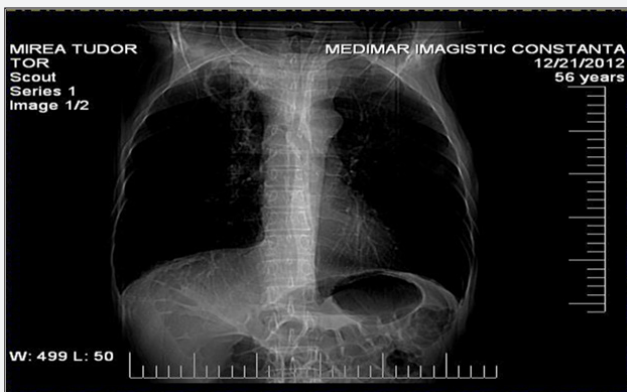

Figure 5: X-ray chest –tuberculosis of the lung with a left superior lob cavity.

The clinical presentation of spinal tuberculosis in patients infected with the human immunodeficiency virus (HIV) is similar to that of patients who are HIV negative; however, spinal tuberculosis seems to be more common in persons infected with HIV.

Physical Examination

- The physical examination in Pott disease should include the following:
- Careful assessment of spinal alignment
- Inspection of skin, with attention to detection of sinuses
- Abdominal evaluation for subcutaneous flank mass
- Meticulous neurologic examination

Although the thoracic and lumbar spinal segments are nearly equally affected in persons with Pott disease, the thoracic spine is frequently reported as the most common site of involvement only 10% occurring in the cervical spine [1-3]. Almost all

patients with Pott disease have some degree of spine deformity (kyphosis).

Examination should reveal local pain related to the affected area or radicular pain. Muscle spasm and rigidity can also be associated. Neurologic deficits may occur early in the course of Pott disease. Signs of such deficits depend on the level of spinal cord or nerve root compression. Retropharyngeal abscesses occur in almost all cases affecting this part of the spine. Neurologic manifestations occur early and range from a single nerve palsy to hemiparesis or quadriplegia. In reported series, only 10-38% of cases of Pott disease are associated with extraskelatal tuberculosis Physical examination findings associated with TB depend on the organs involved. Patients with pulmonary TB may have the following:

- Abnormal breath sounds, especially over the upper lobes or involved areas
- Rales or bronchial breath signs, indicating lung tuberculosis

Diagnostic

Screening methods for TB include the following:

Idr PPD -Mantoux tuberculin skin test

Interferon gamma release assay (IGRA) with antigens specific for Mycobacterium tuberculosis for latent infection.

Acid-fast bacilli (AFB) smear and culture using sputum obtained from the patient: A negative smear - does not exclude active TB infection; AFB culture is the most specific test for TB

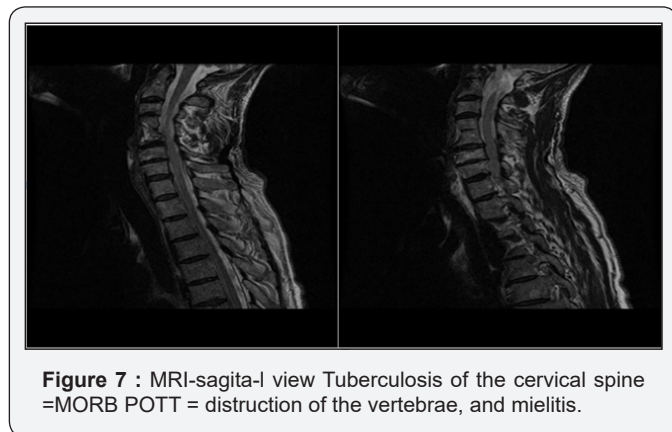
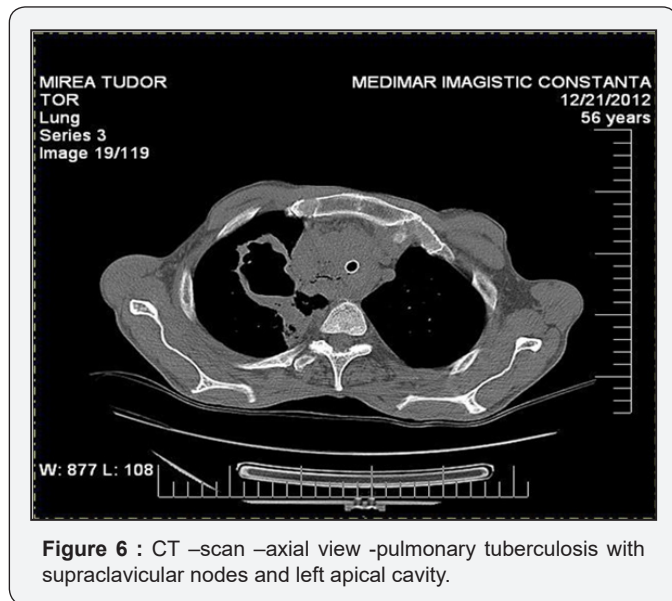
- HIV serology in all patients with TB
- Specific enzyme-linked immunospot (ELISpot)
- Nucleic acid amplification tests
- Blood cultures
- Direct DNA sequencing analysis
- Automated molecular testing
- Microscopic-observation drug susceptibility (MODS) and thin-layer agar (TLA) assays

Additional rapid tests (ex, BACTEC-460, ligase chain reaction, luciferase reporter assays, FASTPlaque TB-RIF, QuantiFERON test). All tuberculosis cases should be reported to the local public health department, and patients with tuberculosis should be tested for HIV [4-7].

Biopsy

Percutaneous, CT scan guided needle biopsy of bone lesions for anatomo-pathologic studies is very important Biopsy from granulation resulted from surgical drainage of abscesses Microbiologic studies to confirm diagnosis and to isolate organisms for culture and susceptibility. Frequent negative

Drainage Some cases of Pott disease are diagnosed following an open drainage procedure (eg, following presentation with acute neurologic deterioration) Figures 6 & 7.



Imagistics

Rx-of the thorax to evaluate for possible associated pulmonary findings:

- Cavity =advanced infection; with a high bacterial load
- Noncalcified round infiltrates==differential with lung carcinoma
- Calcified nodules (usually 5-20 mm): Tuberculomas=old infection
- Primary TB== pneumonia-like ==infiltrative process in middle or lower lung
- Reactivation TB: Pulmonary lesions in posterior segment of right upper lobe, apicoposterior segment of left upper lobe, and apical segments of lower lobes
- TB associated with HIV ==atypical lesions or normal chest radiographic findings

- Healed and latent TB: Dense nodules in hilar or upper lobes;
 - Millitary TB: Numerous small, nodular lesions that filled both lungs ,septicemia
 - Pleural TB empyema
 - Lytic destruction of anterior portion of vertebral body
 - Increased anterior wedging
 - Collapse of vertebral body
 - Reactive sclerosis on progressive lytic process
- Additional radiographic findings may include the following:
- Vertebral end plates are osteoporotic.
 - Intervertebral disks may be shrunk or destroyed.
 - Vertebral bodies show variable degrees of destruction.
 - Fusiform paravertebral shadows suggest abscess formation.
 - Bone lesions may occur at more than 1 level.

Scintigraphy

Radionuclide scanning findings are not specific for Pott disease. Gallium and technetium bone scans yield high false-negative [8-12].

CT Scanning neck, thorax

- CT scanning provides much better bony detail of irregular lytic lesions, sclerosis, disk collapse, and disruption of bone circumference. Low-contrast resolution provides a better assessment of soft tissue, particularly in epidural and paraspinal areas.
- CT scanning reveals early lesions and is more effective for defining the shape and calcification of soft-tissue abscesses. In contrast to pyogenic disease, calcification is common in tuberculous lesions.

Magnetic resonance imaging

(MRI) is the criterion standard for evaluating disk-space infection and osteomyelitis of the spine and is most effective for demonstrating the extension of disease into soft tissues and the spread of tuberculous debris under the anterior and posterior longitudinal ligaments. . MRI is also the most effective imaging study for demonstrating neural compression.

- Contrast-enhanced MRI findings in Pott disease include thin and smooth enhancement of the abscess wall and a well-defined paraspinal abnormal signal.
- Thick and irregular enhancement of the abscess wall and an ill-defined paraspinal abnormal signal suggest pyogenic spondylitis.
- Differential diagnosis of Pott disease include the

following:

- Millitary Tuberculosis
- Septic spondylitis
- Spinal cord abscess
- Spinal tumors
- Metastatic Cancer With Unknown Primary Site
- Multiple Myeloma
- DISH- Diffuse Idiopathic Skeletal Hyperostosis- Forestier syndrome

Complications

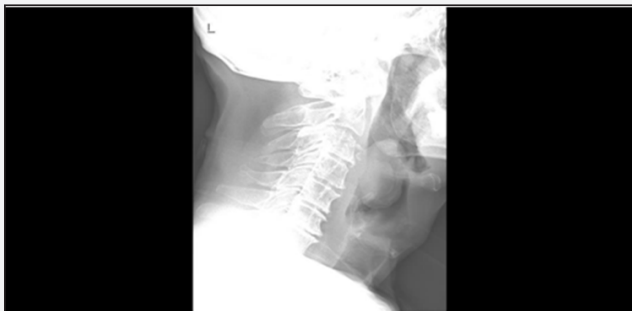

Figure 8 : Lateral view of X-ray of the cervical spine, showing straightening of the normal cervical lordosis, collapse, and sclerosis of C3 and C4 vertebrae and obliteration of the C2/C3 and C3/C4 disc spaces.

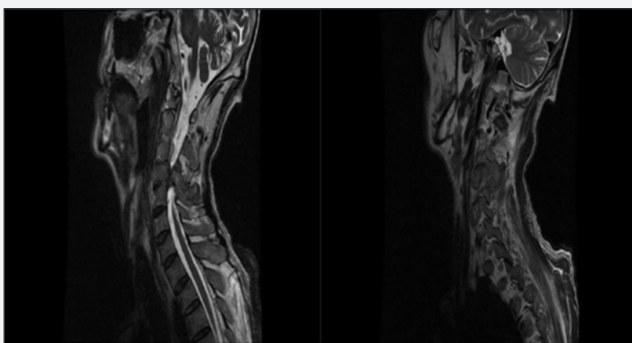


Figure 9 : Lateral view of X-ray of the cervical spine, showing straightening of the normal cervical lordosis, collapse, and sclerosis of C3 and C4 vertebrae and obliteration of the C2/C3 and C3/C4 disc spaces.

Pott disease is the most dangerous form of musculoskeletal tuberculosis because it can cause-bone destruction, deformity, paraplegia, resulting from spinal cord compression usually respond well to chemotherapy, sometimes operative decompression is required motor deficit –a nerve is compressed Association impairment scale (ASIA) is useful to document neurological recovery from Pott disease. A designation of ASIA A indicates the most severe neurological compromise, ASIA E the least. At the beginning of treatment, most individuals are characterized as ASIAD. Late-complication can still occur

reactivation of TB instability or deformity of the spine (Figures 8 & 9) [13-17].

Consultations

- Orthopedic surgeon
- Neurosurgeon
- Rehabilitation team
- Phtisiology

Treatment

Before the advent of effective antituberculosis chemotherapy, Pott disease was treated with immobilization using prolonged bed rest or a body cast. At the time, the disease carried a mortality rate of 20%, and relapse was common (30%). Physical measures (if possible or practical) include the following:

- Isolate patients with possible TB in a private room with negative pressure
- Have medical staff wear high-efficiency disposable masks sufficient to filter the bacillus
- Continue isolation until sputum smears are negative for 3 consecutive determinations (usually after approximately 2-4 weeks of treatment)

Cast or brace immobilization was a traditional form of treatment but has generally been discarded. Patients with Pott disease should be treated with external bracing.\Once the diagnosis of Pott disease is established and treatment is started, the duration of hospitalization depends on the need for surgery and the clinical stability of the patient. The mainstay of treatment is anti-TB therapy. Although optimum treatment for tuberculosis of the spine is still a subject of debate, management of patients should be individualized and this generally depends on location and extent of the lesion, spinal stability, presence or absence of spinal deformity, and severity of neurologic impairment According to recommendations issued in 2003 by the US Centers for Disease Control and Prevention (CDC), the Infectious Diseases Society of America, and the American Thoracic Society, a 4-drug regimen should be used empirically to treat Pott disease [18-21].

Isoniazid and rifampin should be administered during the whole course of therapy. Additional drugs are administered during the first 2 months of therapy. These are generally chosen from among the first-line drugs, which include pyrazinamide, ethambutol, and streptomycin. The use of second-line drugs is indicated in cases of drug resistance.

Treatment duration is for 6-9 months but in patients with multiple vertebral involvement, cervical lesions, or major neurologic involvement 9-12 months. For selected cases with surgical indication that allows complete debridement of the lesion, a combination of surgery and ultra-shortened course of therapy (4.5 mo), appears to show comparable outcomes of a combination of surgery and 9 months of drug therapy.

Special considerations for drug therapy in pregnant women include the following: In the United States, pyrazinamide is reserved for women with suspected MDR-TB. Streptomycin should not be used. Preventive treatment is recommended during pregnancy. Pregnant women are at increased risk for isoniazid-induced hepatotoxicity. Breast feeding can be continued during preventive therapy. Most children with TB can be treated with isoniazid and rifampin for 6 months, along with pyrazinamide for the first 2 months if the culture from the source case is fully susceptible. For postnatal TB, the treatment duration may be increased to 9 or 12 months. Ethambutol is often avoided in young children. Special considerations for drug therapy in HIV-infected patients include the following [22-25].

Dose adjustments may be necessary. Rifampin must be avoided in patients receiving protease inhibitors; rifabutin may be substituted. Considerations in patients receiving antiretroviral therapy include the following:

Patients with HIV and TB may develop a paradoxical response when starting antiretroviral therapy. Starting antiretroviral therapy early (eg, < 4 weeks after the start of TB treatment) may reduce progression to AIDS and death in patients with higher CD4+ T-cell counts, it may be reasonable to defer antiretroviral therapy until the continuation phase of TB treatment.

Multidrug-resistant TB

When MDR-TB is suspected, start treatment empirically before culture results become available, then modify the regimen as necessary. Never add a single new drug to a failing regimen. Administer at least 3 (preferably 4-5) of the following medications, according to drug susceptibilities:

- An aminoglycoside: Streptomycin, amikacin, capreomycin, kanamycin
- A fluoroquinolone: Levofloxacin (best suited over the long term), ciprofloxacin, ofloxacin
- A thioamide: Ethionamide, prothionamide
- Pyrazinamide
- Ethambutol
- Cycloserine
- Terizidone
- Para-aminosalicylic acid
- Rifabutin as a substitute for rifampin
- A diarylquinoline: Bedaquiline

The current incidence of resistance to at least one drug in the United States is 19%, and 1% for multidrug resistance (resistance to at least isoniazid and rifampin). This makes following cultures and susceptibility testing important to make sure that the usual drug combinations are effective.

Surgical treatment

Resources and experience are key factors in the decision to use a surgical approach. The lesion site, extent of vertebral destruction, and presence of cord compression or spinal deformity determine the specific operative approach (kyphosis, paraplegia, tuberculous abscess). The most conventional approaches include anterior radical focal debridement and posterior stabilization with instrumentation. Newer modalities and techniques are being reported, such as endoscopic decompression, inj of a special cement in the osteitic vertebra collapsed. In Pott disease that involves the cervical spine, the following factors justify early surgical intervention:

- High frequency and severity of neurologic deficits
- Severe abscess compression that may induce dysphagia or asphyxia
- Instability of the cervical spine
- Contraindications

Vertebral collapse of a lesser magnitude is not considered an indication for surgery because, with appropriate treatment and therapy compliance, it is less likely to progress to a severe deformity. Surgical management offers the advantage of an early ambulation, early neurologic recovery, less hospitalization, and less deterioration of the angle of kyphosis. The best surgical approach according to the report is the Hong-Kong operation (this involves excision of the diseased bone and replacement of the gap created with a bone graft) [26-28].

Cases Reports

Case 1

A 71-year old men presented to the emergency department with severe dyspnea, dysphagia, severe neck pain, rigidity of the spine. His past medical history consist in cardiovascular disorder and diabetes type II with treatment. He had no history of previous TB or TB exposure. His complaints starts slowly, six month ago with slight night sweats and a moderate weight loss, than in the last month dysphagia, odynophagia neck pain were unbearable and difficulties to breath appeared.

Physical examination: Revealed a pale patient, with inspiratory bradipnea and stridor but with a strange resonance.

Palpation of the neck: Revealed a very painful movement of the larynx in horizontal plane but without enlarged lymph nodes and painful and rigid cervical spine.

Bucopharyngoscopy: Abnormal is on the posterior wall of pharynx is visible a large oval mass with intact mucosa but intense inflamed, and depressible. The mass was extended from the oropharynx in the hypo pharynx being localized on the retropharyngeal space. So most of the pharynx left side was compressed by the mass also the larynx. We order in emergency an X-ray profile of the cervical spine in hyperextension. In

emergency because of the respiratory distress, I make a puncture, than incision and draining of the pus from the retropharyngeal space, aspirate the cavity and wash-out the pus with peroxide and saline. Respiratory distress stopped so he didn't require tracheostomy, also deglutition improve day after day

Laboratory test: CBC-anemia lymphocytosis neutrophilia sign of retropharyngeal space abscess microbiological examination, cultures, antibiogram, also BK direct, acid fast bacilli and cultures from the pus also sputum was sent for cito bacteriological examination with BK direct and cultures biopsy the tissue granulation from the cavity after a gentle curettage was sent for histopathology biopsy taken from the pre spinal cervical space as deep as was possible HIV test PCR elevated, ESR erythrocyte segmentation rate elevated QuantiFERON test-positive We continue next days with CT scan thorax and neck + contrast substance to evaluate the damages of the vertebrae and of the lungs induced by tuberculosis, than with MRI of the cervical spine for a complete evaluation of inflammation, status of medullar cord etc.

Attitude start treatment anti biotherapy with Ceftriaxone and Metronidazole plus volumetric and electrolytic rebalancing, steroids to decrease edema, antalgics, parenteral nutrition we continue, to drain the pus from the retropharyngeal space and wash-out with saline or peroxide till the complete healing patient was referred to an orthopedic clinic specialized in the treatment of tuberculosis of the bones. Repeated controls were necessary but the patient was evolving very well under treatment with chemotherapeutics antituberculosis. cervical spine immobilized, and also healing of the lungs long follow-up was necessary with 6 month -1 year CT contrast or MRI scan-neck and thorax control, cultures sputum negative.

Case 2

The patient was a 56 years old men, febrile -with a temperature of 39.3°C despite an antimicrobial regime consisting of Ciprofloxacin, and Metronidazole, Isoniazid, Rifampin, Ethambutol and Streptomycin which had been administered for the past two weeks, being already diagnosed with pulmonary tuberculosis with cavities and tuberculosis of the cervical spine.

At this time, the major findings on physical examination included cachexia, signs of respiratory distress (a respiratory rate of 25/min, productive cough, but insufficiently coughing up), moderate fluid overload (bilateral basal pulmonary riles,). Inspection on the neck revealed and a reddish swelling in the left posterior triangle, also palpation of the cervical spine was very painful and rigidity important, and the mass was very painful, worm and fluctuant suggesting a collection. A puncture in the mass revealed yellow-green fetid pus -so we prepare the patient for surgical drainage. The rest of the exam revealed oral candidiasis and a unilateral segmental herpes zoster rash at the lower back that both indicated relevant immune suppression. Now, routine laboratory studies showed markedly increased inflammatory activity (CRP 22mg/dL), white blood count

of 14,900/ μ L. HIV serology was negative. Remarkably, the interferon- γ release assay QuantiFERON®-TB Gold In-Tube was negative (IFN 0.189 IU/mL).

We immediately surgically drain the neck collection, wash out the pus, clean the necrotic tissues and order microbiological exam, but no microorganisms were detected on gram stain or acid-fast bacilli were negative with both auramine and Ziehl-Nielsen staining. Also biopsy from the samples taken from the neck was just necrotic tissues with nonspecific inflammatory infiltrate and abscess formation. As the patient was suffering from severe respiratory distress, bronchoscopy was considered potentially harmful and therefore abandoned.

The patient was changed on Imipenem plus Vancomycine. BK sputum was positive for Mycobacterium tuberculosis The MTB isolate was fully susceptible to all first line antimycobacterial drugs. Also the cultures from sputum and neck were positive for M. tuberculosis. Three months after the first examination, at the follow up, patient was better under chemotherapy for TB, cervical spine immobilized and with a better pulmonary status-no dyspnea, just cough but rare. Also dysphagia, odynophagia were minor and the neck was healed. His general status was much better, he gain in weight, and BK in sputum was for the first time negative. In the end he was treated 18 month with antituberculous drugs till the cultures from the sputum were negative for M. tuberculosis. The cervical spine also healed with deformation so he required enforcement with cement injected in the cavities sequels from osteolysis of the vertebrae body

Case 3

A 43-year-old man presented with a history of neck pain and stiffness from at least 2 moth and from 4-5 days weakness in the upper and lower limbs worsen rapidly The neck pain was initially mild but later became severe with associated radicular pain to the left shoulder. There was history of weight loss but no fever or excessive night sweats. No antecedent history of trauma to the head and neck region. No history of urinary or fecal incontinence, cough, or breathlessness. He had dysphagia as well as odynophagia without dyspnea Physical examination revealed a young man pale, afebrile, anicteric with no significant peripheral lymphadenopathy, but confused, responded with difficulties to verbal stimuli. There was marked weight loss and fullness in the retropharyngeal area.

We ask for a neurological examination. Central nervous system examination revealed that she was conscious but desoriented. She had neck stiffness and limited neck movement. There was wasting of the small muscles of the hand and clawing of the fingers worse on the left. He was quadriparetic with gross muscle power. Muscle power was grades 3 and 5 on the left and right, respectively. he had global hyperreflexia with sustained ankle clonus. General examination on chest examination lung bilateral with apical flattening breath sounds and crepitation. Examination of the cardiovascular system and abdomen did not reveal any significant abnormalities.

Lab test: CBC anemia, neutropenia, lymphocytosis ESR-elevated, 72mm/hr (Westergreen method). PCR elevated -microbiology-sputum, BK direct, cultures -HIV screening negative IDR at PPD+ -QuantiFERON test + ImagisticS -X-ray chest showed reticulo-nodular shadows in both apices but worse on the left.

-X-ray cervical spine showed: Straightening of the normal cervical lordosis, collapse, and sclerosis of C3 and C4 vertebrae and obliteration of the C2/C3 and C3/C4 disc spaces. Other findings include widening of the prevertebral soft tissue from C1-C5 with resultant narrowing of the adjoining airway (oropharynx and hypopharynx). There was also sclerosis of the pedicles of C3/C4 vertebrae and osteophytic spurring of the antero-superior margin of C4. Lesions of the cervical spine cause neurologic deficit more frequent because the spinal canal in this region is small relative to the diameter of the cervical cord. The mechanism of neurologic symptoms in cervical spine TB include: local inflammation, tuberculous vasculitis and ischemia, spondylolisthesis of the vertebrae, abscess on the spinal cord or nerve root, and impingement of the discs. He was admitted in the ICU for rapid respiratory failure caused by paralyzed respiratory muscles intubated and put on mechanical ventilation. Tracheostomy was another must to do procedure plus drainage of the retropharyngeal space. Even of the good coverage with antibiotics -Meropenem plus Vancomycin, plus Isoniazid, Streptomycin, Ethambutol and Rifampin he developed a severe bronchopneumonia with multiresistant *Acinetobacter* -and after a long treatment including Colistin sulphate he was clean but very weak. He continued the treatment immobilized and ventilated, he was proposed for laminectomy but he died on surgery because of extremely late presentation.

Prognosis

Patients with Pott disease should be closely monitored to assess their response to therapy and compliance with medication. Directly observed therapy may be required. The development or progression of neurologic deficits, spinal deformity, or intractable pain should be considered evidence of poor therapeutic response. This raises the possibility of antimicrobial drug resistance, as well as the necessity for surgery. Because of the risk of deformity exacerbations, children with Pott disease should undergo long-term follow-up until their entire growth potential is completed. Older patients can also present with late-onset complications such as reactivation, instability, or deformity. Large epidural abscesses correlated with a poor prognosis in terms of recovery from neurological deficits.

Conclusion

MORB POTT's disease, an ancient and rare manifestation of extrapulmonary TB still exist. Due to the devastating consequences of a missed diagnosis, TB should be considered early in every case of spondylitis, intraspinal or paravertebral abscess. Alarm signals can be prolonged history of progressive

back pain, in a patient with pulmonary tuberculosis on a chest radiograph, or neck pain and non specific complaints such as weight loss and fever. The diagnosis must be sustained radiological and microbiological. Before the advent of chemotherapy in 1994, treatment was basically bed rest, but after the treatment with chemotherapy and surgery the outcome began to improve. Surgical treatment is considered in cases of severe spinal instability or progressive neurological symptoms with evidence of cord compression or deformation. Finally, the prognosis depends on many factors. It is better if there is partial cord compression neural complications are of short duration, early onset cord involvement neural complications developed slowly patient is young, and does not have any other disease. Actually, spinal TB is a great challenge to physicians because of the nonspecific and wide spectrum of clinical presentations that result in delay of diagnosis and the risk of significant potential morbidity and mortality due to several complications. Early diagnosis and treatment is the key to avoiding this long-term disability.

References

1. Adiego MI, Valles H, Castellote MA, Royo J, Millan J, et al. (1993) Cold retropharyngeal abscess associated with cervical vertebral tuberculosis. *Acta Otorrinolaringol Esp* 44(6): 471-473.
2. Agada FO, Sharma R, Makura ZG (2006) Atypical presentation of cutaneous tuberculosis and a retropharyngeal neck abscess. *Ear Nose Throat J* 85(1): 60-62.
3. Al Soub H (1996) Retropharyngeal abscess associated with tuberculosis of the cervical spine. *Tuber Lung Dis* 77(6): 563-565.
4. Attia M, Harnof S, Knoller N, Shacked I, Zibly Z, et al. (2004) Cervical Pott's disease presenting as a retropharyngeal abscess. *Isr Med Assoc J* 6(7): 438-439.
5. Al Mulhim FA, Ibrahim EM, El Hassan AY, Moharram HM (1995) Magnetic resonance imaging of tuberculous spondylitis. *Spine* 20: 2287-2292.
6. Bhargava SK, Gupta S (1990) Large retropharyngeal cold abscess in an adult with respiratory distress. *J Laryngol Otol* 104(2): 157-158.
7. Carroll N, Bain RJ, Tseung MH, Edwards RH (1989) Tuberculous retropharyngeal abscess producing respiratory obstruction. *Thorax* 44(7): 599-600.
8. Kostic Joksic SA (1953) Retropharyngeal abscess as unusual sequel of BCG vaccination. *Tuberkuloza* 5(1): 61-62.
9. Laretus VF (2000) Retropharyngeal lymph nodes tuberculous adenitis in adult masked as retropharyngeal abscess. *Vestn Otorinolaringol* 6: 34-35.
10. Lubben B, Tombach B, Rudack C (2004) Tubercular spondylitis with retropharyngeal abscess. *Hno* 52(9): 820-823.
11. Melchor Diaz MA, Domingo Carrasco C, Monge Jodra R, Marino Espuelas J, Ontanon Martin M (1993) Tuberculous retropharyngeal abscess in an HIV patient. Report of a case. *Acta Otorrinolaringol Esp* 44(5): 467-470.
12. Neumann JL, Schlueter DP (1974) Retropharyngeal abscess as the presenting feature of tuberculosis of the cervical spine. *Am Rev Respir Dis* 110(4): 508-511.
13. Oktem F, Guvenc MG, Yilmaz S, Edizer DT, Kara B (2006) Asymptomatic retropharyngeal abscess related to cervical Pott's disease. *Am J Otolaryngol* 27(4): 278-280.

14. Fang D, Leong JC, Fang HS (1983) Tuberculosis of the upper cervical spine. *J Bone Joint Surg Br* 65: 47-50.
15. Pollard BA, El-Beheiry H (1999) Pott's disease with unstable cervical spine, retropharyngeal cold abscess and progressive airway obstruction. *Can J Anaesth* 46(8): 772-775.
16. Stinson JM (1976) Tuberculosis of the cervical spine presenting as retropharyngeal abscess. *J Natl Med Assoc* 68: 494-495,542.
17. Thomas MD, Tierney PA, Samuel D, Patel KS (1995) Tuberculosis: An unusual cause of dysphagia. *Otolaryngol Head Neck Surg* 113(5): 644-650.
18. Gupta RK, Agarwal P, Rastagi H (1996) Problems in distinguishing spinal tuberculosis from neoplasia on MRI. *Neuroradiology* 38(1): S97-S104.
19. Pattison PR (1986) Pott's paraplegia: An account of the treatment of 89 consecutive patients. *Paraplegia* 24: 77-91.
20. Pott P (2002) The surgical works of Percivall Pott, F.R.S., surgeon to St. Bartholomew's Hospital, a new edition, with his last corrections. 1808. *Clin Orthop Relat Res* 398: 4-10.
21. Nerlich AG, Haas CJ, Zink A, Szeimies U, Hagedorn HG (1997) Molecular evidence for tuberculosis in an ancient Egyptian mummy. *Lancet* 350(9088): 1404.
22. Turgut M (2001) Spinal tuberculosis (Pott's disease): its clinical presentation, surgical management, and outcome. A survey study on 694 patients. *Neurosurg Rev* 24(1): 8-13.
23. Park DW, Shim DM, Lee JS, Lee JB, Chun BC, et al. (2007) Outcome and management of spinal tuberculosis according to the severity of disease: *Spine* 8: E130-E135.
24. Nussbaum ES, Rockswold GL, Bergman TA, Erickson DL, Seljeskog EL (1995) Spinal tuberculosis: a diagnostic and management challenge. *J Neurosurg* 83(2): 243-247.
25. Le Page L, Feydy A, Rillardon L, Zarrouk V, Guigui P, et al. (2006) Spinal tuberculosis: a longitudinal study with clinical, laboratory, and imaging outcomes. *Semin Arthritis Rheum* 36(2): 124-129.
26. Joseffer SS, Cooper PR (2005) Modern imaging of spinal tuberculosis. *J Neurosurg Spine* 2(2): 145-150.
27. Pertuiset E, Beaudreuil J, Liote F, Meyer O, Dryll A, et al. (1999) Spinal tuberculosis in adults. A study of 103 cases in a developed country, 1980-1994. *Medicine (Baltimore)* 78(5): 309-320.
28. Heyer CM, Al-Hadari A (2008) Effectiveness of CT-guided percutaneous biopsies of the spine: an analysis of 202 examinations. *Acad Radiol* 15(7): 901-911.



This work is licensed under Creative Commons Attribution 4.0 License
DOI: [10.19080/GJO.2018.13.555861](https://doi.org/10.19080/GJO.2018.13.555861)

Your next submission with Juniper Publishers will reach you the below assets

- Quality Editorial service
- Swift Peer Review
- Reprints availability
- E-prints Service
- Manuscript Podcast for convenient understanding
- Global attainment for your research
- Manuscript accessibility in different formats
(Pdf, E-pub, Full Text, Audio)
- Unceasing customer service

Track the below URL for one-step submission
<https://juniperpublishers.com/online-submission.php>