

# Nitroglycerine-Responsive Ischemic Trigeminal Premature Ventricular Contractions in Stented Myocardial Infarction with Hypertensive Crises and Transient Ischemic Attack



Yasser Mohammed Hassanain Elsayed\*

Department of Critical Care Unit, Kafr El-Bateekh Central Hospital, Egyptian Ministry of Health (MOH), Egypt

Submission: September 11, 2021; Published: November 09, 2021

\*Corresponding author: Yasser Mohammed Hassanain Elsayed, Department of Critical Care Unit, Kafr El-Bateekh Central Hospital, Egyptian Ministry of Health (MOH), Egypt

## Abstract

**Rationale:** Nitroglycerin (NTG) is a definite usually prescribed short-acting anti-anginal and antihypertensive medication. But historically, it is an unknown antiarrhythmic drug. Nitroglycerin is attenuating anginal symptoms in ischemic heart disease (IHD). Ischemic heart disease is a reasonable remarkable cause of premature ventricular contractions (PVCs) and trigeminy. Simultaneous co-presence of both the stented myocardial infarction with premature ventricular contractions trigeminy is extremely rare.

**Patient concerns:** An elderly, heavy cigarette smoker, the male patient presented to emergency department with trigeminal premature ventricular contractions with hypertensive crises and transient ischemic attack (TIA) in stented myocardial infarction.

**Diagnosis:** Trigeminal premature ventricular contractions with hypertensive crises and transient ischemic attack in stented myocardial infarction.

**Interventions:** Nitroglycerin intravenous infusion, critical care monitoring, electrocardiography, and percutaneous transluminal coronary angioplasty, and echocardiography.

**Lessons:** Clearing the efficacious role of nitroglycerin as an antiarrhythmic medication in ischemic trigeminal premature ventricular contractions.

**Outcomes:** Dramatic termination of trigeminal premature ventricular contractions with nitroglycerin intravenous infusion strengthen its antiarrhythmic effect. The presence of myocardial infarction, hypertensive crises, transient ischemic attack, elderly, cigarette smoking, and premature ventricular contractions are prognostic factors for the severity of structural heart disease.

**Keywords:** Nitroglycerine; Premature ventricular contractions; Trigeminy; Myocardial infarction; Stents percutaneous transluminal coronary angioplasty

**Abbreviations:** ECG: Electrocardiograph; HTN: Hypertension; ICU: Intensive Care Unit; IHD: Ischemic Heart Disease; MI: Myocardial Infarction; IVI: Intravenous Infusion; NTG: Nitroglycerin; PTCA: Percutaneous Transluminal Coronary Angioplasty; PvcS: Premature Ventricular Contractions; SCD: Sudden Cardiac Death; SHD: Structural Heart Disease; TIA: Transient Ischemic Attack

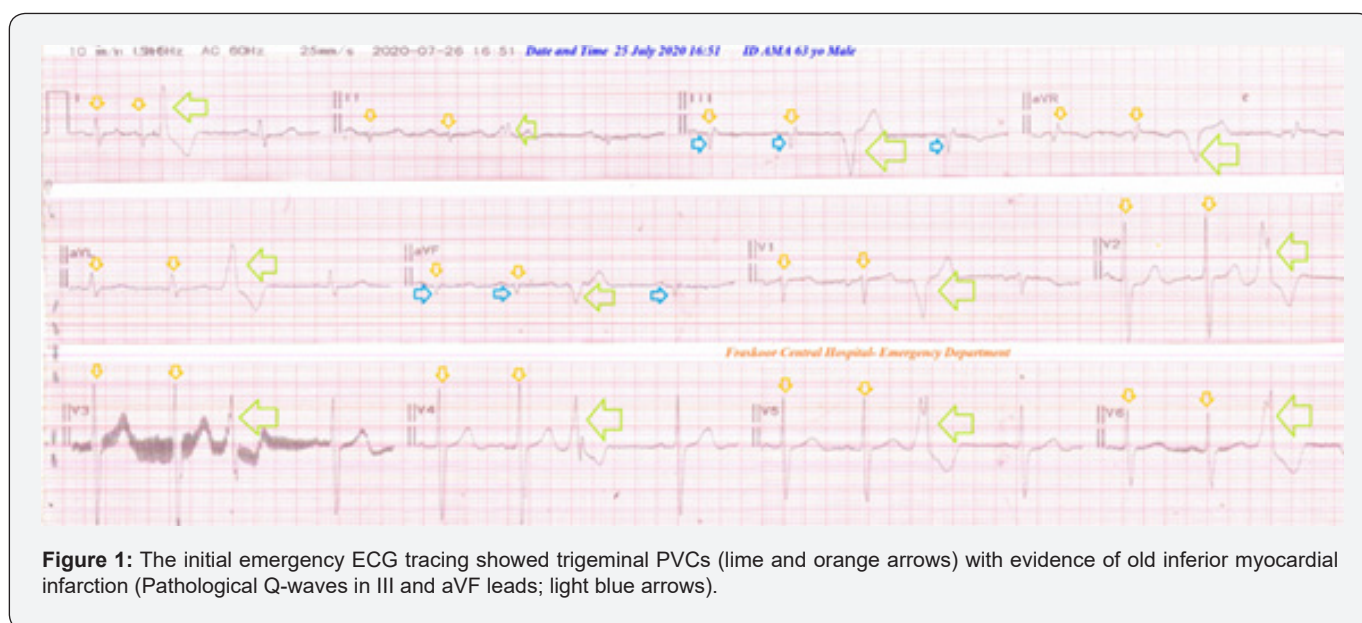
## Introduction

Nitroglycerin (NTG) is the ancient and most frequently administered short-acting anti-anginal medication. Historically, NTG had entered clinical use since 1879. So, the need to educate both patients and health care providers on the various benefits of short-acting nitrates is advisable [1]. Nitrates have a vasodilator

effect with predominant venous action on the large capacitance vessels. They also stimulate collateral coronary circulation, cause augmentation of aortic compliance with conductance, and accentuate the blood flow to myocardium ischemic areas (MIA). Besides, nitrates directly attenuate anginal symptoms by their

effects on the coronary arteries, coronary collateral circulation, aortic compliance and conductance, and blood flow to MIA [2]. Short-acting nitrates are adventurous in acute ischemic heart disease (IHD) [3]. However, NTG is a clinically effective therapy for this condition, but the actual mechanism of action is still unknown [4]. Indeed, clinical observations suggesting that NTG may suppress PVCs during acute IHD. But the studies were undertaken to assess the effect of NTG on the incidence of PVCs in patients with acute MI [5]. Nitroglycerin administration was accompanied by a significantly more rapid decrease in ventricular arrhythmias within 6 hours post-recording and the number of PVCs had reduced to 39% of the baseline value [6]. Trigeminal PVCs are meaning a cardiac arrhythmia in which every third beat is a ventricular premature complex (extrasystole) or two sinus beats between extrasystoles [7]. PVC is a type of arrhythmia characterized by premature heart contractions originating in one of the ventricles<sup>7</sup>. PVCs are early depolarization of the myocardium originating in the ventricle [7] caused by an electrical impulse or ectopic rhythm from any part of the ventricles, including the ventricular septum before the sinoatrial impulse has reached the ventricles. PVCs in absent structural heart disease (SHD) are safe once the risk factors excluded [8]. PVCs with SHD is considered a hallmark of sudden cardiac death (SCD) [8]. Cohort studies revealed that PVCs are accompanied by increased IHD events and SCD [9]. Because PVCs with established IHD may be viewed as a marker of disease severity

or as an endpoint in the natural history of the disease process [8]. The presence of PVCs in patients of IHD is associated with a poor prognosis [8]. Hypertensive crises (76% urgencies and 24% emergencies) represented 3% of all the patient visits, but 27% of all medical emergencies [10]. Hypertensive crisis is defined as levels of systolic blood pressure (SBP) >180 mmHg and/or levels of diastolic blood pressure (DBP) >120 mmHg [11]. Depending on whether there is damage to vital organs or not, we can distinguish between hypertensive emergency (HE) and hypertensive urgency (HU) [11] Hypertensive emergencies occur in up to 2% of patients with systemic hypertension (HTN) [10]. HEs are life-threatening conditions because their outcome is complicated by acute damage to vital organs, and can be presented with neurological, renal, cardiovascular, microangiopathic, and obstetric complications [11]. HEs include hypertensive encephalopathy, hypertensive acute LV relaxation associated with acute myocardial infarction (MI) or unstable angina (UA), aortic dissection, subarachnoid hemorrhage (SAH), ischemic stroke (CVA), and severe pre-eclampsia or eclampsia [11]. HE is a situation with a severe increase in blood pressure without progressive dysfunction of vital organs. The most frequent symptoms are headache, dyspnea, nausea, vomiting, nasal bleeding, and cleared anxiety [11]. Prompt controlling of HTN is required only in patients with acute end-organ damage [10].



**Figure 1:** The initial emergency ECG tracing showed trigeminal PVCs (lime and orange arrows) with evidence of old inferior myocardial infarction (Pathological Q-waves in III and aVF leads; light blue arrows).

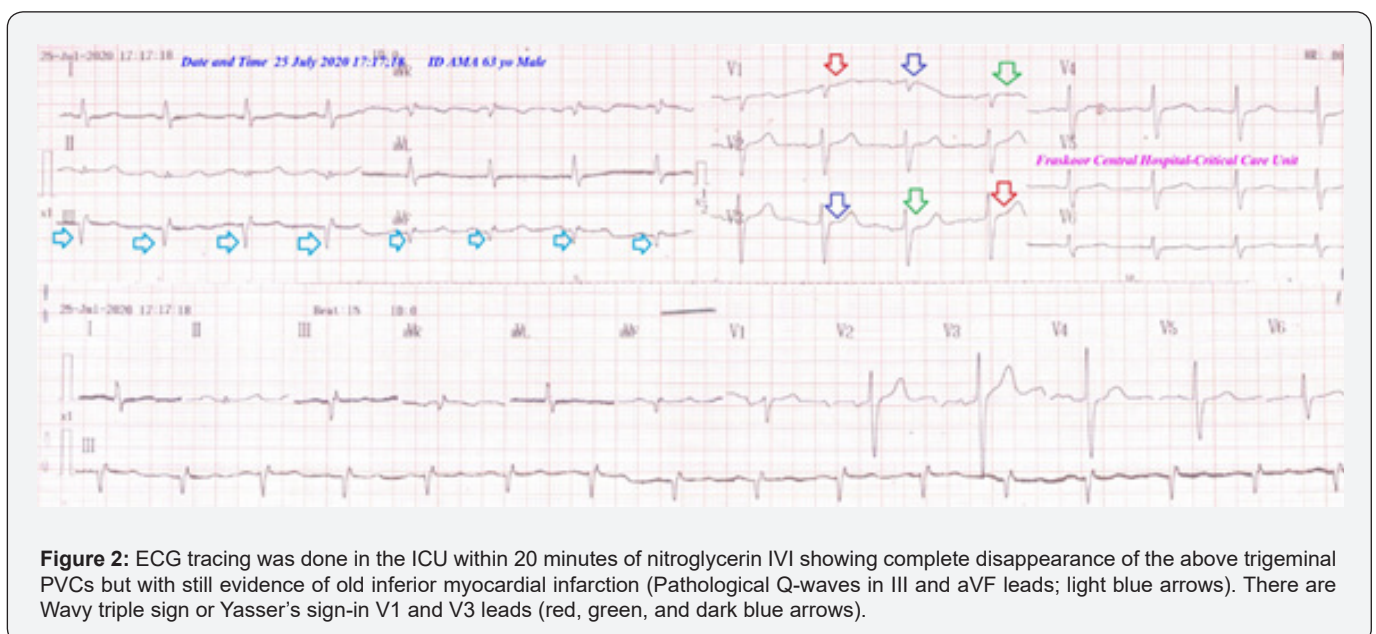
## Case Presentation

A 63-year-old, heavy cigarette smoker, Egyptian farmer, the male patient presented in the emergency department with dizziness, palpitation, and left-side hemiparesis. There are associated headaches, slurred speech, and right-side facial deviation. He is a heavy cigarette smoker (20 cigarettes for about 17 years). The patient gave a history of old MI and HTN. The

patient had a history of inferior MI with undergone percutaneous transluminal coronary angioplasty (PTCA) with two drug-eluting stents (DES) implantation 3 years ago. Upon general physical examination, generally, the patient was anxious, conscious, alert, and oriented with the place and time. His GCS was 15. The heart rate was irregular; 80 bpm, the blood pressure; 190/130 mmHg, the respiratory rate 20 bpm, the temperature; 36.5 °C, and the pulse oximeter of O<sub>2</sub> saturation; 96%. Left side hemiparesis,

slurred speech, and right-side facial deviation were noted. No more relevant clinical data were noted during the clinical examination. The patient was admitted to the intensive care unit (ICU). The initial emergency ECG tracing showed trigeminal PVCs with evidence of old inferior myocardial infarction (Pathological Q-waves in III and aVF leads). (Figure 1). The physician had started giving nitroglycerin IVI in a very low dose (10 mg/50 ml solvent, 5 ug/min). Within 20 minutes of nitroglycerin IVI at the ICU, the second tracing showed complete disappearance of the above trigeminal PVCs but with still evidence of old inferior myocardial infarction (Pathological Q-waves in III and aVF leads). There is a Wavy triple sign or Yasser's sign-in V1 and V3 leads (Figure 2). The requested workup was Electrolyte's profile show: Na+:144 mmol/l, K+: 5.1 mmol/L, ICa++:1.09 mmol/L, Hb: 16.5 gm/dl,

Random blood glucose: 156 mg/dl. The troponin test was negative (below the normal level). Thyroid function tests were normal. The echocardiographic report showed evidence of IHD with inferior wall hypokinesia with normal ejection fraction (59%). Immediate brain CT and repeated imaging within 48 hours later were normal. Neurological manifestation gradually disappeared with blood pressure normalization with about 60 minutes of nitroglycerin IVI. The clinical and electrocardiographic improvement had happened. Trigeminal premature ventricular contractions with hypertensive crises and transient ischemic attack in stented myocardial infarction was n. The patient continued on discharge on nitroglycerin retard (2.5 capsules; BID), aspirin oral tablets (75 mg, OD), and clopidogrel (75 mg, OD) with advised future cardiovascular and neurological follow-up.



## Discussion

### Overview

A 63-year-old married, farmer, smoker, Egyptian male patient was admitted to the ICU with trigeminal PVCs with hypertensive crises and transient ischemic attack (TIA) in stented myocardial infarction (MI).

a) The primary objective for my case study was the presence of a patient who presented with trigeminal PVCs with hypertensive crises and transient ischemic attack (TIA) in stented MI at the ICU.

b) The secondary objective for my case study was the question of: How did you manage the case at home?

a) There is an existence of acute regular trigeminal PVCs.

b) There is evidence of old inferior MI (Pathological Q-waves in III and aVF leads).

c) A SBP of 190 mmHg and the DBP of 130 mmHg with TIA is indicating a hypertensive emergency.

d) The presence of attack of TIA post-hypertensive emergency is reasonable.

e) The acute improvement of TIA within 60 minutes post-nitroglycerin was expected.

f) The dramatic response of regular ischemic trigeminal PVCs after use nitroglycerin IVI is amazing.

g) Cerebral hemorrhage and ischemic stroke are the most possible differential diagnosis for the current case study.

h) I can't compare the current case with similar conditions. There are no similar or known cases with the same management for near comparison.

i) The only limitations of the current study are the absence of neurologist consultation at the time of the TIA.

## Conclusion and Recommendations

Dramatic termination of trigeminal premature ventricular contractions with nitroglycerin intravenous infusion strengthens its antiarrhythmic effect. The presence of myocardial infarction, hypertensive crises, transient ischemic attack, elderly, cigarette smoking, and premature ventricular contractions are prognostic factors for the severity of structural heart disease. Widening the research for clearing the antiarrhythmic effect of nitroglycerin and nitrates will be recommended in further studies.

## Acknowledgment

I wish to thank the team of nurses in the critical care unit in Faraskor Central Hospital who make extra-ECG copies for helping me. Also, I want to thank my wife to save time and improving the conditions for supporting me.

## References

1. Elsayed MH (2017) Test the antiarrhythmic effect of intravenous nitroglycerine on ischemic Premature Ventricular Contractions Bigeminy. *The Egyptian Journal of Critical Care Medicine* 5(3): 101-103.
2. Boden WE, Padala SK, Cabral KP, Buschmann IR, Sidhu MS (2015) Role of short-acting nitroglycerin in the management of ischemic heart disease. *Drug Des Devel Ther* 9: 4793-4805.
3. Giuseppe C, Paul J, Hans-Ulrich I (2015) Use of nitrates in ischemic heart disease. *Expert Opin Pharmacother* 16(11): 1567-1572.
4. James A Miner, C Richard Conti (1978) Topical Nitroglycerin for Ischemic Heart Disease. *JAMA* 239(20): 2166-2167.
5. SB Knoebel, S Rasmussen, RJ Noble, MJ Mihalick (1975) Nitroglycerin and premature ventricular complexes in myocardial infarction. *Br Heart J* 37(10): 1064-1068.
6. Wulf Dirk Bussmann, Klaus Neumann, Martin Kaltenbach (1984) Effects of intravenous nitroglycerin on ventricular ectopic beats in acute myocardial infarction. *Am Heart J* 107(5): 940-944.
7. Elsayed YMH (2019) Test the Termination of Regular Ischemic Premature Ventricular Contractions Variants with Nitroglycerin; A new Therapeutic and Diagnostic Test; Retrospective Observational Study (14-Report Cases). *Emerg Med Trauma Care J EMTJ*-100004.
8. Elsayed YMH (2019) Premature Ventricular Contractions from Benign to Seriousness - A Narrative Updating Review. *Archives of Emergency Medicine and Intensive Care* 2(2): 1-21.
9. Ofoma U, He F, Shaffer ML, Naccarelli GV, Liao D (2012) Premature cardiac contractions and risk of incident ischemic stroke. *J Am Heart Assoc* 1(5): e002519.
10. Paul E Marik, Racquel Rivera (2011) Hypertensive emergencies: an update. *Curr Opin Crit Care* 17: 569-580.
11. Sabina Salkic, Olivera Batic-Mujanovic, Farid Ljuca, Selmira Brkic (2014) Clinical Presentation of Hypertensive Crises in Emergency Medical Services. *Mater Sociomed* 26(1): 12-16.



This work is licensed under Creative Commons Attribution 4.0 License  
DOI: [10.19080/GJPPS.2021.09.555755](https://doi.org/10.19080/GJPPS.2021.09.555755)

### Your next submission with Juniper Publishers will reach you the below assets

- Quality Editorial service
- Swift Peer Review
- Reprints availability
- E-prints Service
- Manuscript Podcast for convenient understanding
- Global attainment for your research
- Manuscript accessibility in different formats  
( Pdf, E-pub, Full Text, Audio )
- Unceasing customer service

### Track the below URL for one-step submission

<https://juniperpublishers.com/online-submission.php>