

# Squamous Cell Carcinoma of the Breast in a Developing Community

Wilson IB Onuigbo\*

Department of Pathology, Medical Foundation and Clinic, Nigeria

Submission: November 14, 2016; Published: January 04, 2017

\*Corresponding author: Wilson IB Onuigbo, Department of Pathology, Medical Foundation and Clinic, 8, Nsukka Lane, Enugu 400001, Nigeria, Email: wilson.onuigbo@gmail.com

## Abstract

Squamous cell carcinoma of the breast is so rare that single cases are usually reported, the squamous appearance being classical. To augment the few examples reported from India, Italy, and USA, this report is from Nigeria. It was facilitated on ground that the establishment of a histopathology data pool can promote epidemiological analysis. Such a data pool established by the Government of the Eastern Region of Nigeria at the capital city, Enugu, provided the opportunity to obtain 4 cases from among the ethnic group called the Ibos or Igbos. It is important to add these examples to the world literature.

**Keywords:** Breast; Cancer; Squamous cells; Ibos/Igbos; Nigeria

## Introduction

Squamous cell carcinoma is a rarity all over the world. From India, 3 cases were reported in women aged 47 years, 58 years and 72 years respectively [1-3]. The Italian patient was aged 54 years [4], while from USA the figure was 58 years [5]. In the present paper concerning the Ibos or Igbos [6], who are domiciled mostly in the South-eastern Region of Nigeria, 4 examples are documented.

**Table 1:** Data on squamous cell carcinomas of the breast.

S/No	Lab No	Initial	Age	Side	Diagnosis	City	Doctor
1	B 120/72	NC	40	R	Carcinoma	Enugu	Nwankwo
2	H 104/72	NB	34	R	Lump	Enugu	Nwozo
3	UH 803//87	NL	45	-	Carcinoma	Enugu	Udekwo
4	UH 215/89	ND	30	L	Carcinoma	Aba	Iwuagwu

## Results

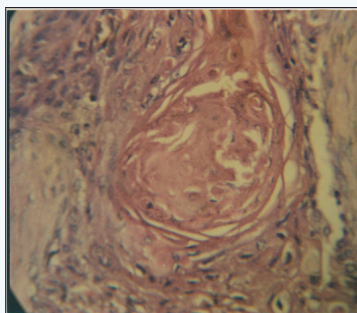
The Igbo cohort is aged from 30 to 45 years (average 37.3 years). On the contrary, the international range of 47 to 72 years

## Investigation

Workers in Birmingham (UK) promoted the idea that the establishment of a histopathology data pool is a good way to facilitate epidemiological analysis [7]. Accordingly, the one established in Enugu, the capital of the Eastern Region, is the source of the present paper which is tabulated hereunder (Table 1).

averaged 57.8 years. This difference is open to research. Most patients were attended to in Enugu, while a single patient was referred from faraway Aba. Interestingly, individual doctors forwarded the specimens.

## Discussion



**Figure 1:** Squamous cell carcinoma of the breast showing the typical cell nest.

A problem has arisen. It was described thus [8]: “Histogenesis is controversial as to whether a pure form of squamous cell carcinoma exists or if these malignancies represent an extreme squamous metaplasia within an adenocarcinoma.” Incidentally, this particular group avowed that the median age recorded was 52 years. In contrast, the present group has the average of 37.3 years. This may well be of epidemiological interest for future research. (Figure 1) gives an authentic representation of the

squamous cell carcinoma. It characteristically featured in the present cohort.

## References

1. Pramesh CS, Chaturvedi P, Saklani AP, Badwe RA (2001) Squamous cell carcinoma of the breast. *J Postgrad Med* 47(4): 270-271.
2. Mitra B, Pal M, Debnath S, Paul B, Saha TN, et al. (2011) Primary squamous cell carcinoma of the breast with ipsilateral axillary lymph node metastasis: An unusual case. *Int J Surg Case Rep* 2(7): 194-197.
3. Badge SA, Gangane NM, Shivkumar VB, Sharma SM (2014) Primary squamous cell carcinoma of the breast. *Int J Appl Basic Med Res* 4(1): 53-55.
4. Murialdo R, Boy D, Musizzano Y, Tixi L, Murelli F, et al. (2009) Squamous cell carcinoma of the breast: a case report. *Cases J* 2: 7336.
5. Zomerlei TA, Samarghandi A, Terando A (2015) Primary squamous cell carcinoma arising from a breast implant capsule. *Plast Reconstr Surg* 3(12): e586.
6. Basden GT (1966) *Niger Ibos*. Cass, London, UK.
7. Macartney JC, Rollaston TP, Codling BW (1980) Use of a histopathology data pool for epidemiological analysis. *J Clin Pathol* 33(4): 351-353.
8. Karma HT, Gadgil PA, Chaware SA, Kanade UA (2011) Acantholytic variant of squamous cell carcinoma of the breast: a rare case report. *Eccancermedicalscience* 5: 214.



This work is licensed under Creative Commons Attribution 4.0 License  
DOI: [10.19080/IJCSMB.2017.01.555565](https://doi.org/10.19080/IJCSMB.2017.01.555565)

### Your next submission with Juniper Publishers will reach you the below assets

- Quality Editorial service
- Swift Peer Review
- Reprints availability
- E-prints Service
- Manuscript Podcast for convenient understanding
- Global attainment for your research
- Manuscript accessibility in different formats  
( Pdf, E-pub, Full Text, Audio)
- Unceasing customer service

Track the below URL for one-step submission  
<https://juniperpublishers.com/online-submission.php>