

**Case Series**

Volume 12 Issue 5 - June 2023  
DOI: 10.19080/JAICM.2023.12.555846

**J Anest & Inten Care Med**

Copyright © All rights are reserved by Prakash Shastri

# COVID-19 Associated Mucormycosis- a Retrospective Case Series from A Tertiary Centre



**Prakash Shastri<sup>1\*</sup>, Salil Bhargava MD<sup>2</sup>, Pallav Gupta MD<sup>3</sup> and Shreya Singh MD<sup>4</sup>**

<sup>1</sup>Senior Consultant & Vice Chairman, Sir Gangaram Hospital, New Delhi India

<sup>2</sup>Senior Consultant, Department of Radiodiagnosis, Sir Gangaram Hospital, New Delhi India

<sup>3</sup>Senior Consultant, Department of Histopathology, Sir Gangaram Hospital New Delhi, India

<sup>4</sup>Senior Resident, Department of Microbiology, Post Graduate Institute of Medical Education & Research, Chandigarh, India

**Submission:** June 12, 2023; **Published:** July 03, 2023

**\*Corresponding author:** Prakash Shastri, Senior Consultant & Vice Chairman, Sir Gangaram Hospital, New Delhi India, Tel: +91 9810937295; Email: prakashshastri@live.in

## Abstract

Mucormycosis is caused by an angio-invasive mould of the order Mucorales. The predisposing factors includes diabetes, haematological malignancy, stem cell transplants, and those receiving immunosuppressive drugs for auto-immune conditions. We report a case series of 19 cases which were diagnosed after a median of 23 days after infection with the novel corona disease (COVID 19 reported at our tertiary care centre with emphasis on the radiological findings, and its bearing on the management and outcomes of these cases.

**Keywords:** Angio-Invasive Mould; Haematological Malignancy; Auto-Immune Conditions; Sabaroud's Dextrose Agar; Histopathology; Mycology

## Main Text

The presence of secondary infections in a large population of patients afflicted with the emerging variants of the novel corona virus (SARS CoV-2) has placed a major burden on public health services. Recently, several centres from India have reported a surge in the cases of mucormycosis in patients with COVID-19 disease [1].

Mucormycosis is caused by an angio-invasive mould of the order Mucorales. Its prevalence is estimated to be 140 cases per million population in India [2]. Diabetes is the most common predisposing factor in India, while in the developed world it is seen more frequently in patients with haematological malignancy, stem cell transplants, and those receiving immunosuppressive drugs for auto-immune conditions [3].

A multicentre cohort study from India reported a two-fold rise in the prevalence of mucormycosis between September-December 2020 compared to the same time in 2019 with a case fatality rate of 38.3% and 45.7% at 6 and 12 weeks, respectively [4]. Despite the rise in cases of covid associated mucormycosis (CAM), systematic studies identifying the magnitude, risk factors, and outcome of CAM are still lacking.

## Methods

### Study Design:

A retrospective observational analysis of all cases of proven mucormycosis among patients infected with COVID-19 presenting during 1st September 2020 to 31st December 2020 was performed. The Institute Ethics Committee approved the study protocol (Reference number: EC/02/21/1827) and a consent waiver was allowed due to retrospective analysis of anonymized patient data.

### Patient selection

Mucormycosis was defined as per the European Confederation of Medical Mycology in cooperation with the Mycoses Study Group Education and Research Consortium (ECMM MSG) [5]. All patients defined as CAM had a positive real time-polymerase chain reaction (RT-PCR) for SARS-CoV-2 within the previous two months of the diagnosis of mucormycosis. The included patients received treatment for COVID-19 and mucormycosis as per the institutional protocols.

**Microbiological methods:**

Biopsy specimens from affected sites were subjected to wet mount microscopy using 10 % potassium hydroxide (KOH), histopathology and fungal culture on Sabaroud’s dextrose agar. Molecular detection was carried out by direct DNA extraction and amplification using Mucorales specific primers as previously described [6].

**Data collection:**

The demographic characteristics (age and gender), risk factors (diabetes mellitus, hematological malignancy, renal transplantation, and others), days to the diagnosis of mucormycosis after COVID-19 (positive RTPCR), site of involvement, diagnosis of mucormycosis (microscopy, culture,), treatment details (antifungal therapy, surgery), and outcomes in terms of survival at 6 and 12 weeks was recorded. We also collected information on

the treatment received during COVID-19 episode, (glucocorticoids, tocilizumab, and others). All patients who left the hospital against medical advice were categorized under mortality for analysis (worst-case scenario analysis). Descriptive analysis were reported as frequencies, percentages; medians and range; or means and standard deviation (SD), as appropriate.

**Results**

We collected information of a total of 19 patients with CAM. The median age of the patients was 55 years (range 37-80). Majority of the patients were male (n=17). The diagnosis of mucormycosis was made after a median of 23 days (range 6-58) after positive RT-PCR for SARS CoV-2. The prevalence of CAM (as calculated by the total number of cases of CAM divided by the number of COVID-19 cases treated) was 5.47 per 1000 COVID-19 patients during the study period.

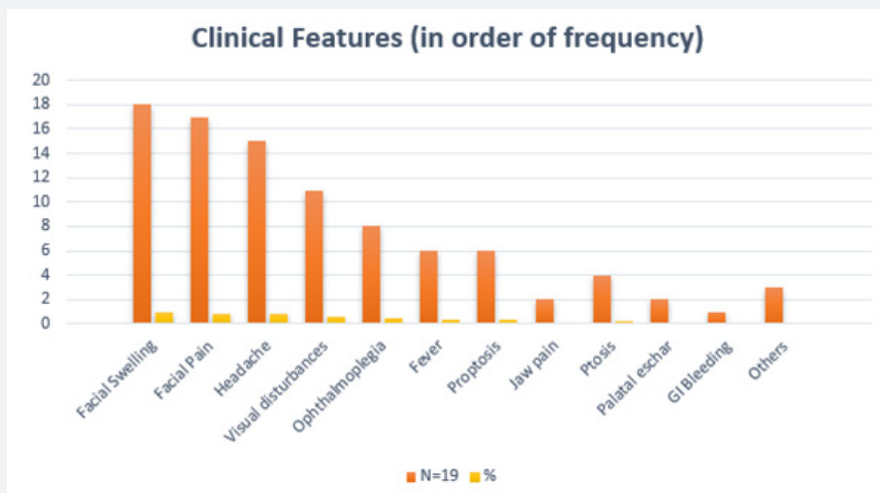


Figure 1: Clinical presentation at the onset of the COVID-19 associated Mucormycosis.

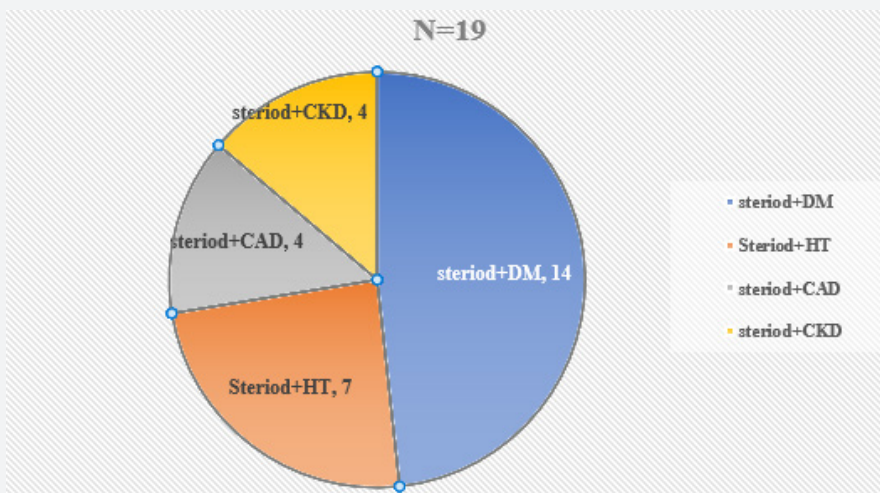
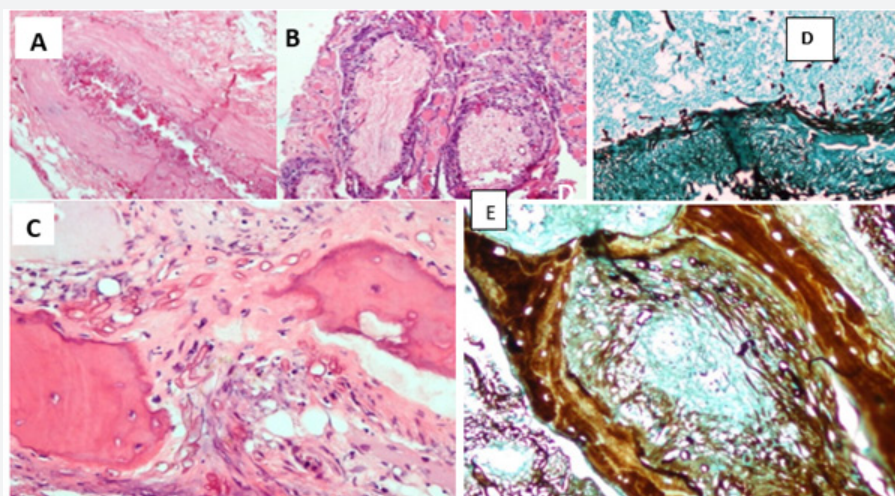


Figure 2: Risk factors among CAM patients.

The clinical features of the patients at the onset of the CAM are presented in (Figure 1). Majority (n=15, 78.9%) of the patients were known cases of diabetes mellitus (DM), with poorly controlled blood glucose levels Median glycosylated haemoglobin (HbA1c%) was 8.4 (range 6 -13.4). Among other risk factors, steroids therapy during COVID was most common (n=18, 94.7%), followed by hypertension (n=7, 38.8), coronary artery disease, chronic kidney disease (CKD) (n=4, 22.2%) and chronic liver disease (n=1, 5.2%). The risk factors observed among CAM patients are presented in (Figure 2). Concomitant steroid administration with diabetes was reported in 74% (n=14) patients followed by steroid with hypertension (n=7, 37%). The median steroid dosage was 2400 mg

prednisolone equivalent (range 840-12500 mg) and the median duration of steroid therapy was 14 days (range 6-29 days). Only one patient was in the state of diabetic ketoacidosis. No patients had malignancy or were recipients of solid organ/ bone marrow transplant.

Rhino orbital mucormycosis (ROM) was the most common form (n=9, 47.3%) and the most common symptom observed was facial swelling and facial pain in 18 (94.7%) and 17 (89.4%) patients, respectively (Figure 3). Representative images of contrast enhanced Magnetic resonance imaging (MRI) findings in patients with CAM are provided in (Figure 4).



**Figure 3:** Histopathology of the nasal biopsy or debridement tissue us H & E, Grocott's (A)H&E, 200X: angioinvasion; (B) H&E, 200X: perineural & intraneural invasion (C) H&E, 200X: bone destruction by Mucor. (D, E): GROCOTT's stain highlighting the angioinvasion, perineural and intraneural invasion and bone destruction as A, B, C respectively.

The diagnosis of mucormycosis was confirmed by histopathology in all 19 patients (Figure 5). Direct microscopic examination using 10% KOH was positive in 14 (73.6%) patients and Mucorales were recovered from culture in 5 (26.3%) patients. These included *Rhizopus arrhizus* (n=3), *Lichtheimia corymbifera* (n=1) and *Apophysomyces elegans* (n=1). Representative images of mycological findings are shown in (Figure 6).

Liposomal Amphotericin B (L-amB) was instituted in all the 19 patients. Of these 19 patients 12 (63.1%) patients received posaconazole along with L-amB. Isavuconazole was instituted in only one patient in combination with L-amB. Surgical endoscopic debridement was done in 17 patients. Video assisted thorascopic surgery (VATS) decortication was done in one patient with pulmonary involvement. Exenteration of the eye was done in three (15.7%) patients for MRI images of the patient - Case No 1). Majority (15, 73.6%) of the patients improved and were discharged, three patients died while one patient left against medical advice, resulting in 21.05% (4/19) mortality in this cohort. The 15 surviving patients were alive at 6 and 12 weeks follow up.

## Discussion

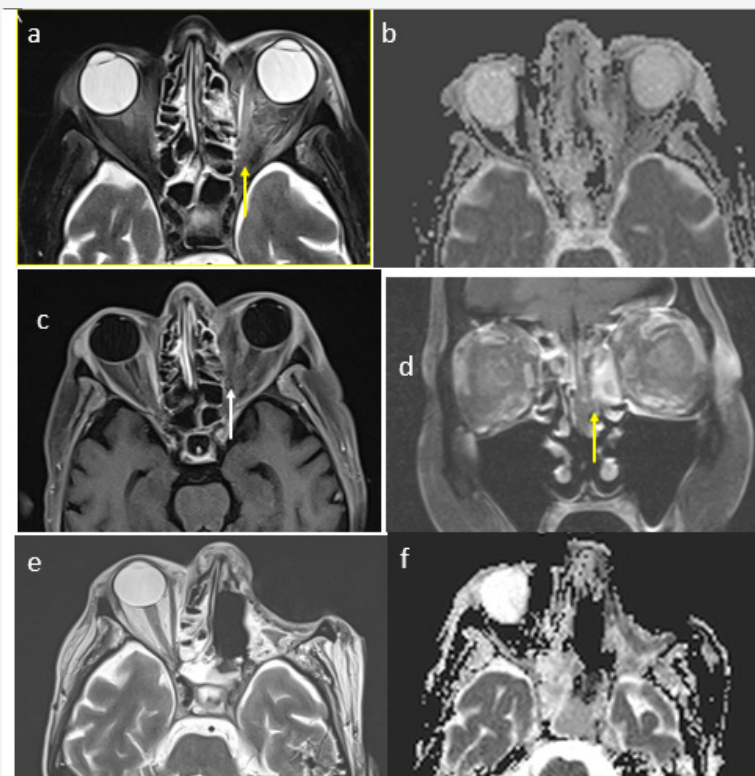
In this study we describe the clinical presentation, risk factors, management approach and outcomes of patients with CAM presenting at our tertiary care centre. The prevalence of CAM was 5.47 per 1000 Covid patients. Majority of patients were diabetic and steroid therapy had worsened their blood sugar control. Early surgical intervention was made possible because of coordination with microbiology and early imaging.

Diabetes has been reported as a risk factor for mucormycosis in 73.5% of cases in India [7]. In the present series, the presence of diabetes and steroid therapy were observed in the majority of cases.

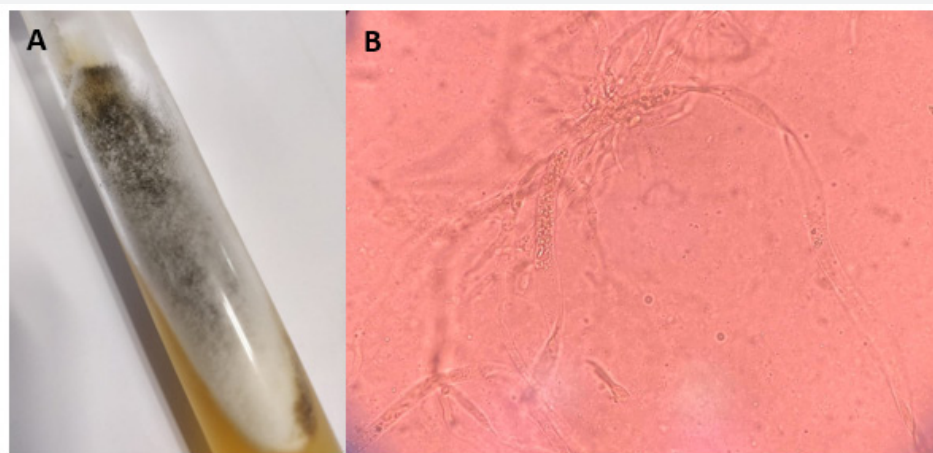
Rhino orbital mucormycosis is the most common clinical presentations,[3] and this trend has been observed in the present series. Infection rapidly spreads to the orbit with extension along the nasolacrimal duct, medial orbital wall or from the ethmoid sinus. In the brain, the spread occurs through the orbital apex, traversing vessels or the cribiform plate of ethmoid bone [8]. The fungus adheres to the internal elastic lamina of the blood

vessels causing thrombosis, resulting in ischemia and necrosis of tissues [9] *R. arrhizus* is the most commonly implicated agent in mucormycosis, particularly in ROM as this has been observed even

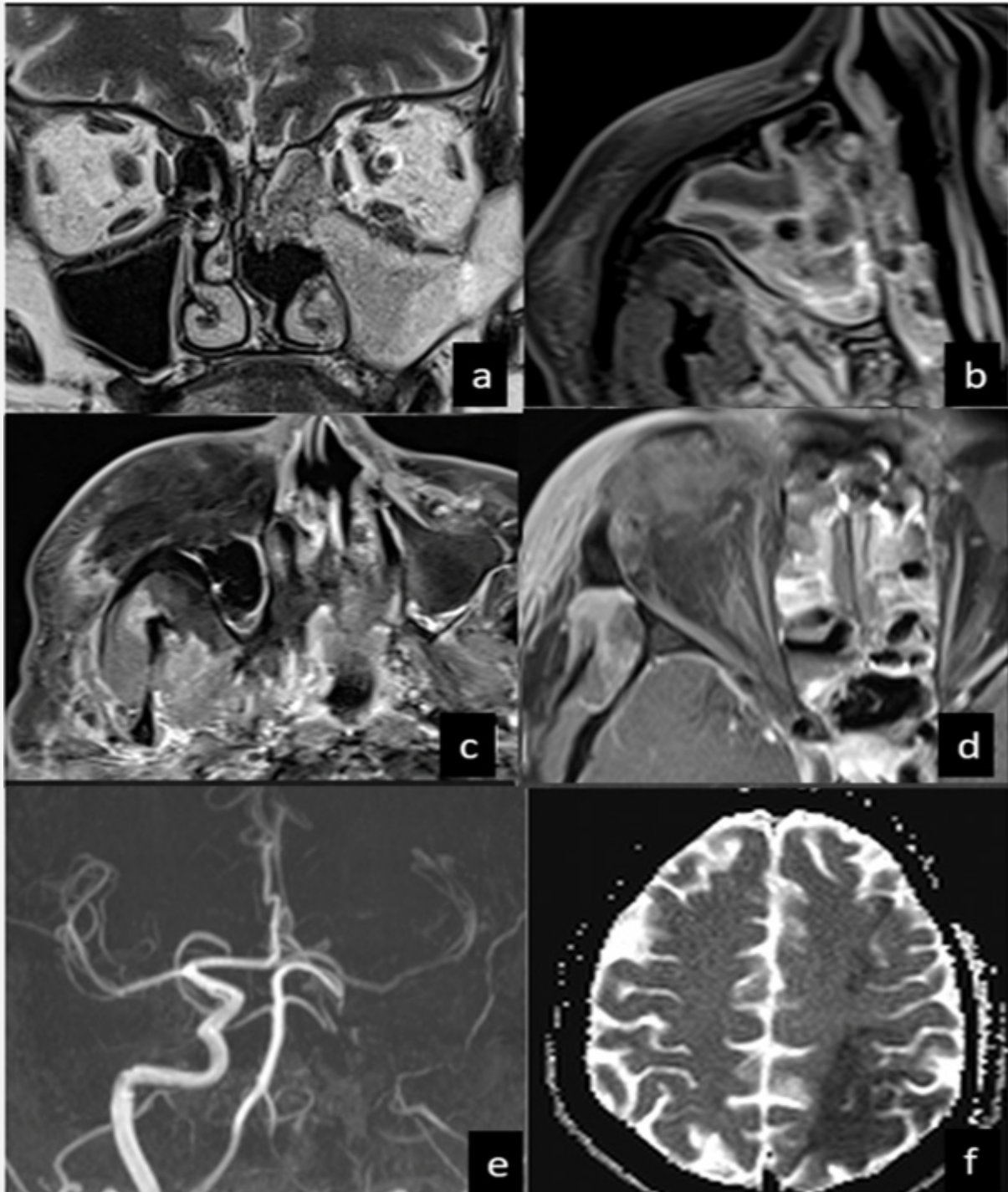
among cases of CAM both in the present study and other reports [3].



**Figure 4** (a, b, c, d, e, f): a) T2W Fat suppressed axial MR image showing increased signal intensity in the extraconal and intraconal tissues of the left orbit extending up to the orbital apex. b) ADC map of the diffusion weighted imaging showing restriction within the areas of left orbit. c) Axial T1W fat suppressed post contrast image showing non enhancement of the extraocular muscles on the left side suggestive of myonecrosis with predominant involvement of the left medial rectus muscle (white arrow) Yellow asterisk denotes normally enhancing right medial rectus muscle. d) Non enhancement of the left middle turbinate with thickening suggestive of positive Black Turbinate sign. e & f) s T2W and ADC Map of diffusion weighted image showing post exenteration changes in the left orbit and post ethmoidectomy changes in the left orbit.



**Figure 5:** A) Culture showing cottony Grey black appearance Identified by Malditof as *Rhizopus arrhizus* B) KOH mount Broad aseptate hyphae of *Mucor*.



**Figure 6:** Characteristic MRI Images of Rhino orbital Mucormycosis with brain extension.

a) Coronal T2W Images show area of T2W hypointensity within the left maxillary and ethmoid sinuses which show non enhancement suggestive of fungal sinusitis. b) Axial T1W post contrast image showing early extension of the disease process into the right pterygopalatine fossa (PPF) as an area of increased enhancement. c) Extensive involvement of the premaxillary space and PPF on the right as an area of non-enhancement on T1W fat suppressed images. d) Contrast enhanced images showing non enhancement of the right orbital soft tissues suggestive of necrosis. e) Non visualization of the left ICA on Time-of-flight angiography (TOF) images suggestive of thrombosis. f) Apparent diffusion coefficient (ADC) map showing evidence of diffusion restriction in the left MCA territory suggestive of an acute infarct

Identification of these changes on computed tomography (CT) and magnetic resonance imaging (MRI) can help in making an early diagnosis of ROCM. In the early stages CT shows mucosal thickening and absence of air-fluid level in the infected sinus. In later stages of the disease invasion of the ipsilateral pterygopalatine fossa, medial orbital wall and other orbital structures can be seen [10]. Because of increased soft tissue resolution, contrast MRI provides a better visualization of involvement of orbital soft tissue, infratemporal fossa, intracranial structures, perineural invasion and vascular obstruction than CT. MRI findings in T2-W described in progressive spread of ROCM include a hypointense sinus wall, hypointense tissue extending from paranasal sinus along orbital apex into the cavernous sinus and narrowing or slow flow in the ipsilateral internal carotid artery in the vicinity of mucor invasion [11]. All these features were very well demonstrated by MRI in our cases (Figure 4). We additionally noticed hyperintense signal intensity on DWI and corresponding hypointense signal on ADC maps in the lesion extending from orbit to cavernous sinus, compatible with restricted diffusion. DWI of brain also showed acute infarcts in the watershed territories. These small infarcts provided additional indirect evidence of tenuous blood supply at watershed territory due to narrowing and arteritis of the cavernous segment of the internal carotid artery.

Direct microscopic examination with 10% KOH or use of optical brighteners along with culture of biological specimens are the cornerstone for diagnosis. To improve the yield, proper sample collection and preparation is imperative before mycological examination. Surgically obtained samples with necrosed tissue are preferred and since the hyphae of mucorales are thin walled and can be easily damaged if specimens are ground instead of cut. Unfortunately, even when fungal hyphae are seen on direct examination, culture sensitivity may be as low as 50% and this, coupled with the need for invasive sampling highlights an urgent need for other methods for the prompt diagnosis of mucormycosis. The molecular identification of Mucorales is a promising approach for the diagnosis of mucormycosis and most assays are based on the detection of ribosomal rRNA genes. Although there are a few studies evaluating biomarker-based tests for the early diagnosis of mucormycosis, none of the tests is clinically validated or commercially available as yet [9].

If clinical suspicion of mucormycosis is strong, positive report of endoscopic nasal or sinus biopsy, and a suggestive MRI finding can be available in less than an hour allowing prompt surgical intervention. For management of mucormycosis, Liposomal Amphotericin B is the preferred treatment in the dose of 3-5mg/kg/day as slow infusion. After 3-4 weeks of amphotericin B therapy, consolidation therapy with azoles (posaconazole or Isavuconazole) is continued for 3-6 months [5]. However, in this study we noted that all patients were treated with combination therapy from the outset, which was later de-escalated to oral azoles on discharge. Control of blood sugar, early treatment with

liposomal amphotericin B, and extensive debridement are essential for the successful management of mucormycosis. However, COVID-19 has created a unique scenario where all three aspects of the management are compromised. Worsening of hyperglycemia, resource constrains during pandemic (including antifungal availability) and coexisting ARDS or multiorgan dysfunction precludes prompt diagnostic workup and surgery. Despite these, we observed a low mortality 21.1% which is comparable to the mortality observed in CAM (30% to 34%) and is lower than earlier reported series among non-COVID patients (40.8 to 54%) [12-14].

Thus, this series highlights the important radiological, mycological, and clinical aspects of CAM. Future prospective multicenter case-control studies, to improve our understanding of the factors affecting the clinical outcome in patients with CAM are warranted. Once CAM is suspected, multidisciplinary approaches with antifungal therapy combined with surgical intervention should be encouraged to improve outcomes.

## References

- Garg D, Muthu V, Sehgal IS, Ramachandran R, Kaur H, et al. (2021) Coronavirus Disease (Covid-19) Associated Mucormycosis (CAM): Case Report and Systematic Review of Literature. *Mycopathologia* 186(2): 289-298.
- Chakrabarti A, Dhaliwal M (2013) Epidemiology of Mucormycosis in India. *Curr Fungal Infect Rep* 7: 287-292.
- Jeong W, Keighley C, Wolfe R, Lee WL, Slavin MA, et al. (2019) The epidemiology and clinical manifestations of mucormycosis: A systematic review and meta-analysis of case reports. *Clin Microbiol Infect* 25(1): 26-34.
- Patel A, Agarwal R, Rudramurthy SM, Shevkani M, Xess I, et al. (2021) MuCovi Network. Multicenter Epidemiologic Study of Coronavirus Disease-Associated Mucormycosis, India. *Emerg Infect Dis* 27(9): 2349-2359.
- Cornely OA, Alastruey-Izquierdo A, Arenz D, Chen SCA, Dannaoui E, et al. (2019) Global guideline for the diagnosis and management of mucormycosis: an initiative of the European Confederation of Medical Mycology in cooperation with the Mycoses Study Group Education and Research Consortium. *Lancet Infect Dis* 19(12): e405-e421.
- Zaman K, Rudramurthy SM, Das A, Panda N, Honnavar P, et al. (2017) Molecular diagnosis of rhino-orbito-cerebral mucormycosis from fresh tissue samples. *J Med Microbiol* 66(8): 1124-1129.
- Patel A, Kaur H, Xess I, Michael JS, Savio J, et al. (2020) A multicentre observational study on the epidemiology, risk factors, management and outcomes of mucormycosis in India. *Clin Microbiol Infect* 26(7): 944.e9-944.e15.
- Prakash H, Ghosh AK, Rudramurthy SM, Singh P, Xess I, et al. (2019) A prospective multicentre study on mucormycosis in India: Epidemiology, diagnosis, and treatment. *Med. Mycol* 57(4): 395-402.
- Skiada A, Pavleas I, Drogari-Apiranthitou M (2020) Epidemiology and Diagnosis of Mucormycosis: An Update. *J Fungi (Basel)* 6(4): 265.
- Yousem DM, Galetta SL, Gusnard DA, Goldberg HI (1989) MR findings in rhinocerebral mucormycosis. *J Comput Assist Tomogr* 13(5): 878-882.
- McLean FM, Ginsberg LE, Stanton CA (1996) Perineural spread of rhinocerebral mucormycosis. *AJNR Am J Neuroradiol* 17(1): 114-116.

12. Muthu V, Agarwal R, Dhooria S, Sehgal IS, Prasad KT, et al. (2021) Has the mortality from pulmonary mucormycosis changed over time? a systematic review and meta-analysis. *Clin Microbiol Infect* 27(4): 538-549.
13. Pandey N, Kaushal V, Puri GD, Taneja S, Biswal M, et al. (2020) Transforming a general hospital to an infectious disease hospital for COVID-19 over 2 weeks. *Front Public Health* 8: 382.
14. Atsuyuki W, So M, Mitaka H, Ishisaka Y, Takagi H, et al. (2022) Clinical Features and Mortality of COVID-19-Associated Mucormycosis: A Systematic Review and Meta-Analysis. *Mycopathologia* 187(2-3): 271-289.



This work is licensed under Creative Commons Attribution 4.0 License  
DOI: [10.19080/JAICM.2023.12.555846](https://doi.org/10.19080/JAICM.2023.12.555846)

**Your next submission with Juniper Publishers  
will reach you the below assets**

- Quality Editorial service
- Swift Peer Review
- Reprints availability
- E-prints Service
- Manuscript Podcast for convenient understanding
- Global attainment for your research
- Manuscript accessibility in different formats  
( Pdf, E-pub, Full Text, Audio)
- Unceasing customer service

**Track the below URL for one-step submission**

<https://juniperpublishers.com/online-submission.php>