

Reconstruction of Torn Document into Suicidal note



Rajiv Dua*

Department of Chemistry, State Forensic Science Laboratory, India

Submission: August 10, 2018; **Published:** August 24, 2018

***Corresponding author:** Rajiv Dua, Department of Chemistry, State Forensic Science Laboratory, Department of Home (Police), Government of Madhya Pradesh, India, Tel: +919425191545, Email: duanobleheights@gmail.com

Abstract

In stressful life, suicide is very common. Death due to hanging is very common method of committing suicide in India. Cultural, social and psychological aspects have the direct role in the causation of suicide. Suicide note is last words left behind by a person who intends to commit suicide. In the present paper, we report 24 years old female who committed suicide by hanging from ceiling hook with wearing apparel around her neck. The victim lady was divorcee, cohabitant with a person, due to failure in her life, no support from parents made her more emotional, she could not balance herself and committed suicide by hanging. The present study also analyses recovery of torn document, its reconstruction and study of its inherent message show the psyche of the patient which play an important role in drawing up logical and accurate conclusion.

Keywords: Hanging; Ligature; Suicide; Torn document

Introduction

Suicide note forms an important part of psychological autopsy that is the information obtained during the last few moments of the deceased regarding the circumstances of suicide to understand the reasons of act of suicide and possible events that would have led to death [1]. Suicidal ideation, concerns thoughts about or an unusual preoccupation with suicide which includes divorce, dowry, love affairs, cancellation or the inability to get married, illegitimate pregnancy, extra-marital affairs and such conflicts relating to the issue of marriage, play a crucial role, particularly in the suicide of women in India [2]. Understanding psyche of the deceased of suicide and knowledge of the messages contained within suicide notes would be useful for suicide prevention Programmes [3]. It is the duty of the forensic medicine expert to check the pockets, secret pockets in the clothes, bag for presence of suicide note. Hanging is one of the popular modes of suicides in India since time immemorial for its simplicity, availability of objects and in terms of efficacy in committing the suicide.

Tendency of an individual to commit suicide is deeply personal and individual act. Suicide notes are often found at crime scene, especially rived document reconstruction is very vital and admired topic for forensic science. Recovery of torn documents is a problem that often arises in archival study and investigation science. Documents may be ripped up by hand or shredded by a machine. Manual reconstruction of a recovered set of ripped-up documents can be a difficult and time-consuming task. Most document reconstruction problems can be solved in two steps, that is, first, finding an initial set of matching fragment pairs as

candidate matches, which is the most time-consuming part of the reconstruction, then resolving the ambiguity among these candidate matches to reconstruct the original document [4,5].

Case History

A dead body of 24-year-old female was found hanged by the wearing apparel in her bed room. It was reported that the body was removed from hanging position and was brought to mortuary for post-mortem examination and forensic team was called to examine the body at mortuary and scene of incidence as per forensic requirements. As per information deceased parents were blaming and putting allegation on deceased cohabitant.

Post mortem: Observations

External Findings

The deceased was a lady of fair complexion wearing yellow blouse and yellow petticoat, white piece of cloth is kept over the body. Ligature knot (sari) was tied around the neck and knot of ligature was present at right side of upper neck. The ligature mark was non-continuous above the thyroid cartilage and extending from left side of the neck to the anterior runs obliquely upward to right mastoid region measuring one cm in breadth. There was dried mark of saliva extending from left angle of mouth upon the left cheek (Figure 1a). The face was congested. The skin beneath the ligature was reddish brown and ecchymosed. The nail bed of fingers and toes were also bluish in colour. Apart from ligature mark over neck, no other external injury was evident. Mobile number of 10 digit was written on the left palm of the deceased.

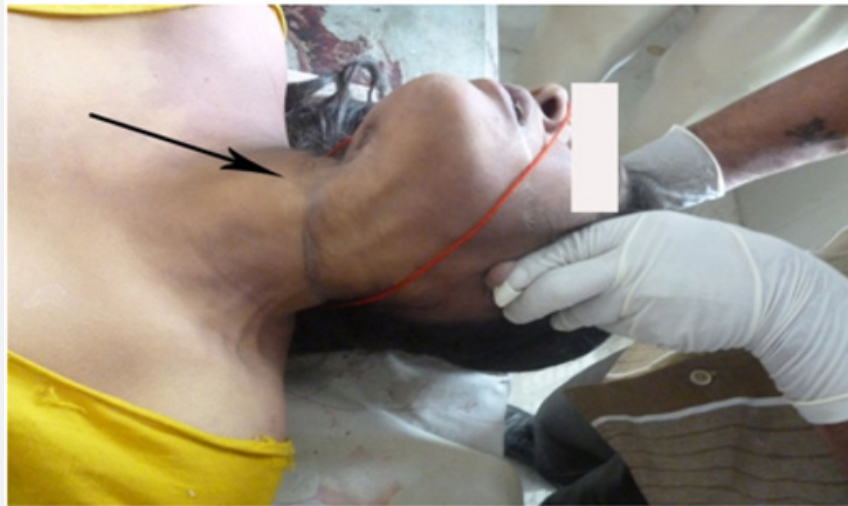

Figure 1(a): Non-Continuous Ligature mark above thyroid cartilage runs upward to right mastoid region.

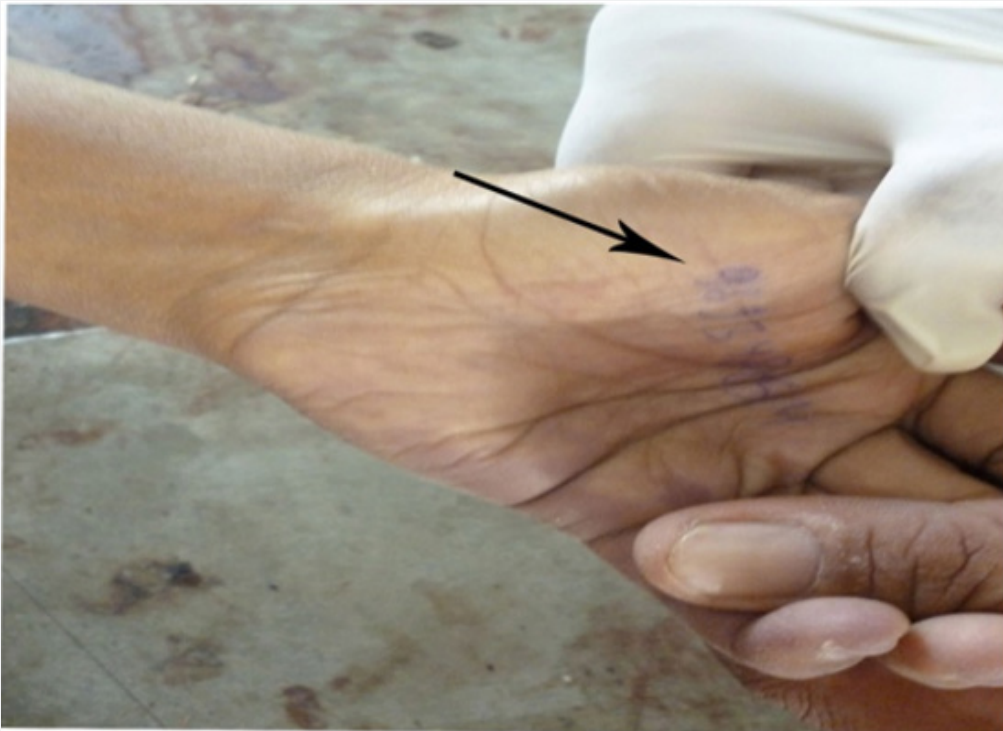

Figure 1(b): Mobile number written on the left palm of the hand.

Internal Findings

Above findings are in favour of antemortem hanging which was also opined by autopsy report in their internal findings.

Crime Scene: Observation and Reconstruction

Crime scene reconstruction is the process of determining or eliminating the events and actions that occurred at the crime scene through analysis of the crime scene pattern, the location and position of the physical evidence, and the laboratory examination of the physical evidence [6,7]. Oftentimes, evidence

tells a story and helps an investigator to re-create the crime scene and establish the sequence of events. The forensic team along with investigating agency arrived the deceased house having two rental rooms at upstairs where deceased committed suicide by hanging from ceiling hook with wearing apparel around her neck to find the truth and let the facts prove or disprove any allegations (Figure 2a). The forensic team searched the scene of incidence thoroughly for the clue materials and following observations were made:



Figure 2(a): Rental house of the deceased where lady committed suicide by hanging.



Figure 2(b): Photograph supplied by investigating officer before spot visit.

I. The inside door of crime scene room has lock hasp in the middle and the place where lock hasp enters the wall, the plaster of the wall was broken, broken pieces of wall plaster were scattered on the floor of the room which shows someone had forcefully opened the door and room was closed from inside during the incidence (Figure 3a).




Figure 3(a): Broken plaster of the wall inside the room near the lock hasp.

II. Room was empty from inside except one carpet is placed on the floor. On one of the wall of the room there is stone shelf with three stone partitions (Figure 3b). at a distance of one foot, the height of the stone shelf from the floor is 4 feet 9 inch. Iron hook is there on the ceiling at a distance of 10 feet from the floor. No other relevant physical evidence were obtained from this room.



Figure 3 (b): Stone Shelf on the wall with three stone partitions.



Figure 4(a): Recovery of two hand bags hung on one wall outside the room.



Figure 4(b): Fragments of irregularly shaped numerous mixed torn pieces of paper.

III. Recovery of two hand bags hanged on one wall outside the room where deceased body was found to be hanged, in one bag two mobile, two memory cards, one mobile sim, one bank pass book and one slip having mobile number 989XXXXX56 was found, the mobile number was same as written on the left palm of the deceased lady. In other bag, irregularly shaped numerous mixed torn pieces of paper were recovered (Figure 4a, 4b).

Reconstruction of the Scene

To reach the ceiling hook the deceased lady must have stood on the upper base of the stone self having with three stone partitions at a distance of one foot. An attempt was made to perform by the neighbour of the deceased who cut the

ligature from the ceiling hook after the incidence, was made to stand on the upper base of the stone shelf (Figure 5). It was found conceivable to reach up to the ceiling hook and thus the re-enactment showed that hanging could indeed have been possible to be performed by the deceased lady by tying a knot around the neck from one end of the wearing apparel (sari) and other end to the ceiling hook. Reconstruction of Torn Document The reconstruction of a torn document with uneven edges is a puzzling, complex and challenging task to be performed by a human operator. In case of machine shredding of pages, each fragment piece of paper has straight edge only and hence the problem may be considered as a variety of jigsaw puzzle. But the reconstruction of torn document by hand is considerably different from the referred jigsaw problem [8,9].



Figure 5: Reconstruction of the Scene.

This is because, a paper when torn creates uneven edges bearing undesired shears containing tiny paper fibres, which gives rise to ill-defined physical contours when compared to jigsaw puzzle which have smooth edges with well-defined corners. A hand-torn piece of paper may have arbitrary shape and as many edges (borders) as possible, depending on how many times the corresponding document has been torn apart. Matching the serrated edges of paper containing texts and images is very helpful in the reconstruction of torn documents.

A challenging issue was there to join the torn pieces of papers to reconstruct the original document but with patience and perseverance torn pieces of paper with uneven edged were matched together and reassembled by manual “random search” strategy [10]. (Figure 6). Continuation of writing established that all the fragments were part of single paper and identified as suicide note supposed to be written by deceased having her signature at the bottom side of the paper.

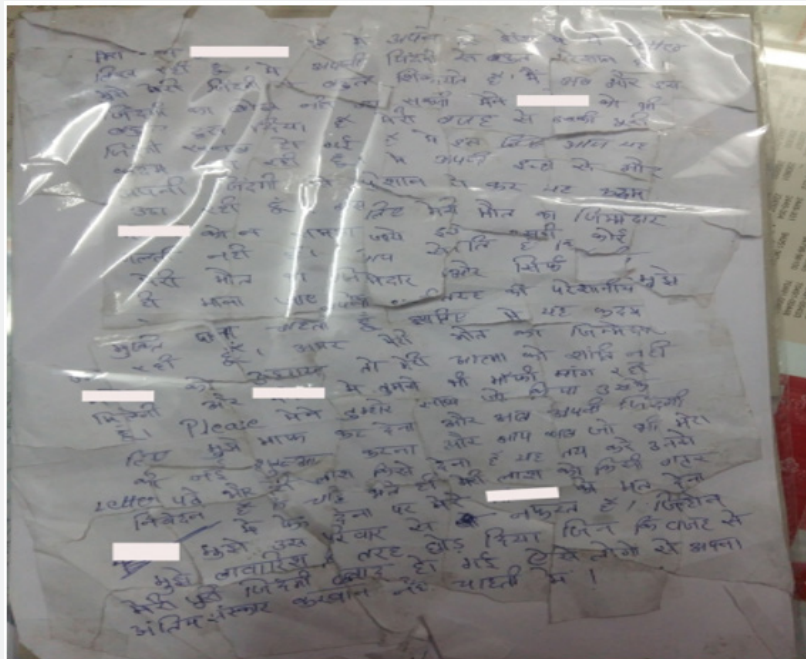


Figure 6: Reconstruction of torn documents into suicidal note.

Results and Discussion

Virtually all hangings are suicidal. Simulation of suicide by hanging a victim previously killed or made unable to resist by other means are regarded as extremely rare events. It is not ordinarily possible with an adult victim, if she or he is not intoxicated or made unconscious by some other means, like head injury. Alternatively, the victim is either a child or a much debilitated person. Signs of struggle may be present on the body of the victim and at the place. In this case it was a case of partial hanging, the ligature material used was wearing apparel (sari) and following ante-mortem signs of hanging were present:

- a. Dribbling of saliva from left angle of mouth upon the left cheek.
- b. The ligature mark was non-continuous above the thyroid cartilage, runs obliquely towards the right ear.
- c. Presence of ecchymosed and redness about the ligature mark,
- d. Signs of central and peripheral cyanosis and, all viscera were congested as per autopsy report. Above four ante-mortem findings are in favor of ante-mortem in nature.

Reconstruction of Torn Document

Phone number written on the palm of the deceased was her friend mobile number to whom she talked prior to committing suicide with concern to her stressed life. Suicide note found at crime scene in which deceased made a plea for absolution due to frustration in her life, blaming parents for not supporting her, and her cohabitant should not be harassed after death. Presence of suicide note at the scene of incidence also helps the forensic

team to investigate that deceased herself was responsible for death.

Conclusion

Hanging is most frequently observed since it is commonly chosen as a method of suicide. Considering thorough complete autopsy including both external and internal examination, physical, circumstantial evidence, re-enactment at the scene of crime and recovery of the torn documents and its reconstruction of torn documents into suicidal note at the scene of incidence reveals this case as a true suicidal hanging, there is no option of second thought. So in conclusion, it can be stated that 'Hanging is always suicidal unless otherwise proved.

Acknowledgment

Author expresses his deep gratitude to Dr. Harsh Sharma Director, State Forensic Science Laboratory Sagar for giving me opportunity to prepare this case report. Author is very grateful to Shri R.A. Chaube, IPS, Dr. Smt Himani Khanna, IPS, for great supporting hand during investigation and finally forensic team members for assisting me at crime scene.

References

1. Rani M, Girdhar S, Murty OP (2015) Suicide Note: The Last Words. J Forensic Medicine and Toxicology 32(2): 35-41.
2. Gliatto MF, Rai AK (1999) Evaluation and Treatment of Patients with Suicidal Ideation. American Family Physician 59(6): 1500-1506.
3. Lakshmi VK (2007) Suicide and its prevention: The urgent need in India. Indian J Psychiatry 49(2): 81-84.
4. Pandya J, Jay V, Dhara M (2014) Proposed Technique for Edge Matching of Torn Paper. International Journal of Modern Trends in Engineering and Research 1(1): 01-04.

5. Liangjia Z, Zongtan Z, Dewen H (2008) Globally Consistent Reconstruction of Ripped Up Documents. IEEE Transactions on pattern analysis and machine intelligence 30 (1): 01-13.
6. Adams TF, Krutsinger J (2000) Crime Scene Investigation, Prentice Hall, Inc., NJ.
7. Vallejo CA, Edsicker D (2001) Crime Scene Investigation and Physical Evidence Manual.
8. Justino E, Oliveira LS, Freitas C (2006) Reconstructing shredded documents through feature matching. Forensic Science International 160(2-3): 140-147.
9. Yao FH, Shao GF (2003) A Shape and Image Merging Technique to Solve Jigsaw Puzzles. Pattern Recognition Letters 24 (12): 1819-1835.
10. Kantilal PR, Bhirud SG (2011) Text Reconstruction using Torn Document Mosaicing. International Journal of Computer Applications



This work is licensed under Creative Commons Attribution 4.0 License
DOI: [10.19080/JFSCI.2018.10.555787](https://doi.org/10.19080/JFSCI.2018.10.555787)

**Your next submission with Juniper Publishers
will reach you the below assets**

- Quality Editorial service
- Swift Peer Review
- Reprints availability
- E-prints Service
- Manuscript Podcast for convenient understanding
- Global attainment for your research
- Manuscript accessibility in different formats
(Pdf, E-pub, Full Text, Audio)
- Unceasing customer service

Track the below URL for one-step submission
<https://juniperpublishers.com/online-submission.php>