

Forensic Evidence of a Surgical Fetus- A Rare Case Report



HK Pratihari^{1*}, Subhankar Nath¹, M Pradhan² and SB Chakraborty²

¹State Forensic Science Laboratory, India

²Department of Obstetrics & Gynaecology, Agartala Government Medical College, India

Submission: December 9, 2019, Published: January 10, 2020

*Corresponding author: HK Pratihari, State Forensic Science Laboratory, Tripura-799015, India

Abstract

Rape is the fastest growing crime in the country compared to other crime against women. It is also seen minor girl age between (7-12 year) is found rape-victim and sometimes reported pregnant being raped. In such cases, pregnancy is terminated by doctors using different methods to save the life of minor innocent girl, protect from Human Rights and social stigma. In one case, a girl child, age about 12 year, was staying with single parent family. She used to visit and play with her friend being the neighbour. Taking advantage of age, the girl was lured and repeatedly raped by her friend's uncle, an elderly man age about 57 year. One day, the victim girl complained abdominal pain and the doctor confirmed her pregnant but then she was about 20 weeks. The mother took up the matter to legal court to save her daughter being unable to access to medical termination of pregnancy (MTP). Considering the girls age/health, medical board was held under judge's order and decided to end the pregnancy. The unborn fetus of the victim girl was removed and received in forensic science laboratory for DNA evidence to link the accused and establish the crime. The minor girl was saved to carry the pregnancy further. The details have been discussed in this rarest of the rare case.

Keywords: Minor girl; Illegal sex; Fetus, Surgery; DNA evidence

Introduction

In the life cycle of women, they are subjected to different violence in the society. The crime against women includes mostly sexual assault, foeticide, infanticide, dowry death, bride burning forced prostitution/sterilization etc. [1-3]. But rape/sexual assault is one of the most common crime reported against women of different age groups even kids and aged women are not spared. The sex with minor girl is an evil scenario in the society and reported for various reasons [4] According to National Crime Records Bureau (NCRB), MHA, Govt. of India, 2013 Annual Report, 24,923 rape cases were reported across India in 2012, out of which 24,470 committed by someone known to the victim [5] The statistical figure of rape cases is available but pregnant being raped is not much as such statistics under such crime head is not found in literature. The following are the reasons for increase of sexual offence cases in the country [6,7].

- Man dominated society
- Improper respect for women
- Girls are not properly educated to react
- Use of mobile blue film

- No exemplary punishment and trials get unusually delay
- Want of quality investigation
- Media and dress code
- Sadistic lifestyle
- All want girl friend
- Use of internet-based child sexual exploitation networking (Dark net market).

There is law to permit termination of pregnancy when there is threat to life or abnormal fetus. In this case, the victim was minor and under order of Hon'ble court unborn fetus was surgically removed by a team of doctors to terminate the pregnancy.

Case Report

A girl child age about 12-year was staying with single parent and used to visit her friend's house being neighbor. Taking advantage of frequent visit, her friend's uncle an elderly man age about 57 year lured the girl and developed physical relation. Subsequently, the girl got pregnant. One day having severe abdominal pain the girl child (victim) told her mother and on

medical checkup, she was confirmed to be pregnant. Thereafter, the child revealed the hidden truth to her mother about sexual abuse by the uncle of her friend. She (victim) was then twenty weeks of pregnancy and risky on her age/health to continue. Hence took help of Hon'ble court for termination of pregnancy to save the life of minor girl child and lodged a FIR in the local police station for justice. The case was registered u/s 376(2)(1)(a)/506 Indian Penal Code (IPC) and sec 6 of Protection of Children from sexual offences (POCSO) Act.

Materials and Methods

In this critical case, as per order of the Hon'ble Court the fetus of the victim girl was removed by surgical method by a team of gynecological experts. Subsequently biological fluid (blood) from the offender and the victim girl was collected as per blood sample authentication form. The illegal surgical fetus after removal was also received for DNA evidence.

Medical examination and result

Potency test of the offender

- A. **General Physical Examination:** Height 157cm, weight 51kg, pulse 78bpm, beard and moustache adult type, axillary and pubic hair adult type.
- B. **Local Examination:** Penis length 8cm and circumference 9cm in flaccid condition, both the testes descended into the scrotal sac, scrotal skin is healthy; no genital, extra-genital

injury was noted.

- C. Based on the above findings the medico-legal expert opined that there was nothing to suggest that the offender is not capable of performing sexual intercourse

Surgical method used to remove unborn fetus

It was a case of late mid-trimester abortion. As per protocol, medical termination was attempted first by using prostaglandins and oxytocin. But as it failed it was decided to do surgical induction by transabdominal anterior hysterotomy under general anesthesia. In this procedure, after opening the abdomen low transverse incision was made on lower segment of the uterus. Abortus and placenta were removed completely; uterine wall was sutured in layers. Complete hemostasis was secured followed by closure of abdomen. Postoperative period was monitored meticulously by intravenous fluid, antibiotics, sedation and oxytocin.

Forensic DNA Evidence

Samples received from three different sources were properly preserved in the laboratory. The DNA Typing from three sources was made by using Genetic Analyzer AB 3130, Life Technologies Holding Pvt. Ltd., USA, following standard procedure available in literature [8]. The DNA profiling of all the three different exhibits are shown in (Table 1). The allelic distribution of fetus, victim and offender shown conclusively confirms that the victim and the offender are the biological parents of the fetus (Figure 1-3).

Table 1: Allelic distribution of fetus, victim and offender (Paternity determination).

Locus/Marker	Positive Control DNA 9947A	Negative Control	Fetus of Victim	Blood Sample of Victim	Blood Sample of Offender
D8S1179	13	NA	14,15	3, 14	14, 15
D21S11	30	NA	28, 31.2	31.2, 32.2	28,31.2
D7S820	10,11	NA	10	10,11	10
CSF1PO	10,12	NA	11,12	11,12	11,15
D3S1358	14,15	NA	16,17	16,17	15,16
TH01	8, 9.3	NA	9,9.3	9,9.3	7,9
D13S317	11	NA	8,11	11	8,9
D16S539	11,12	NA	11,12	11	12
D2S1338	19,23	NA	18,21	18,25	19,21
D19S433	14,15	NA	15,16	15,15.2	13,16
VWA	17,18	NA	14,17	17	14,18
TPOX	8	NA	10	10,11	8,10
D18S51	15,19	NA	10,14	10,13	12,14
Amelogenin	X, X	NA	X	X	XY
D5S818	11	NA	10,12	12,13	10,11
FGA	23,24	NA	22,26	24,26	21,22



Figure 1: Victim girl, 12yr.

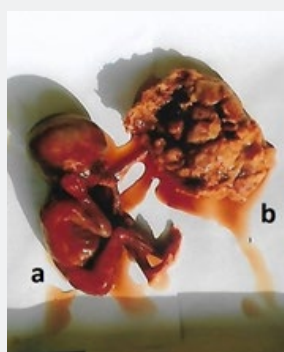


Figure 2: Fetus, 20 week (a), placenta (b).

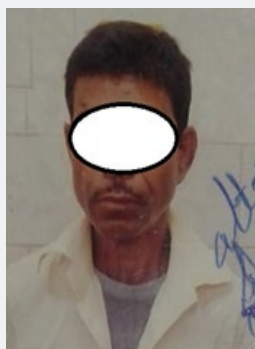

Figure 3: Offender, 57yr.

Conclusion

In this case the minor innocent girl was easily lured by the elderly man and repeatedly raped to satisfy his sex desire. But the offender could not think of the consequence as a result the girl got pregnant being raped. Moreover, the innocent girl could not understand what is being done on her and going to happen. She

was also not taught to protest from such inhuman activity by her parents. As a child, she (victim) totally surrendered without any resistance to the offender and became the rape-victim of the devil. The fear of threatening in the mind of the girl being killed by the offender also kept her silent. As such, she was not at fault, abuser to blame. The criminal profile of the accused in this case, appears to be psychopath and mentally perverted and could not understand the barbaric act with a girl 12-year age almost like a daughter. The offender also did not care about stringent punishment prescribed under Protection of Children from Sexual Offences (POCSO) Act, leading to life imprisonment and even death. The offender is to be further examined by the psychiatric professional to know such unusual aggressive behavior. This is humiliating event in women's life. The incident reminds a quote:

"Surgery during life is painful and benefit individual.

Surgery after death is not painful but benefits mankind"

The forensic result showing DNA evidence supported by the statement of the victim girl and medical report and circumstantial evidence could conclusively identified the offender & establish the crime.

Acknowledgment

The authors are thankful to Dr. Prasenjit Das and Dr. Sabyasachi Nath for their valuable suggestion and also to Miss Emily Nandy, investigating officer of the case for taking keen interest for successful investigation and care taken for timely dispatch of biological exhibits to the laboratory.

References

1. Sapkota D, Bhattarai S, Baral D (2016) Domestic violence and its associated factors among married women of a village development committee of rural Nepal. BMC Res Notes 9: 178.
2. https://en.wikipedia.org/wiki/Violence_against_women_in_India
3. <http://www.endvawnow.org/uploads/modules/pdf/1372349234.pdf>
4. Nath S, Pratihari HK (2019) Rape-Murder of A Kid-A Rare Case Report. J Forensic Sci & Criminal Inves 13(1): 1-3.
5. National Crime Records Bureau (2012) Ministry of Home Affairs, Government of India.
6. Fisher, Barry AJ (2004) Techniques of crime scene investigation. (7th Edn.), CRC Press LLC, Boca Raton, USA.
7. Becker, Ronald F (2009) Criminal Investigation. (3rd Edn.), Jones and Bartlett Publishers, Sudbury, Massachusetts, USA.
8. Butler, John M (2009) Fundamentals of Forensic DNA Typing. Academic Press, Burlington, USA.



This work is licensed under Creative Commons Attribution 4.0 License
DOI: [10.19080/JFSCI.2020.13.555862](https://doi.org/10.19080/JFSCI.2020.13.555862)

**Your next submission with Juniper Publishers
will reach you the below assets**

- Quality Editorial service
- Swift Peer Review
- Reprints availability
- E-prints Service
- Manuscript Podcast for convenient understanding
- Global attainment for your research
- Manuscript accessibility in different formats
(Pdf, E-pub, Full Text, Audio)
- Unceasing customer service

Track the below URL for one-step submission
<https://juniperpublishers.com/online-submission.php>