

Diagnostic Performance of Magnetic Resonance Imaging in the Pretreatment Evaluation of Invasive Cervical Carcinoma

Nazmun Nahar^{1*}, Rokshana Ahmed², Shahryar Nabi³, Asifa Sattar⁴, Sahara Haque³ and Husne Ara³

¹Department of Radiology and Imaging, National Institute of Neurosciences and Hospital, Bangladesh

²Indoor Medical Officer, National Institute of Neurosciences and Hospital, Bangladesh

³Department of Radiology and Imaging, Dhaka Medical College, Bangladesh

⁴Department of Radiology and Imaging, Sir Salimullah Medical College, Bangladesh

Submission: January 04, 2016; **Published:** January 13, 2016

***Corresponding author:** Nazmun Nahar, Associate Professor, Department of Radiology and Imaging, National Institute of Neurosciences and Hospital, Sher-E-Bangla Nagar, Dhaka, Bangladesh, Tel: 01712007441; Email: nazmuntony@gmail.com

Abstract

This cross sectional study was carried out in the department of Radiology and Imaging, Dhaka Medical College Hospital in collaboration with Obstetrics and Gynecology department from July 2010 to June 2012 to compare the levels of diagnostic performance of MRI with FIGO clinical staging in the pretreatment evaluation of invasive carcinoma of the cervix using surgicohistopathological findings as reference standard. 30 patients with invasive carcinoma of uterine cervix were enrolled. Patients were examined by the gynecologic surgeon to determine the appropriate clinical FIGO stage. MRI examination was performed in all patients. In all cases, the findings of MRI, clinical examination and histopathological reports were recorded on a preformed data sheet. Finally, the accuracy of MRI findings and clinical FIGO staging were evaluated against the surgicohistopathological reports. For each modality, the estimated area under the ROC curve was reported. MRI (0.88) was significantly better than FIGO staging (0.68) for staging cervical tumor in Stage IA, as measured by the respective areas under the ROC curves (AUC). In case of Stage IIA, MRI (0.86) also proved to be significantly better than FIGO staging (0.74). These results revealed that MRI staging was more accurate than FIGO staging in diagnosis of invasive cervical carcinoma.

Keywords: MRI; Cervical carcinoma

Conclusion: ROC: Receiver Operating Characteristic; NICRH: National Institute of Cancer Research and Hospital

Introduction

Cervical cancer is third most common malignancy affecting the female genital tract in middle age group between 45 and 55 years [1,2]. Approximately 80% of cervical cancers occur in developing countries. Worldwide, in 2008, it was estimated that there were 473,000 cases of cervical cancer, and 253,500 deaths per year [3]. According to the National Institute of Cancer Research and Hospital (NICRH), Dhaka, cancer registry report that covers three years from 2005 to 2007, cervical cancer is the second most common cancers among females (21.5%) and ranked third among the whole group. Patient outcome depends on tumor stage, size, nodal status and histological grade. Correct tumor staging is important to decide the treatment strategy. Clinically staging is based on 1994 clinical FIGO criteria. Clinical staging is based on histological specimens and

physical examination of the pelvis. To be done properly, physical examination of the pelvis should be performed with the patients under GA. It is subjective and depends on the experience of the examiner. Moreover, clinical examination cannot show the precise extent and volume of the endophytic (barrel - shaped) tumor, as seen in the FIGO classification, which disregards tumor extension to the corpus. Compared with surgical staging, FIGO clinical staging has been shown to result in under staging of up to 20% to 30% in stage IB, up to 23% in stage IIB and almost 40% in stage IIIB, as well as over staging of approximately 64% in stage IIIB [4]. The greatest difficulties in the clinical evaluation of patients with cervical cancer are the estimation of tumor size, especially when the tumor is endocervical in location; the assessment of parametrial and pelvic sidewall invasion; and the evaluation of lymph node and distant metastases. MRI is the best single imaging investigation that can accurately

determine tumor volume, location (endocervical/exophytic), depth of stromal invasion and extension into lower uterine and vaginal segments. It is accurate for evaluation of tumor size, usually within 0.5 cm of the surgical size; in 70% to 90% of cases [5]. It is also useful in the evaluation of lymph node metastases. MRI the modern diagnostic procedure has shown advantages over existent techniques in imaging of female pelvis. It has complemented sonography and/or CT in further refining anatomic details and allowing the display of the disease in more detail. Ultrasonography remains the screening technique for the many uterine and ovarian lesions. However, its significant operator dependence, limitations due to patient's habitus, and relative inability to tissue characterization, significantly decrease its value. CT which is currently used for the staging of pelvic neoplasm also has limitations. These include the presence of ionizing radiation and distortion due to metallic clips, contrast media, and bone density. All this restricts the usefulness of pelvic CT, particularly in regard to soft tissue resolution [6]. MRI is noninvasive, does not depend on ionization, has superb soft tissue contrast resolution, and is capable of multidirectional imaging, simultaneous imaging of multiple sections, and visualization of blood vessels without the need of contrast injection. The aim of present study was to compare the diagnostic performance of MRI with FIGO clinical staging in the pretreatment evaluation of invasive cancer of the cervix using surgicohistopathological findings as the reference standard.

Materials and Methods

This cross sectional study was performed in Department of Radiology & Imaging, Dhaka Medical College Hospital with the collaboration of Obstetrics and Gynecology unit. Between the period of July, 2010 to June, 2012, 30 patients meeting the selection criteria were included in the study. Inclusion criteria were- patients having biopsy confirmed invasive cervical cancer for which surgery was intended and for which a FIGO clinical stage ≤ II-A was assigned before imaging, patients who were willing to undergo surgery and suitable for contrast enhanced MRI. Exclusion criteria were - Patients not suitable for surgery or refused to do MRI scan and surgery, patients in whom surgicohistopathological report were not available. Patients were examined under anesthesia by the gynecologic surgeon to determine the appropriate clinical FIGO stage (Figure A). Patients were instructed to fast for 4-6 hours before the MRI examination to limit artifact due to small bowel peristalsis. MR examination was performed in all patients by using 0.3 Tesla, HITACHI- MRI machine. In each patient, images were obtained with 1 cm thick contiguous sections in transverse, sagittal and coronal planes. The matrix was 256×256, with a 32 cm field of view, and the data were displayed in a 512×512 matrix. Imaging protocols was preset in machine. Post contrast images were achieved by delivering a bolus (50 ml) Gadolinium DTPA in intravenous route manually by medium hand pressure (at a rate of about 1-1.5 ml/sec with 19/20 gauge needle) and completed by 50-60 sec.

Classification of Cervical Carcinoma Using TNM and International Federation of Gynecology and Obstetrics (FIGO) Staging Systems

TNM	FIGO ^a	Description
T1	I	Carcinoma confined to the cervix
T1a	IA	Invasive carcinoma identified only microscopically
T1a1	IA1	Stromal invasion no greater than 3 mm in depth and no wider than 7 mm
T1a2	IA2	Stromal invasion greater than 3 mm but less than 5 mm in depth and no wider than 7 mm
T1b1	IB1	Clinical lesions no larger than 4 cm
T1b2	IB2	Clinical lesions larger than 4 cm
T2	II	Extension beyond cervix and involvement of the upper vagina (but not the lower vagina)
T2a	IIA	No parametrial invasion
T2b	IIB	Parametrial invasion
T3	III	Invasion of the lower third of the vagina, invasion extending to the pelvic sidewall, or both
T3a	IIIA	Invasion of the lower third of the vagina
T3b	IIIB	Extension to the pelvic wall or hydronephrosis (or both)
T4	IVA	Invasion of the mucosa of bladder, rectum, or bladder and rectum; invasion extending beyond the true pelvis; or both
M1	IVB	Spread to distant organs

FIGO staging system is based on surgical and pathologic findings alone; imaging, although useful in preoperative assessment of tumor stage, is not recognized as a method for definitive staging.

Figure A: Classification of cervical carcinoma using FIGO and TNM staging system (After Sala et al. 2007).⁸

All MR images were interpreted without knowledge of the clinical or surgicohistopathological findings and based on specific MR imaging staging criteria Togashi, et al. [7] by the investigator and one of the expert radiologists of the department. Finally, the diagnostic effectiveness of MRI staging and clinical FIGO staging were evaluated against the surgico-histopathological reports [8].

Observation and Results

This cross sectional descriptive study was carried out on 30 purposively selected subjects whose age ranged from

35 to 70 years. All patients who attended in the Department of Radiology and Imaging, Dhaka Medical College, hospital, Dhaka, having biopsy confirmed cervical cancer of FIGO Stage ≤ IIA scheduled for surgery based on clinical assessment during the period from July, 2010 to June, 2012 were included in this present study. MRI was done and compared with that of surgicohistopathological findings. Data regarding the clinical, MRI and surgicohistopathological findings are presented in (Tables 1-4 and Figures 1,2).

Table 1: MR imaging findings of 30 patients with invasive cervical carcinoma.

MRI Findings	Characteristics	No of patients	Percentage
Location	Anterior lip	2	6.67
	Posterior lip	1	3.33
	Circumferential	27	90
Nature	Exophytic	3	10
	Endophytic	27	90
Signal intensity	T1W-Iso-hypo	30	100
	T2W-Hyper	30	100
Contrast	Present	28	93.33
Enhancement	Absent	2	6.67
Size	≤ 3 cm	9	30
	3-5 cm	11	36.67
	≥5cm	10	33.33
Stromal invasion	No invasion	0	0
	Partial	26	86.67
	Complete	4	13.33
Extension	Lower uterine segment	14	46.67
	Upper2/3rd vagina	7	23.33
	Lower1/3rd vagina	1	3.33
	Parametrium	4	13.33
	Pelvic wall	0	0
	Urinary-bladder	2	6.67
	Rectum	1	3.33

Table 2: MR imaging stage compared with surgical stage.

urgical Stage	Total	MR Imaging Stage					
		IB	IIA	IIB	IIIA	IIIB	IVA
IB	10	07	02	01	00	00	00
IIA	10	01	08	01	00	00	00
IIB	06	01	01	04	00	00	00
IIIA	01	00	00	00	01	00	00
IIIB	00	00	00	00	00	00	00
IVA	03	00	00	01	00	00	02

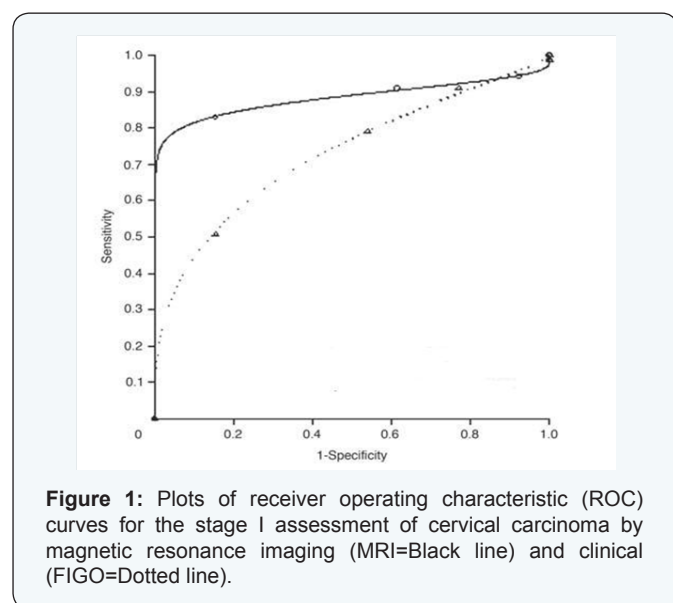
Table 3: Clinical (FIGO) stage compared with surgical stage.

Surgical Stage	Total	Clinical Stage (FIGO)					
		IB	IIA	IIB	IIIA	IIIB	IVA
IB	10	06	03	00	00	00	00
IIA	10	01	20	00	00	00	00
IIB	06	00	00	00	00	00	00
IIIA	01	00	00	00	00	00	00
IIIB	00	00	00	00	00	00	00
IVA	03	00	00	00	00	00	00

Table 4: Diagnostic performance of MRI scan and Clinical staging for detection of carcinoma of cervix considering surgicohistopathological results as gold standard test.

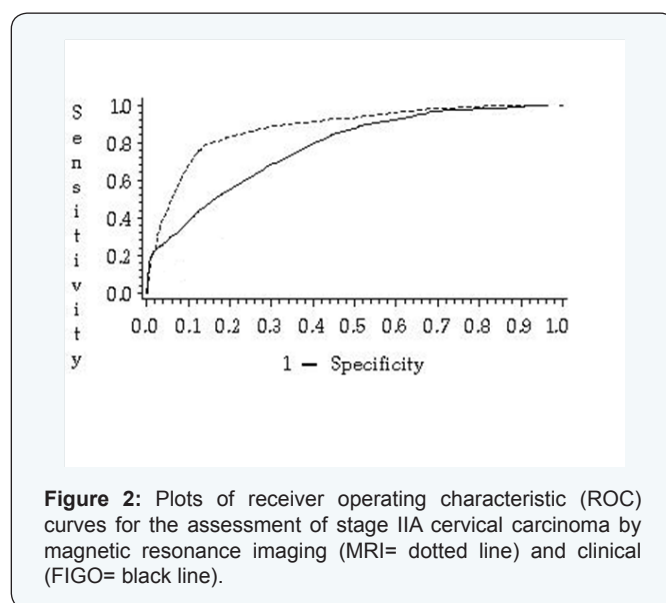
Staging	Sensitivity		Specificity		Positive predictive value		Negative predictive value		Accuracy	
	MRI	Clinical	MRI	Clinical	MRI	Clinical	MRI	Clinical	MRI	Clinical
IB	90.00	29.41	75	53.84	64	45.49	93	36.84	80	40
IIA	80	84.34	100	63.86	100	84.87	90.9	45.86	93.33	67.44
IIB	60.33	00	55.36	00	64.5	00	56.33	00	69.54	00
IIIA	100	00	100	00	100	00	100	00	100	00
IIIB	00	00	00	00	00	00	00	00	00	00
IVA	66.66	00	100	00	100	00	96.42	00	96.66	00

*Results were expressed in percentage.



Surgicopathological staging confirmed 10 cases in Stage IB. In this group, MRI confirmed 7 patients in Stage IB, 2 patients in Stage IIA and 1 patient in Stage IIB. Among 10 surgicopathologically confirmed Stage IIA cases, one was staged in IB on MRI. MRI diagnosed eight subjects in Stage IIA and one in IIB in this group. Surgicopathological staging confirmed six cases in Stage IIB. Among them, four were within Stage IIB. In Stage IB and IIA there was one subject in each group. Only one subject was confirmed in Stage IIIA both in pathology and MRI.

Surgicopathological staging confirmed 10 cases in Stage IB.



In this group, FIGO staging confirmed six patients in Stage IB and three patients in Stage IIA. Ten subjects were found in Stage IIA surgicopathologically. In this group twenty patients were confirmed in Stage IIA and one in Stage IB.

Considering surgicopathological diagnosis as gold standard test, sensitivity, specificity, PPV, NPV and accuracy of MRI scan in IB staging were 90%, 75%, 64%, 93% and 80% respectively. In case of FIGO staging, sensitivity, specificity, PPV, NPV and accuracy in IB staging were 29.41%, 53.84%, 45.49%, 36.84% and 40% respectively.

For MRI sensitivity, specificity, PPV, NPV and accuracy in IIA staging were 80%, 100%, 100%, 90.9% and 93.33% respectively. FIGO IIA staging had sensitivity, specificity, PPV, NPV and accuracy in IIA staging were 84.34%, 63.86%, 84.87%, 45.86% and 67.44% respectively.

In Stage IIB, sensitivity, specificity, PPV, NPV and accuracy were 60.33%, 55.36%, 64.5%, 56.33% and 69.54% respectively for MRI scan.

For Stage IIIA all the diagnostic parameter was 100% for MRI.

Considering surgicopathological diagnosis as gold standard test, sensitivity, specificity, PPV, NPV and accuracy of MRI scan in IVA staging were 66.66%, 100%, 100%, 96.42% and 96.66% respectively. For each modality, the estimated area under the ROC curve was reported. MRI (0.88) was significantly better than FIGO staging (0.68) for staging cervical tumor in Stage IA, as measured by the respective areas under the ROC curves (AUC).

The estimated area under the ROC curve was reported in both MRI and FIGO staging. MRI (0.86) was significantly better than FIGO staging (0.74) for staging cervical tumor in Stage IIA, as measured by the respective areas under the ROC curves (AUC).

Discussion

With the aim to compare the levels of diagnostic performance of MRI with FIGO clinical staging in the pretreatment evaluation of invasive cancer of the cervix using surgicohistopathological finding as reference standard, this cross sectional study was carried out in Department of Radiology and Imaging, Dhaka Medical College Hospital in collaboration with Obstetrics and Gynecology department, during the period of July, 2010 to June 2012 enrolling 30 patients with invasive cervical carcinoma of uterine cervix. Appropriate clinical FIGO staging was determined first followed by MRI examinations in all patients. Finally, the accuracy of MRI findings and clinical FIGO staging were evaluated against the surgicohistopathological reports. Study subjects had age ranged from 35 to 70 years. The results of the study are discussed below on the basis of previous studies.

Hricak et al. [5] described that majority (95%) of the cervical carcinoma was histologically squamous variety. Among 30 cases in present study, histopathologically 94% squamous cell carcinoma was confirmed and 6% subjects had adenocarcinoma. All of the cases with carcinoma of cervix had invasion. MRI revealed partial invasion in 26 subjects and complete invasion in 4 cases. Hricak et al. [5] found invasion in 100% cases which was similar with the present study. The accurate staging of carcinoma of the cervix is important because the choice of treatment depends on the clinical stage of the disease at the time of initial examination.

In present study, 10 patients had surgicopathological Stage

IB, 10 had stage IIA, 6 had stage IIB, 1 had stage IIIA, and 3 had stage IVA. In case of stage IB, MRI confirmed 7 patients and clinical examination confirmed 6 patients correctly as Stage IB. Regarding stage IIA, MRI diagnosed 8 patients and clinical examinations 20 patients in Stage IIA. Surgicopathologically stage IIB was confirmed in 6 cases, among them, four were correctly diagnosed by MRI, but clinical examination failed to stage any patient in this stage. Only one subject was confirmed in Stage IIIA both in histopathology and MRI. Regarding stage IVA, three patients were surgically confirmed and only 2 were correctly diagnosed by MRI scan but none of them were detected clinically. These findings revealed that MRI staging was very much similar to surgicopathological staging and FIGO staging could not detect any case beyond Stage IIA in this study. In Stage IIA, there was overestimation by FIGO staging. This finding was similar with the study conducted by Hricak et al. [5] MRI image could demonstrate parametrium clearly. So, MRI staging gave better staging than FIGO staging. Sironi et al. [9] observed that overall accuracy of MR imaging in staging cervical carcinoma (stage IB-IIB) was 78.1%. MR imaging seemed to be the most reliable preoperative modality for staging invasive cervical cancer Ruben et al. [10] MR imaging should be used in conjunction with clinical staging to determine appropriate therapy in patients with stage IB -IIB cervical carcinoma.

At present study, in case of IB staging, sensitivity, specificity, PPV, NPV and accuracy of FIGO were 29.41%, 53.84%, 45.49%, 36.84% and 40% respectively and those for MRI were 90%, 75%, 64%, 93% and 80% respectively.

For MRI, sensitivity, specificity, PPV, NPV and accuracy in IIA staging were 80%, 100%, 100%, 90.9% and 93.33% respectively. FIGO IIA staging had sensitivity, specificity, PPV, NPV and accuracy 84.34%, 63.86%, 84.87%, 45.86% and 67.44% respectively.

It was observed that clinical staging was possible up to IIA stage. Therefore, beyond IIA stage diagnostic accuracy was not possible to calculate. In Stage IIB, sensitivity, specificity, PPV, NPV and accuracy were 60.33%, 55.36%, 64.5%, 56.33% and 69.54% respectively for MRI scan.

For Stage IIIA, all the diagnostic parameter was 100% for MRI. Sensitivity, specificity, PPV, NPV and accuracy of MRI scan in IVA staging were 66.66%, 100%, 100%, 96.42% and 96.66% respectively.

For each modality (FIGO and MRI scan) in present study, the estimated area under the ROC curve was reported which revealed that MRI (0.88) was significantly better than FIGO staging (0.68) for staging cervical tumor in Stage IA. In case of Stage IIA, MRI (0.86) was also proved to be significantly better than FIGO staging (0.74) for staging cervical tumor. These results revealed that MRI staging was more accurate than FIGO staging in diagnosis of invasive cervical carcinoma.

Staging of cervical carcinoma was based on involvement of lower uterine segment, vaginal involvement, involvement of parametrium, pelvic side walls, urinary bladder and rectal involvement. Volume of the tumor mass and enlarged LN, although not included in FIGO staging, they are two important prognostic factors for patients survival.

Rockall et al. [11] defined Stage IA as a microinvasive tumor that cannot be reliably shown on T2-weighted images. However, microinvasive disease might be detected on dynamic MRI as a strongly enhancing area on early arterial phase images. MRI is more accurate for predicting macroinvasive tumor and in showing its relationship of to the internals and surrounding structures.

Although, location of the tumor plays no role in staging, we demonstrated 17 patients had circumferential tumor mass, 09 had anterior lip and 04 had posterior lip tumor mass. All of them were endocervical mass, none had exophytic growth. Extension of tumor into lower uterine segment was histologically documented in 17 patients and was demonstrated by MR imaging in 14 patients. It had sensitivity, specificity and accuracy of 64.28%, 50% and 56.61%, respectively.

The sensitivity of MR imaging for detection of vaginal extension in lower third was excellent, there were no false positive and false negative diagnosis giving a predictive value of positive test and negative test of 100%. FIGO staging failed to demonstrate lower vaginal (Lower third) invasion. Greco et al. [12] reported that MRI accuracy in assessment of vaginal involvement was 100% respectively.

Rockall et al. [11] stated that in stage II tumors, the sensitivity of MRI in the evaluation of parametrial invasion was 69%, and the specificity was 93%. An intact low-signal-intensity cervical stroma virtually excludes parametrial invasion with a negative predictive value of 94–100%. In the present study, FIGO staging could not demonstrate parametrial involvement in any case but surgicopathologically 6 cases of parametrial involvement were confirmed. In demonstrating parametrial involvement, MR imaging had an accuracy of 93.33%, sensitivity 66.66% and specificity of 100%.

Clinical staging could not find bladder involvement in any case and two cases of bladder involvement were confirmed after surgery and MRI scan. Rectum involvement was not found in FIGO staging. One case of rectal involvement was confirmed after surgery and MR imaging. Thus, considering surgical staging as gold standard test diagnostic performance of MRI staging in detecting rectal invasion was 100%. The absence of bladder and rectal invasion can be diagnosed with sufficient confidence using MRI (NPV 100%) to safely obviate invasive cystoscopic or endoscopic staging in most patients with cervical cancer. This could potentially lead to a reduction in staging cost and morbidity.

In patients with endometrial and cervical cancer, the presence of lymph node metastasis suggested a poor prognosis, with a marked decrease in survival rate. Lymph node involvement which was not included in FIGO staging system of carcinoma of cervix was also an important factor in choice of adjuvant radiation therapy in both endometrial and cervical cancer. During surgicopathological staging, 23 lymph nodes were found. MR imaging demonstrated 17 cases of enlarged LN. Among them, 10 cases were correctly diagnosed as malignant (True positive) but, incorrectly showed tumor positive nodes in 07 patients (False positive). It should be noted that FIGO staging always failed to demonstrate lymph node where MRI staging could detect lymph node which might be helpful for management purpose. Previous study by Hyuck et al. [13] that MRI could detect lymph node as accurately as CT scan and an increased lymph node short axis diameter more than 1 cm correlated with lymph node metastasis in cervical cancer patient.

From the results of the present study and the findings obtained by others, it is conceivable that MR imaging is a reliable imaging technique for diagnosing, staging and also evaluating important prognostic factors of carcinoma of cervix.

Summary

This present study was carried out in Department of Radiology & Imaging, Dhaka Medical College Hospital in collaboration with Obstetrics and Gynecology department. The general objective of this cross sectional study was to compare the levels of diagnostic performance of MRI with FIGO clinical staging in the pretreatment evaluation of invasive cancer of the cervix using surgicohistopathological finding as reference standard during the period of July, 2010 to June, 2012, enrolling 30 patients with invasive cervical carcinoma of uterine cervix. Patients were examined under anesthesia by the gynecologic surgeon to determine the appropriate clinical FIGO stage. MR examinations were performed in all patients. In all aspects, the findings of MRI, clinical examinations and histopathological reports were recorded on a preformed data sheet. Finally, the accuracy of MRI findings and clinical FIGO staging were evaluated against the surgicohistopathological reports. The following results and observations were obtained.

The age range of the patients was 34 – 70 years.

Among the cases histopathology confirmed that 94% subjects had Squamous cell carcinoma and 6% subjects had adenocarcinoma. All of the cases with carcinoma of cervix were invasive, partial invasion in 26 patients and complete invasion in 4 patients.

Regarding staging, 10 patients had surgical staging IB, 10 had stage IIA, 6 had stage IIB, one had stage IIIA and 3 had stage IV carcinoma of cervix. The study staged the tumour of these 30 patients with MR imaging. It was determined that 7 patients had stage IB, 8 had stage IIA, 4 stage IIB, one stage IIIA and 2

stage IVA. The lesion was correctly staged in 22 of 30 patients, 4 lesions were staged too high and 4 too low. Whereas FIGO staging correctly diagnosed in 16 patients, 3 were staged too high and 11 too low.

In stage IB overall accuracy of MR imaging and FIGO staging was 80% and 40% respectively.

In staging of IIA, MR imaging and FIGO staging had overall accuracy of 93.33% and 67.44% respectively.

In the present study, FIGO could not stage any patient \geq IIB, but MRI imaging demonstrated four IIB, one IIIA and two IVA patients and had accuracy of 69.54%, 100% and 96.66% respectively in detecting these stages.

Extension of tumor into lower uterine segment was histologically documented in 17 patients and was demonstrated by MR imaging in 14 patients. It had sensitivity, specificity and accuracy of 64.28%, 50% and 56.61%, respectively.

The sensitivity of MR imaging for detection of vaginal extension in lower third was excellent, there were no false positive and false negative diagnosis giving a predictive value of positive test and negative test of 100%.

In demonstrating parametrial involvement, MR imaging had an accuracy of 93.33%, sensitivity 66.66% and specificity of 100%.

The reported sensitivity, specificity, positive predictive value, negative predictive value and accuracy in the evaluation of bladder and rectal invasion were 100%. The absence of bladder and rectal invasion can be diagnosed with sufficient confidence using MRI (NPV 100%) to safely obviate invasive cystoscopic or endoscopic staging in most patients with cervical cancer. This could potentially lead to a reduction in staging cost and morbidity.

Regarding lymph node, although pelvic node metastases do not change FIGO stage, it is an important prognostic factor. The accuracy of MR imaging in demonstrating LN involvement was 69.56%, sensitivity was 100%, and specificity was 46.15%.

For each modality, the estimated area under the ROC curve was reported. MRI (0.88) was significantly better than FIGO staging (0.68) for staging cervical tumor in Stage IA, as measured by the respective areas under the ROC curves (AUC). In case of Stage IIA, MRI (0.86) also proved to be significantly better than FIGO staging (0.74). These results revealed that MRI staging was more accurate than FIGO staging in diagnosis of invasive cervical carcinoma.

Conclusion

MRI is a complex rapidly evolving modality, although not officially incorporated in the FIGO staging system, is accepted as the most reliable and promising imaging examination for the diagnosis, staging and evaluating of all morphologic cervical cancer, prognostic factors (including parametrial invasion, adjacent organ/tissue invasion, and lymph node metastasis) and is thus capable of providing answers to crucial questions regarding patient's treat.

References

- Nicolate V, Carignan L, Bourdon F, Prosmann O (2000) MR imaging of cervical carcinoma: A practical staging approach. *Radiographics* 20(6): 1539-1549.
- Szklaruk F, Tamm E, Choi H, Varavithya V (2003) MR imaging of common and uncommon pelvic masses. *Radiographics* 23(2): 403-424.
- World Health Organization (2006) "Fact sheet No. 297: Cancer".
- Amendola M, Hrick H, Mitchell DG, Snyder B, Chi DS, et al. (2005) Utilization of diagnostic studies in the pretreatment evaluation of cervical cancer in the United States: Results of intergroup protocol ACORN 6651/ GOG 183. *J Clin Oncol* 23(30): 7454-7459.
- Hricak H, Lacey CG, Sandles LG, Chang YCF, Winkler ML, et al. (1988) Invasive cervical carcinoma: comparison of MR imaging and surgical findings. *Radiology* 166(3): 623-631.
- Chung H, Kang S, Cho J, Kim J, Lee H, et al. (2007) Can preoperative MRI accurately evaluate nodal and parametrial invasion in early stage cervical cancer? *J Clin Oncol* 37(5): 370-375.
- Togashi K, Nishimura K, Sagoh T, Minami S, Noma S, et al. (1989) Carcinoma of cervix: Staging with MRI imaging. *Radiology* 171(1): 245-251.
- Sala E, Wakely E, Senior E, Lomas D (2007) MRI of malignant neoplasms of the uterine corpus and cervix. *AJR Am J Roentgenol* 188(6): 1577-1587.
- Sironi S, Belloni C, Taccagni G, Delmaschio A (1991) Carcinoma of the cervix: Value of MR imaging in detecting parametrial involvement. *AJR Am J Roentgenol* 156(4): 753-756.
- Rubens D, Thornbury JR, Angel C, Stoler MH, Weiss SL, et al. (1988) Stage IB cervical carcinoma: comparison of clinical, MR, and pathologic staging. *AJR Am J Roentgenol* 150(1): 135-138.
- Rockall AG, Ghosh S, Alexander-Sefre F, Babar S, Younis MT, et al. (2006) Can MRI rule out bladder and rectal invasion in cervical cancer to help select patients for limited EUA? *Gynecol Oncol* 101(2): 244-249.
- Greco A, Mason P, Leung AW, Dische S, McIndoe GA, et al. (1989) Staging of carcinoma of the uterine cervix: MRI-surgical correlation. *Clin Radiol* 40(4): 401-405.
- Hyuck J, Serung H, San-Soo, Kang S, Lee S, et al. (2006) MRI for pretreatment lymphnode staging in uterine cervical cancer. *AJR Am J Roentgenol* 187(5): 538-543.