



**Case Report**

Volume 1 Issue 5 – November 2016  
DOI: 10.19080/JOCCT.2016.01.555574

J Cardiol & Cardiovasc Ther

Copyright © All rights are reserved by Kenichi Chatani

# Sequential Observation of Angio-Seal™-Induced Acute Limb Ischemia via Angiography and Intravascular ultrasound

**Kenichi Chatani<sup>1\*</sup>, Yoshihiro J Akashi<sup>1</sup>, Yasuhiro Tanabe<sup>1</sup>, Yuki Ishibashi<sup>1</sup>, Hiroshi Yamazaki<sup>1</sup>, Mizuho Kasahara<sup>1</sup>, Hisashi Ishimaru<sup>2</sup> and Masahiro Nauchi<sup>3</sup>**

<sup>1</sup>Department of Cardiology, St. Marianna University School of Medicine, Japan

<sup>2</sup>Department of Cardiology, AOI universal hospital, Japan

<sup>3</sup>Department of Cardiology, Saiseikai yokohama city eastern hospital, Japan

**Submission:** October 20, 2016; **Published:** November 02, 2016

**\*Corresponding author:** Kenichi Chatani, Department of Cardiology, St. Marianna University School of Medicine, 2-16-1 Sugao Miyamae, Kawasaki, Kanagawa 216-8511, Japan, Tel: 044-977-8111; E-mail: chatani.kenichi@gmail.com

## Abstract

Femoral artery stenosis and occlusions are relatively common following the use of Angio-Seal™ devices compared with other vascular closure devices (VCDs). This study reports the first such case that we could observe the absorption of the collagen plug one year after balloon angioplasty for Angio-Seal™-induced acute limb ischemia in the angiographic and IVUS finding. A 66-year-old male with effort-induced angina pectoris underwent percutaneous coronary intervention (PCI) for severe stenosis of the proximal left anterior descending artery (LAD) through a right femoral artery access. A 7 Fr, 11 cm sheath was inserted through the right femoral artery. The puncture site was closed with an 8 Fr Angio-Seal™ device after the completion of the PCI. Patient's right popliteal artery and dorsalis pedis artery became impalpable about one hour after the procedure.

Emergency angiography revealed subtotal occlusion (99%) of the proximal right superficial femoral artery (SFA). Emergency endovascular treatment of the right SFA was performed through a left femoral artery access. Balloon dilatation was performed with a 5.0 × 40-mm balloon resulting in improvement of antegrade flow. Severe stenosis persisted (area stenosis rate was 85%) immediately after EVT. Follow-up IVUS and angiography one year after procedure demonstrated gradual absorption of the collagen plug, with a reduction in vessel stenosis and symptomatic improvement. These findings suggest that balloon dilatation and close monitoring constitute an effective strategy for the management of Angio-Seal™-induced acute limb ischemia.

**Keywords:** Peripheral Intervention; Acute Limb Ischemia; Complication: Vascular Access; Balloon Angioplasty

**Abbreviations:** IVUS: Intravascular Ultrasound; EVT: Endovascular Therapy ; SFA: Superficial Femoral Artery; VCDs: Vascular Closure Devices; LAD: Left Anterior Descending Artery; PCI: Percutaneous Coronary Intervention; ABI: Ankle-Brachial Index

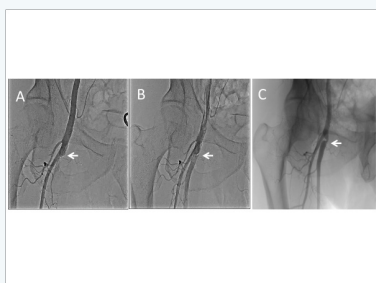## Introduction

Vascular closure devices (VCDs) are commonly used following trans-femoral interventions to achieve immediate hemostasis. Femoral artery stenosis and occlusions are relatively common following the use of Angio-Seal™ devices (St. Jude Medical, Austin, Texas). However, acute limb ischemia accompanying such instances is a rare but serious complication. Conventionally, this complication is managed by surgical revascularization or endovascular therapy (EVT). It is a problem for EVT that the component of the Angio-Seal™ remains in the blood vessel. Some reports that the intravascular component

of the Angio-Seal™ is absorbed almost completely within 90 days of deployment. The absorption of component of the Angio-Seal™ to vessels in human has not been previously reported. This study reports the first such case that we could observe the absorption of the collagen plug one year after balloon dilatation therapy for Angio-Seal™-induced acute limb ischemia in the angiographic and intravascular ultrasound (IVUS) finding. The absorption of the collagen plug one year after endovascular therapy resulted in the reduction in the stenosis, as well as symptomatic improvement.

## Case Report

A 66-year-old man with hypertension and hyperuricemia was admitted to our hospital for effort-induced chest pain. Coronary angiography revealed severe stenosis in the proximal left anterior descending artery (LAD), and percutaneous coronary intervention (PCI) for an LAD lesion was performed after accessing the right femoral artery. The Ankle-brachial index (ABI) on the right side was 1.1 and on the left side was 1.15. Femoral artery diameter was 7.4 mm on the right side and there was no evidence of any stenosis. Prior to the procedure, he received aspirin (100 mg/day) and clopidogrel (75 mg/day) for seven days. A 7 Fr, 11 cm sheath was inserted into the right femoral artery. Sheath insertion was immediately followed by an intravenous injection of 5000 units of heparin. A drug-eluting stent (24 x 3.5mm) was deployed in the proximal LAD, and the puncture site was closed with an 8 Fr Angio-Seal™ device.

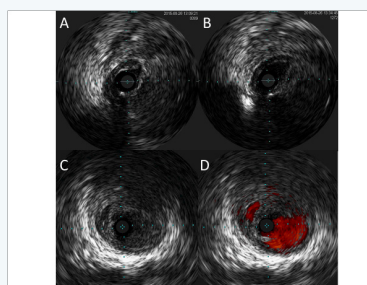


**Figure 1:** Angiographic images of the right femoral artery, before, just after and one year after endovascular therapy (EVT) with balloon dilatation.

- Initial angiography revealed a sub-total occlusion of the proximal superficial femoral artery (SFA).
- Angiography just after-balloon dilatation with 5.0 × 40 mm balloon demonstrated residual stenosis of the proximal SFA (white arrow) as well as antegrade flow.
- Angiography after one year following EVT demonstrated 50 % residual stenosis of the proximal SFA (white arrow).

The patient complained of pain in the right calf and a feeling of coldness in the tips of his toes, one hour following the procedure. Examination revealed impalpable right popliteal and dorsalis pedis artery. Emergency angiography, performed through the left femoral artery revealed subtotal occlusion (99%) of the proximal right superficial femoral artery (SFA) (Figure 1). Emergency endovascular therapy (EVT) of the right SFA was performed through a left femoral artery access. A 0.014 guidewire (Cruise™, Asahi Intecc Co. Ltd., Aichi, Japan) was passed across the lesion. Intravascular ultrasound (IVUS; Vision PV™ 018, Volcano Co. Ltd., San Diego, CA, USA) demonstrated the collagen plug of the Angio-Seal™ present intraluminally (Figure 2). Balloon dilatation was performed with a 5.0 × 40 mm balloon catheter with a long inflation time of up to 2 minutes. Post-dilatation IVUS demonstrated that the SFA diameter was 2.0 × 5.0 mm, which appeared to be insufficient for perfusion (Figure 2), and severe stenosis of the right proximal SFA persisted.

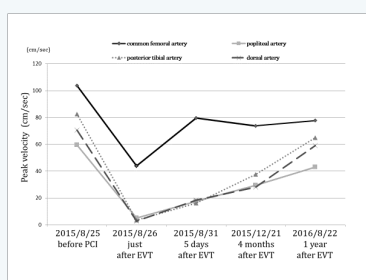
However, since there was an improvement in the antegrade flow, the procedure was terminated (Figure 1b). The patient reported relief of calf pain, and increased warmth in the periphery of his right foot immediately following the procedure. However, he complained of intermittent claudication. B-mode sonography performed five days after EVT identified the intraluminal collagen plug as a hypoechoic lesion and measured the diameter percent stenosis as 85%.



**Figure 2:** Intravascular ultrasound (IVUS) images of the right femoral artery before and just after and one year after endovascular therapy (EVT) with balloon dilatation.

- Initial IVUS revealed intraluminal location of the collagen plug as a hypoechoic image at 5 o'clock position and significant narrowing of the proximal superficial femoral artery (SFA).
- IVUS just after EVT revealed dilated lumen with an oval appearance along with severe residual stenosis in the proximal SFA. The diameter of the minimum lumen was 2.0×4.0mm.
- IVUS after one year following EVT revealed more dilated lumen along with moderate residual stenosis in the proximal SFA. The diameter of the minimum lumen was 4.0×5.0mm.
- IVUS with ChromaFlo™ revealed more dilated lumen along with double lumen in the proximal SFA.

Following EVT, the patient was started on anticoagulant treatment with apixaban (20 mg/day), in addition to double antiplatelet therapy with aspirin and clopidogrel. Apixaban was stopped two months after EVT, while aspirin (100 mg/day) and clopidogrel (75 mg/day) were continued. Four months after the procedure, he no longer complained of intermittent claudication. His ABI on the right side improved from 0.47 just after EVT to 0.98 at about one year following the procedure. On lower extremity artery echography, the peak velocity improved in the popliteal artery (from 17.5 cm/s [5 days following EVT] to 43.0 cm/s [about 1 year following EVT]), posterior tibial artery (from 16.2 cm/s to 65.0 cm/s), and in the dorsalis pedis artery (18.5 cm/s to 59.1 cm/s) (Figure 3). Angiography demonstrated 50 % residual stenosis of the proximal SFA about one year after EVT (Figure 1). Follow up IVUS about one year after EVT revealed more dilated lumen along with moderate residual stenosis in the proximal SFA and the diameter of the minimum lumen was 4.0×5.0mm (Figure 2). Follow up IVUS with ChromaFlo™ revealed more dilated lumen along with double lumen in the proximal SFA one year after EVT (Figure 2).



**Figure 3:** The progress of peak systolic velocity of right common femoral artery, popliteal artery, posterior tibial artery and dorsal artery on the lower extremity artery echography. Lower extremity artery echography demonstrated normal peak velocity before percutaneous coronary intervention (PCI). The peak velocity just after endovascular therapy (EVT) was less than 10 cm/s in the popliteal, posterior tibial, and dorsalis pedis arteries. Echography five days after EVT demonstrated improved peak velocity. Echography one year later demonstrated further improvement in the peak velocity.

## Discussion

Hemorrhage, *pseudoaneurysm*, infection and vessel occlusion are uncommon complications following the use of Angio-Seal™ devices. Although femoral artery stenosis or occlusion following VCDs is rare, with the incidence of such complications ranging from 0 to 2.9% [1], they are relatively common with the Angio-Seal™ device compared with other devices (Vaso-Seal™, St Jude Medical Co. Ltd., St. Paul, MN, USA or Techstar™, Abbot Vascular Japan Co. Ltd., Calif, USA) [2]. Since acute limb ischemia or leg necrosis may follow Angio-Seal™ device-induced femoral artery stenosis or occlusion, this is a serious complication. In the present case, a technical difficulty was encountered during deployment of the Angio-Seal device. The collagen plug could not be easily inserted subcutaneously in spite of applying pressure with the tamper tube. Therefore, it was forcibly positioned with the aid of an inserter (PCI accessory device).

The collagen plug may have been forced into the vessel lumen during these unplanned maneuvers, resulting in superficial femoral artery (SFA) occlusion and thus, acute limb ischemia. This was confirmed by both, the IVUS and the lower extremity artery echography, which demonstrated the intraluminal location of the collagen plug. The SFA diameter of 6 mm was adequate for the deployment of the Angio-Seal™ device [3]. However, this complication could be largely attributed to the low position of the SFA puncture and the forcible insertion of the collagen plug. The intravascular anchor of the Angio-Seal™ is expected to be absorbed with complete dissolution in about 30 days as observed on microscopy, and in 90 days as observed on chemical analysis [4]. Tellez et al reports that the intravascular component of the Angio-Seal™ is absorbed almost completely within 42 days of deployment as observed on IVUS [5]. In the present case, about half of the anchor and collagen plug were

absorbed over one year, resulting in a reduction in the stenosis, as well as symptomatic improvement. The patient continued to have residual stenosis and it was difficult to predict a further reduction in the size of the collagen plug. In cases like this, however, it is important to continue close monitoring of the patient in anticipation of SFA restenosis or distal embolism.

## Conclusion

There are some reports describing surgical revascularization for Angio-Seal™-induced femoral artery stenosis or occlusion [6]. Surgical treatment must be considered for occlusions involving large thrombus. In addition, stenting should be considered in cases where balloon dilatation fails to open up the occlusion. In the case of our patient, balloon dilatation alone provided relief of acute limb ischemia. First, balloon dilatation achieved good antegrade flow even in the absence of complete revascularization of the SFA. Second, conservative therapy was followed by the absorption of the collagen plug of the Angio-Seal™ device as confirmed by B-mode ultrasonography performed four months following EVT. Balloon dilatation and close monitoring are less invasive compared to surgical treatment; thus, this combination is a useful strategy in the management of Angio-Seal™-induced acute limb ischemia. It is important to consider the additional reasons that could have contributed to the favorable response of our patient to balloon dilatation alone. First, early detection of acute limb ischemia resulted in emergency EVT without much delay. Second, sub-total occlusion of the SFA instead of complete occlusion may have enabled better antegrade blood flow following EVT. Third, the patient received anticoagulation with apixaban in addition to double antiplatelet therapy to avoid thrombus formation.

## References

- Nikolsky E, Mehran R, Halkin A, Aymong ED, Mintz GS, et al. (2004) Vascular complications associated with arteriotomy closure devices in patients undergoing percutaneous coronary procedures: a meta-analysis. *J Am Coll Cardiol* 44(6): 1200-1209.
- Carey D, Martin JR, Moore CA, Valentine MC, Nygaard TW (2001) Complications of femoral artery closure devices. *Catheter Cardiovasc Interv* 52(1): 3-7.
- Abando A, Hood D, Weaver F, Katz S (2004) The use of the Angioseal device for femoral artery closure. *J Vasc Surg* 40(2): 287-290.
- Felicita Andreottia, Alberto Lavorgnaa, Giulio Coluzzia, Claudio Vincenzonib, Antonio G Rebuzzi (2007) Lost and found: an unusual late complication of the Angio-Seal closure device. *Int J Cardiol* 117(1): e1-e3.
- Tellez A, Cheng Y, Yi GH, Conditt GB, McGregor JC, et al. (2010) In vivo intravascular ultrasound analysis of the absorption rate of the Angio-seal vascular closure device in the porcine femoral artery. *EuroIntervention* 5(6): 731-736.
- Sung-Min Park, Young-Tae Kwak (2008) Femoral artery occlusion after using a suture-mediated arterial puncture closure device. *Catheterization and Cardiovascular Interventions* 72(4): 522-524.

**Your next submission with JuniperPublishers  
will reach you the below assets**

- Quality Editorial service
- Swift Peer Review
- Reprints availability
- E-prints Service
- Manuscript Podcast for convenient understanding
- Global attainment for your research
- Manuscript accessibility in different formats  
( Pdf, E-pub, Full Text, Audio)
- Unceasing customer service

**Track the below URL for one-step submission  
<http://juniperpublishers.com/online-submission.php>**