



Research Article

Volume 2 Issue 1 – November 2016  
DOI: 10.19080/JOCCT.2016.02.555580

J Cardiol & Cardiovasc Ther

Copyright © All rights are reserved by Mehdi Ghaderian

# Medium term Follow up Treatment of Severe Native Coarctation of Aorta Using of Balloon Angioplasty in Young Infants Less Than one Year's age

Mehdi Ghaderian<sup>1\*</sup> and Mojdeh Gheysari<sup>2</sup>

<sup>1</sup>Assistant professor of Pediatric Cardiology, Department of Pediatric Cardiology, Child Growth and Development Research Center, Isfahan University of Medical Sciences, Iran

<sup>2</sup>Medical student, Department of Pediatric Cardiology, Child Growth and Development Research Center, Isfahan University of Medical Sciences, Iran

**Submission:** November 05, 2016; **Published:** November 22, 2016

**\*Corresponding author:** Mehdi Ghaderian, Assistant professor of Pediatric Cardiology, Department of Pediatric Cardiology, Child Growth and Development Research Center, Isfahan University of Medical Sciences, Iran.

## Abstract

**Background:** The spectrum of therapeutic approaches for the treatment of native aortic coarctation has widely expanded from surgical correction to balloon angioplasty (BA) and stent implantation. The aim of this study to assess the safety and efficacy of BA for native CoA therapy in infants less than one year' sold age.

**Method:** Sixteen patients (10 male) with discrete COA underwent BA of COA between May 2014 and May 2015 at our center. The age ranged from 23 days to 10 months (mean  $4.28 \pm 2.84$  m) and body weight ranged from 3 to 7 kg (mean  $4.76 \pm 1.33$  kg). Appropriate balloons (mean  $6.18 \pm 0.91$  mm) were choosedand were inflated 2-3 times under fluoroscopic guidance. Successful outcome was defined as peak systolic pressure gradient after balloon angioplasty  $< 20$  mm Hg or decreased by more than 50% and at least 50% increase in diameter. Follow-up duration was  $6.0 \pm 3.0$  months (1-12 months).

**Result:** The mean value of the peak-to-peak systolic pressure gradient between ascending to descending aorta significantly decreased from  $48.43 \pm 11.65$  mmHg (range 25-65 mmHg) to  $11.43 \pm 8.29$  mmHg (range 0-30 mmHg) ( $P < 0.001$ ). Echocardiographic peak and mean pressure gradients decreased significantly from  $58.81 \pm 11.15$  and  $30.56 \pm 6.51$  before of procedure to  $23.06 \pm 11.75$  and  $12.31 \pm 6.86$  mmHg during follow-up respectively ( $P < 0.001$ ).

**Conclusion:** For native discrete aortic coarctation in young infants  $< 12$  months of age percutaneous BA is a safe and effective treatment alternative to surgical approach.

**Keywords:** Balloon angioplasty; Coarctation of aorta; Congenital heart disease

**Abbreviations:** BA: Balloon Angioplasty; COA: Coarctation of Aorta; TTE: Transthoracic Echocardiography; ECG: Electrocardiogram; VSD: Ventricular Septal Defect; CGDRC: Child Growth and developmental Research Center

## Introduction

Coarctation of aorta (COA) is a common congenital cardiovascular defect that defined a stenosis or occlusion of the aorta, usually located in the region of the ligamentum arteriosum after the left subclavian artery origin [1]. It can be diagnosed over a wide range of ages during neonatal to senile and with varying degrees of severity from asymptomatic to severe heart failure. This defect accounts for approximately four in 10,000 live births, which corresponds to 5-8% of all congenital heart defects and may occurs as an isolation or in association with

other cardiac defects, most commonly ventricular septal defect and bicuspid aortic valve. COA diagnosis may be missed delayed until the patient has developed congestive heart failure, which is common in infants, or hypertension, that is common after this time during the life. Most often coarctation of aorta diagnosed during the first months of age because of its symptoms. In the literature two types of COA have been described: postductal (or adult) and preductal (or infantile), depending on whether the coarctation segment is distal or proximal to the ductus arteriosus, respectively [2].

The spectrum of therapeutic approaches for the treatment of native aortic coarctation has widely expanded over the past sixty years. For the first time by Crafoord in 1944 surgical repair of aortic coarctation was performed. Many surgical techniques have been used for coarctation repair, and each of them had advantages and disadvantages. Percutaneous balloon angioplasty is a less invasive alternative approach to surgical technique for treatment of patients with a discrete coarctation of aorta. It has been used for coarctation treatment since 1982 and less acceptable for safety and effectiveness in patients with native coarctation [3]. For the treatment of choice for re-coarctation after previous surgical repair balloon angioplasty (BA) is widely accepted among intervention a list to be in as much as its morbidity is lower and its higher success rate in comparison with repeat surgery [4].

It remains controversial for a primary treatment approach for a native coarctation of aorta [5]. Balloon angioplasty technique involves expansion of the constricted segment site that results in rupture of the intima and injury of the media. Less favorable outcomes have been described in patients with aortic arch hypoplasia or long segment coarctation compared to discrete type of coarctation. Complications after balloon angioplasty include injury at the femoral or other percutaneous access site, restenosis or recoil and damage of the aortic wall resulting in aortic aneurysm formation. Balloon-expandable stents provide an effective and safe therapy for many patients with coarctation of aorta after early ages. Stents decrease restenosis after procedure related to vessel recoil and diminish the incidence of aneurysm formation and reduces the resting systolic gradient to less than 5 mmHg [6,7].

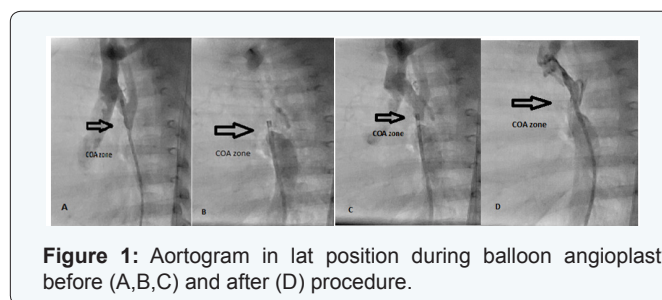
Stent implantation initially was used only for cases that balloon angioplasty and surgery had failed but in patients with stent implantation several re-dilations may be required until the patient is fully grown to adult age [7,8]. Therefore balloon angioplasty is preferred in children less than 10 year's old age or 20 kg and in this group this technique had special difficulty and experience for performing and successful. The purpose of this study was to evaluate safety and efficacy mid-term follow-up results of balloon angioplasty for treatment of native coarctation of aorta during May 2014 to May 2015 in patients less than one year's old age in our center.

### Methods

Sixteen patients with discrete COA underwent transcatheter balloon angioplasty of COA between May 2014 and May 2015 at Shahid Chamran cardiovascular heart center of Esfahan University of medical science. Ten patients were male and six were female. The age ranged from 23 days to 10 months (mean  $4.28 \pm 2.84$  m) and body weight ranged from 3 to 7 kg (mean  $4.76 \pm 1.33$  kg). Before procedure, all patients were examined clinically by pediatric cardiologist and underwent transthoracic echocardiography (TTE), 12 lead electrocardiogram (ECG), and

chest radiography. Clinically, all 16 patients presented with ranges of heart failure and decreased ejection fraction and cardiac function. Among these 16 patients, 6 had an isolated CoA, including two patients with lowest age diagnosed with dilated cardiomyopathy, mild endocardial fibroelastosis, before being referred to our hospital.

The other 10 patients presented with other cardiac defects, including ventricular septal defect (VSD) in 3, atrial septal defect in 2, and patent ductus arteriosus in 3, bicuspid aortic valves in 1 patient and tassign-bing malformation in one. For patient with a CoA and tassign-bing malformation balloon angioplasty was performed for increasing of ejection fraction and one week later transferred to operating room subsequently. In patients with small VSD only balloon angioplasty were performed and in one patient with large VSD at first balloon angioplasty and then surgical correction were performed. All of the procedures were performed under deep sedation, and endovascular balloon angioplasty was performed via a retrograde femoral artery approach and standard catheterization technique. Arterial pressure was monitored persistently during the procedure. Coarctation of the aorta was defined as systolic pressure gradient  $\geq 20$  mm Hg between ascending and descending aorta or echocardiographic or angiographic evidence of COA.



**Figure 1:** Aortogram in lat position during balloon angioplasty before (A,B,C) and after (D) procedure.

A 4 or 5 (11 and 7 cm in length) French introducer sheath was initially used and according to balloon size changed during the procedure. A 4 French end and side holes catheter was passed gently across the coarctation site retrogradely and the pressure of ascending aorta and descending aorta were measured and pressure gradient was estimated. After aortogram in lateral or LAO position, size and position of coarctation was distinguished and an appropriate balloon equal to aortic size at diaphragmatic size or equal to or 1-2 mm greater than the diameter of the aortic arch at or proximal to the level of the left subclavian artery no larger than 3 times as narrowest size of coarctation site was chosen. Mean sizes of balloons were (mean  $6.18 \pm 0.91$  mm), range from 5-8 mm. It passed across the coarctation site over a floppy tip guide wire that inserted in the ascending aorta or right subclavian artery. The balloon was inflated 2-3 times under fluoroscopic guidance for each patient by second intervention a list under the pressure recommended by the manufacturer. If a residual waist or high pressure gradient were seen at the coarctation zone, another 1-2 mm larger balloon was selected to dilate the coarctation within the same protocol. After the

procedure aortography was performed for more evaluation (Figure 1).

Successful outcome was defined as peak systolic pressure gradient after balloon angioplasty < 20 mm Hg or decreased by more than 50% and at least 50% increase in diameter at the coarctation segment. Anticoagulation with heparin (50-100U/kg) was administered after vascular access was achieved and it was repeated during the procedure after one hour. Follow-up duration was 6.0 ± 3.0 months (1-12 months). Follow-up concentrated on examination with special attention to systolic blood pressure gradient, blood pressure and regular echocardiogram after procedure. Statistical significance was evaluated utilizing the paired t-test for paired data such as pre and post procedure mean values of the peak-to-peak systolic gradient between ascending to descending aorta. A p value < 0.05 was considered statistically significant. The interval data are expressed as mean ± standard deviation. All the data analyses were conducted using SPSS version 18.0.

**Results**

In 3 patients two sequential balloon dilations were performed, and in the other patient’s one balloon dilation was performed. In two patients with ages lower than one month’s (23 and 25 days old age) and severe coarctation and decreased ejection fraction and heart failure, the catheterization gradient before the procedure was approximately 60 mmHg. After procedure, the pressure gradient decreased to 10 and 30 mm Hg, and showed significant increasing in cardiac function. In this two patients another procedure were performed 4 and 6 months later because of increasing gradient and recoiling of coarctation. In one of these patients after first procedure gradient increased from 10 to 40 mm Hg and by second procedure pressure gradient decreased to 5 mm Hg and did not increased during follow-up. Another patient had increased pressure gradient and in second time we could not passed from coarctation zone because of severe constriction and she referred for surgical correction.

**Table 1:** Pressure gradients before and after balloon angioplasty.

Variants	Pre procedure	Post procedure	P-Value
PPG in angiography (mmHg)	48.43 ± 11.65 (range 25–65)	11.43 ± 8.29	< 0.001
PPG in echocardiography (mmHg)	58.81 ± 11.15	23.06 ± 11.75	<0.001
MPG in echocardiography (mmHg)	30.56 ± 6.51	12.31 ± 6.86	<0.001

PPG: Peak Pressure Gradient; MPG: Mean Pressure Gradient

The mean value of the peak-to-peak systolic pressure gradient between ascending to descending aorta significantly decreased from 48.43 ± 11.65 mmHg (range 25-65 mmHg) to 11.43 ± 8.29 mmHg (range 0-30 mmHg) (P < 0.001) at the

end of procedure (Table 1). A residual gradient of greater than 20 mmHg was acceptable in the presence of an increase at least two fold in the coarctation zone diameter. There were no immediate complications during balloon angioplasty and need for emergency surgery. During or post balloon angioplasty, no angiographic complications such as retroperitoneal hematoma secondary to bleeding from the external iliac artery, aneurism formation, arterial dissection, aortic rupture, and arteriovenous fistulas were evident by repeat echocardiography, catheterization, or CT-angiography. There were no deaths related to the procedure. None of patients has need for blood transfusion. 3 patients had decreased femoral pulsation and by using heparin pulses were returned normally during the first 24 hours. Regular echocardiography was performed the day after procedure, one month, 3 months and six months later and yearly in future. During the follow-up 1 month to 12 months follow up period (mean 6.0 ± 3.0 months) we had not complication. Echocardiographic peak pressure gradient and mean pressure gradient decreased significantly from 58.81 ± 11.15 and 30.56 ± 6.51 before of procedure to 23.06 ± 11.75 and 12.31 ± 6.86 mm Hg during follow-up respectively (P<0.001).

**Discussion**

Balloon angioplasty was first used in infants and neonates with coarctation of aorta and heart failure that were at a higher risk for surgery than interventional approach, but its indications were later extended to include older children, adolescents and other ages as well [9-11]. Complications such as aneurysm formation and re CoA have been associated with both balloon angioplasty and surgical repair have been reported during the past decades and it making difficult to decide any meaningful conclusions as to which treatment option is superior to other one. Aortic dissection and aortic aneurysm formation and aortic rupture occurred in about less than 10% of patients at the site of repair late after operation [12,13]. The risk of re CoA after surgery in young children ranges from 44% to 11% in neonates to older children, and whatever the patient had younger age the risk is higher [14].

For the baseline probabilities of successful treatment, aneurismal formation, re CoA and other complications, Wong et al reviewed articles and he reported that BA was preferred over surgery for all plausible situations as the initial treatment for native CoA in children (15). Repeated intervention rate was high especially in patients treated with balloon angioplasty during infancy and younger age. The success rate immediately after procedure in our study was 93% (15 patients), that was concordant with other studies in which the early success rate in infants less than 3 months ranged greater than 88% [16-19]. In follow-up period (1m to one year) two patients developed rest enosis and pressure gradient in echocardiography and needed a second BA. One of these patients resolved via repeated balloon dilation without surgery. Other patient had youngest age (23 days) among our patients and had dilated LV and critical posture

at admission but after procedure her gradient was decreased and her ejection fraction was increased and during follow-up her gradient was increased and because of unsuccessful procedure she was referred to the surgeon.

We guess that her condition and small balloon choosing in first procedure occasion to re-CoA and progressing of her gradient. Restenosis rate was reported in previous reports, in infants younger than 12 months ranged from 25% to 71% [14,15] and in this study we had 12.5% rest enosis among our patients that which was lower than other studies, but longer follow-up is need for better results. BA has the best results in patients with developed and good size aortic arch and discrete CoA, and in these patients further restenosis of the CoA zone can be managed by repeat procedure. An aneurysm formation has been reported, immediately or lately during the follow-up and it occurs less than 6% in BA [20-22]. Aneurysms may not change in size for a long duration of time during life and it may be not require immediate treatment for long time. He L reported that 5.4% percent of their patients developed aneurysmal formation and disappeared during the 18 month follow-up and they had not any late aneurysm formation in their study [23]. We had not any immediate aneurysmal formation among our patients and we think that oversize balloon choosing and smaller children are risk factors for inducing of this complication and longer duration of follow-up is needed for further results. In patient with a CoA and tassing-bing malformation balloon angioplasty was performed at first and one week later transferred to operating room subsequently with better condition.

In patients with other associated congenital heart defects such as VSD experience and policy of that center are important to treatment of these patients. He L reported that they used balloon for CoA treatment and patients with large non-restricted VSD underwent surgical repair on the same day or within 1 week [23]. We had the same policy and think that it's better because of low risk complications such as phrenic nerve palsy, delayed sternal closure, and wound infection. Femoral artery complications such as occlusion and aneurysm are the most commonly reported artery complications in young infants especially in younger infants and neonates [24]. Using of smaller sheath and administering of heparin during the procedure and short time of procedure are help to reduce these complications. We used 4 F sheaths for beginning of procedure and during the procedure change it with 5F short sheaths (7cm in length) if need and if had suspicious to reduce flow to lower limb, heparin was administrated during the first 24 h after procedure, and we did not see these complications in our patients.

In neonatal period and severe coarctation of aorta especially lower weight smaller balloon such as coronary balloon using for the first time and then in follow-up redilation of coarctation with larger balloon at older age was recommended [24]. In our center we use smaller balloon with low profile that need smaller

sheath and passing easily from CoA zone at the first time and if need in follow-up larger balloon help us for reducing the pressure gradient (staging procedure) and this process avoid aneurysm formation and artery complications in smaller infants. A limitation of our study is its small size and short term follow-up. It had been better that we compared these patients with matched group that threatened with surgical approach and long term follow-up and complications.

In conclusion, for native discrete aortic coarctation in young infants <12 months of age percutaneous BA is a safe and effective treatment. Smaller sheath, low profile balloon using and staging procedure in BA are recommended for reducing complications. However, long term close follow up is essential for these patients that treated with BA to observe and treat late aneurysms and restenosis. Large groups of patients and longer duration of follow-up need for confirmation of these reports.

## Acknowledgment

This study was approved and supported by Child Growth and developmental Research Center (CGDRC), Esfahan University of Medical Sciences, Esfahan, Iran. This paper was extracted from the thesis of Dr. Modjdeh Gheisari.

## References

1. Rao PS (2005) Coarctation of the aorta. *Curr Cardiol Rep* 7(6): 425-434.
2. Mortazaeian H, Moghadam MY, Ghaderian M, Davary PN, Meraji M (2010) Evaluation of exercise-induced hypertension post endovascular stenting of coarctation of aorta. *J Tehran Heart Cent* 5(3): 137-140.
3. Fawzy ME, Fathaala A, Osman A, Badr A, Mostafa MA, et al. (2008) Twenty-two years of follow-up results of balloon angioplasty for discret native coarctation of the aorta in adolescents and adults. *Am heart J* 156(5): 910-917.
4. Reich O, Tax P, Bartáková H, Tomek V, Gilík J, et al. (2008) Long-term (up to 20 years) results of percutaneous balloon angioplasty of recurrent aortic coarctation without use of stents. *Eur Heart J* 29(16): 2042-2048.
5. Hellenbrand WE, Allen HD, Golinko RJ, Hagler DJ, Lutin W, et al. (1990) Balloon angioplasty for aortic recoarctation: results of the valvuloplasty and angioplasty of congenital anomalies registry. *Am J Cardiol* 65(11): 793-797.
6. Wheatley GH, Koullias GJ, Rodriguez-Lopez JA, Ramaiah VG, Diethrich EB (2010) Is endovascular repair the new gold standard for primary adult coarctation? *Eur J Cardiothorac Surg* 38(3): 305-310.
7. Rosenthal E, Qureshi SA, Tynan M (1995) Stent implantation for aortic re-coarctation. *Am Heart J* 129: 1220-1221.
8. Qureshi SA (2007) Stenting in aortic coarctation and transverse arch/isthmus hypoplasia. In: Sievert H, Qureshi SA, Wilson N, Hijazi ZM (Eds), *Percutaneous Interventions for Congenital Heart Disease*. Informa Healthcare, London, UK, pp 475-486.
9. Singer MI, Rowen M, Dorsey TJ (1982) Transluminal aortic balloon angioplasty for coarctation of the aorta in the newborn. *Am. Heart J* 103(1): 131-132.
10. Finley JP, Beaulieu RG, Nanton MA, Roy DL (1983) Balloon catheter dilatation of coarctation of the aorta in young infants. *Br Heart J* 50(5): 411-415.

11. Lababidi Z (1983) Neonatal transluminal balloon coarctation angioplasty. *Am Heart J* 106(4 Pt 1): 752-753.
12. Toro Salazar OH, Steinberger J, Thomas W, Rocchini AP, Carpenter B, et al. (2002) Long term follow up of patients after coarctation of the aorta repair. *Am J Cardiol* 89(5): 541-547.
13. Cramer JW, Ginde S, Bartz PJ, Tweddell JS, Litwin SB, et al. (2013) Aortic aneurysms remain a significant source of morbidity and mortality after use of Dacron (®) patch aortoplasty to repair coarctation of the aorta: Results from a single center. *Pediatr Cardiol* 34(2): 296-301.
14. Vriend JW, Mulder BJ (2005) Late complications in patients after repair of aortic coarctation: Implications for management. *Int J Cardiol* 101(3): 399-406.
15. Wong D, Benson LN, Van Arsdell GS, Karamlou T, McCrindle BW (2008) Balloon angioplasty is preferred to surgery for aortic coarctation. *Cardiol Young* 18(1): 79-88.
16. Lee CL, Lin JF, Hsieh KS, Lin CC, Huang TC (2007) Balloon angioplasty of native coarctation and comparison of patients younger and older than 3 months. *Circ J* 71(11): 1781-1784.
17. Rao PS, Jureidini SB, Balfour IC, Singh GK, Chen SC (2003) Severe aortic coarctation in infants less than 3 months: Successful palliation by balloon angioplasty. *J Invasive Cardiol* 15(4): 202-208.
18. Patel HT, Madani A, Paris YM, Warner KG, Hijazi ZM (2001) Balloon angioplasty of native coarctation of the aorta in infants and neonates: Is it worth the hassle? *Pediatr Cardiol* 22(1): 53-57.
19. Ammar RI (2012) Balloon angioplasty for native aortic coarctation in children and infants younger than 12 months: Immediate and medium term follow up. *J Invasive Cardiol* 24(12): 662-666.
20. Hu ZP, Wang ZW, Dai XF, Zhan BT, Ren W, et al. (2014) Outcomes of surgical versus balloon angioplasty treatment for native coarctation of the aorta: A meta analysis. *Ann Vasc Surg* 28(2): 394-403.
21. Parra-Bravo JR, Reséndiz-Balderas M, Francisco-Candelario R, García H, Chávez-Fernández MA, et al. (2007) Balloon angioplasty for native aortic coarctation in children younger than 12 months: immediate and medium-term results. *Arch Cardiol Mex* 77(3): 217-225.
22. Massoud Iel S, Farghly HE, Abdul Monem A, Botros N, Kassem A, et al. (2008) Balloon angioplasty for native aortic coarctation in different anatomic variants. *Pediatr Cardiol* 29(3): 521-529.
23. He L, Liu F, Wu L, Qi CH, Zhang LF, et al. (2015) Percutaneous Balloon Angioplasty for Severe Native Aortic Coarctation in Young Infants Less Than 6 Months: Medium- to Long-term Follow-up. *Chin Med J (Engl)* 128(8): 1021-1025.
24. Suárez de Lezo J, Pan M, Romero M, Segura J, Pavlovic D, et al. (2005) Percutaneous interventions on severe coarctation of the aorta: A 21 year experience. *Pediatr Cardiol* 26(2): 176-189.

Your next submission with JuniperPublishers  
will reach you the below assets

- Quality Editorial service
- Swift Peer Review
- Reprints availability
- E-prints Service
- Manuscript Podcast for convenient understanding
- Global attainment for your research
- Manuscript accessibility in different formats  
( Pdf, E-pub, Full Text, Audio)
- Unceasing customer service

Track the below URL for one-step submission

<http://juniperpublishers.com/online-submission.php>