

Case Report

Volume 19 Issue 1 - November 2023
DOI: 10.19080/JOCCT.2023.19.556001

J Cardiol & Cardiovasc Ther

Copyright © All rights are reserved by Dr Ashish Trivedi

Distal Coronary Perforation Managed with a Cut Balloon Tip



Dr Ashish Trivedi*

KEM hospital Pune, Maharashtra, India

Submission: November 01, 2023; **Published:** November 24, 2023

***Corresponding author:** Ashish Trivedi, KEM hospital Pune, 1202,subhash Nagar, Maharashtra, India

Keywords: Coronary artery; Hypokinesia; Cardiac tamponade; Pericardial effusion

Introduction

Coronary artery perforation is a rare but life-threatening complication of percutaneous coronary interventions [1]. Cardiac perforation is a serious complication resulting in pericardial tamponade, which requires immediate intervention. Treatment options for coronary perforation typically involve the utilization of different techniques such as covered stents, coil deployment, and glue embolization. The present case report highlights the successful management of a distal coronary perforation using a novel approach involving the use of a cut balloon tip used to seal the perforation. I We encountered a patient with a distal coronary

perforation during a percutaneous coronary intervention. The perforation occurred when the Fielder FC guide wire inadvertently punctured the vessel wall. This complication posed a significant risk to the patient's life and required immediate attention.

Clinical Examination Findings

A 45-year-old male patient presented with chest discomfort in the last 24 hours and was diagnosed with an evolved inferior myocardial infarction. The troponin I levels were significantly increased.

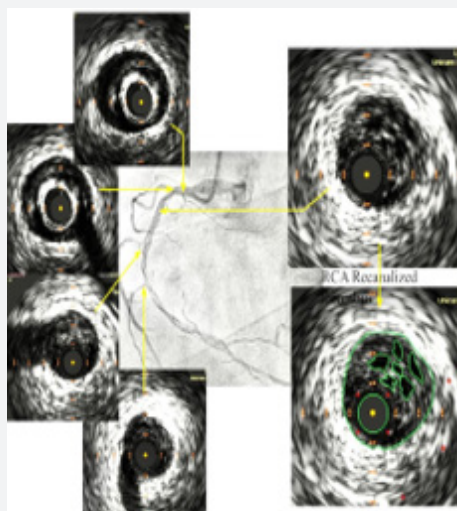


Figure 1: IVUS Image Showing fragmented thrombus.

Diagnostic Tests and Results

2 Echocardiography showed inferior-posterior wall hypokinesia and a left ventricular ejection fraction of 45%. Based on the findings during coronary angiography, it was observed that there were multiple planes of dissection/ fragmented thrombus

in the right coronary artery. The distal right coronary artery was filling retrogradely from the left system. His left anterior descending and left circumflex arteries were normal. Intravascular ultrasound done confirmed the presence of fragmented thrombus & significant stenosis in the RCA (Figure 1 & 2).

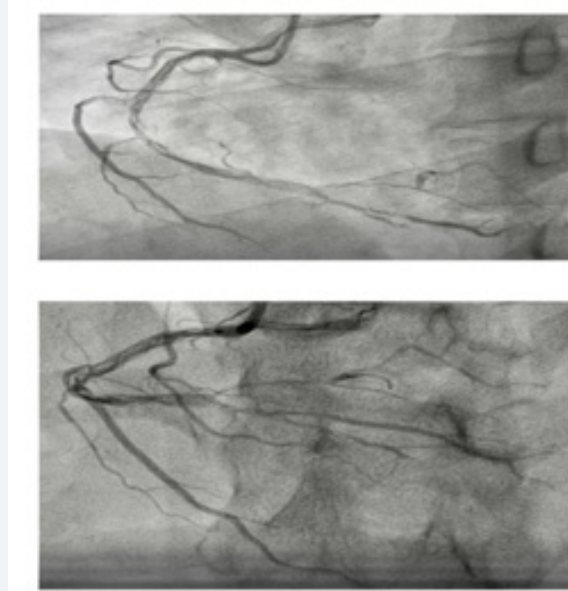


Figure 2: Coronary angiogram of RCA showing multiple planes of dissection/Fragmented thrombus.

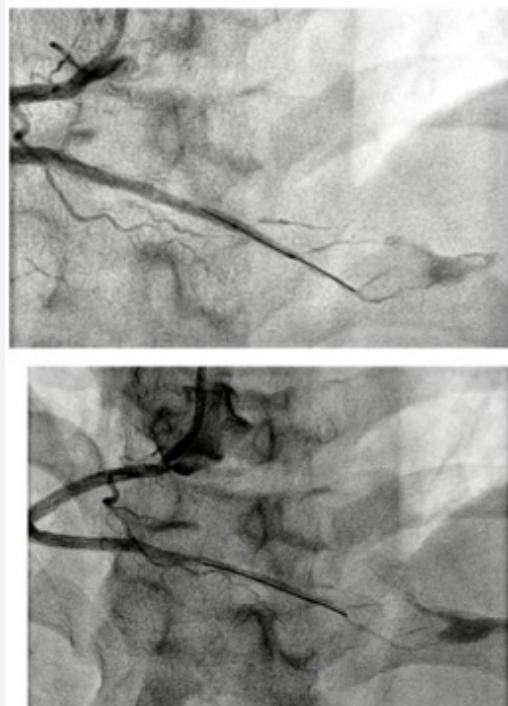


Figure 3: post stent deployment distal vessel perforation.

Proposed Approach for Treatment

Patient was advised to undergo coronary angioplasty; the right coronary artery was cannulated using a 3.5 Judkins right guiding catheter and wired with a Fielder FC guide wire. The lesion in the RCA was then stented with three overlapping stents from the posterior descending artery (PDA) to the proximal RCA. We achieved successful stent expansion and observed TIMI III distal flow. However, we identified a perforation at the far end of the PDA. Initially, we performed balloon dilatation in the PDA using a 2.5 x 15 mm balloon for approximately 7-8 minutes, but subsequent imaging showed sustained leakage of contrast from the PDA. Another round of balloon inflation was attempted, but there was persistent leak. Due to the unavailability of coils or glue

during the procedure and given that the artery size was too small to accommodate a covered stent, our approach for managing this distal coronary perforation involved inserting a guide-plus catheter with balloon support into the distal RCA. Subsequently, we cut and mounted a 1.5 x 10mm balloon tip with a little part of the shaft on a guide wire as; it was then pushed inside using a 2.5 x 15 mm balloon delivery system. Afterward, we retracted both balloon delivery systems along with the guide wire, leaving the cut balloon tip in the distal part of PDA. A follow-up check shoot confirmed the successful sealing of perforation. The patient was hemodynamically stable, on echo screening there was no significant pericardial effusion or cardiac tamponade. The patient was observed in the critical care unit for 48 hours & discharged after 2 days (Figure 3 & 4).

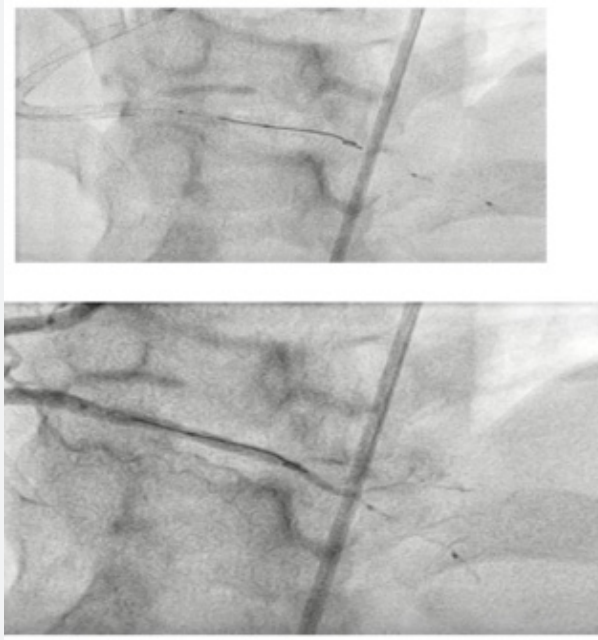


Figure 4: cut balloon tip pushed in distal RCA.

Discussion

This was an urgent effort to close the perforation since we didn't have any micro coils or gelatin swab. Since we had already placed 3 stents, we decided not to use protamine. We used a guide plus catheter for added stability when delivering the cut balloon tip, ensuring that there would be no risk of disengagement or embolization. It is crucial to closely monitor the long-term results of this procedure. The novel approach used in this case successfully sealed the perforation of the distal coronary artery when conventional methods such as prolonged balloon inflation were ineffective. However, it is essential to consider alternative

perspectives and approaches when managing distal coronary perforations. While the use of a guide-plus catheter with a cut balloon tip may have been successful in this case, it is worth exploring other options that have been reported in the literature (Figure 5). The use of vascular occlusion materials such as micro coil or gelatin sponge in cases of distal coronary artery perforation is commonly used. By utilizing these occlusion materials, it may be possible to achieve effective hemostasis without the need for improvising, but we thought of sharing this approach as it proved to be lifesaving in desperate situation. & can rarely be used as bail out strategy. The long-term outcome needs to be monitored closely.

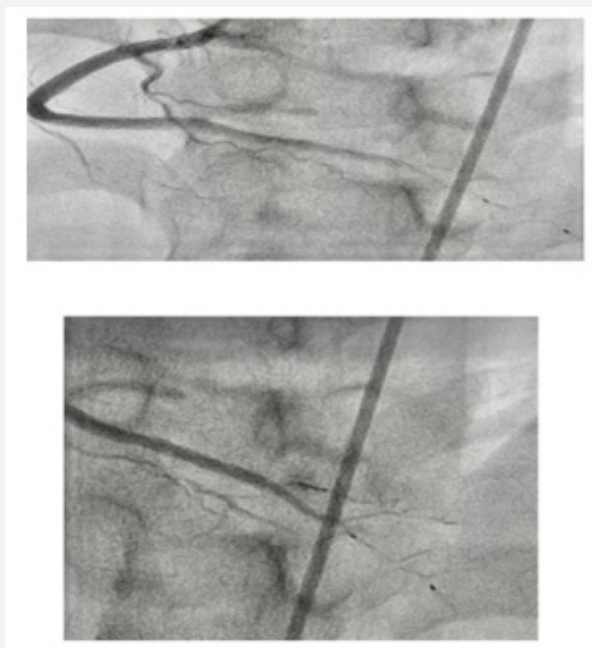


Figure 5: RCA & sealing of perforation.

References

- Kearney PM, Whelton M, Reynolds K, Muntner P, Whelton PK, et al. (2005) Global burden of hypertension: analysis of worldwide data. *The Lancet* 365(9455): 217223.
- The Seventh Report of the Joint National Committee on Prevention, Detection, Evaluation, and Treatment of High Blood Pressure: The JNC 7 Report | Hypertension | JAMA | JAMA.
- Bertrand E, Muna WFT, Diouf SM, Ekra A, Kane A, et al. (2006) [Cardiovascular emergencies in Sub-Saharan Africa]. *Arch Mal Coeur Vaiss* 99(12): 11591165.
- Touze JE (2007) Cardiovascular diseases and the epidemiological transition in tropical regions. *Med Trop (Mars)* 67(6): 541-542.
- Kingue S, Ngoe CN, Menanga AP, Jingi AM, Noubiap JJN, et al. (2015) Prevalence and Risk Factors of Hypertension in Urban Areas of Cameroon: A Nationwide Population-Based Cross-Sectional Study. *J Clin Hypertens* 17(10): 819824.
- Boombhi J, Menanga A, Doualla JP, Hamadou B, Kuate L, et al. (2016) Prévalence et mortalité des maladies cardiovasculaires en milieu hospitalier camerounais: Cas de deux hopitaux de référence de la ville de Yaoundé. *Cardiologie tropicale* 145: 9-16.
- Mandi DG, Yaméogo RA, Sebgo C, Bamouni J, Naibé DT, et al. (2019) Hypertensive crises in sub-Saharan Africa: Clinical profile and short-term outcome in the medical emergencies department of a national referral hospital in Burkina Faso. *Ann Cardiol Angéiol* 68(4): 269274.
- Nkoke C, Noubiap JJ, Dzudie A, Jingi AM, Njume D, et al. (2020) Epidemiology of hypertensive crisis in the Buea Regional Hospital, Cameroon. *J Clin Hypertens (Greenwich)* 22(11): 21052110.
- Vilela-Martin JF, Vaz-de-Melo RO, Kuniyoshi CH, Abdo ANR, Yugar-Toledo JC (2011) Hypertensive crisis: clinical-epidemiological profile. *Hypertens Res* 34(3): 367-371.
- Geraldo Pierin AM, Flórido CF, Dos Santos J (2019) Hypertensive crisis: clinical characteristics of patients with hypertensive urgency, emergency and pseudocrisis at a public emergency department. *Einstein (Sao Paulo)* 17(4): eAO4685.
- Shea S, Misra D, Ehrlich MH, Field L, Francis CK (1992) Predisposing Factors for Severe, Uncontrolled Hypertension in an Inner-City Minority Population. *N Engl J Med* 327(11): 776-781.
- Guiga H, Sarlon-Bartoli G, Silhol F, Radix W, Michelet P, et al. (2016) Prévalence et gravité des urgences et des poussées hypertensives dans le service d'urgence hospitalière du CHU La Timone de Marseille : suivi à trois mois des patients hospitalisés. *Ann Cardiol Angéiologie* 65(3): 185-190.
- Alshami A, Romero C, Avila A, Varon J (2018) Management of hypertensive crises in the elderly. *J Geriatr Cardiol JGC* 15(7): 504512.
- Martin JFV, Higashiyama E, Garcia E, Luizon MR, Cipullo JP (2004) Hypertensive crisis profile. Prevalence and clinical presentation. *Arq Bras Cardiol* 83(2): 131136; 125130.
- Ngongang Ouankou C, Chendjou Kapi LO, Azabji Kenfack M, Nansseu JR, Mfeukeu-Kuate L, et al. (2019) Hypertension artérielle sévère nouvellement diagnostiquée dans un pays en Afrique sub-saharienne : aspects épidémiocliniques, thérapeutique et évolutifs. *Ann Cardiol Angéiologie* 68(4): 241248.
- Wallach R, Karp RB, Reves JG, Oparil S, Smith LR, et al. (1980) Pathogenesis of paroxysmal hypertension developing during and after coronary bypass surgery: A study of hemodynamic and humoral factors. *Am J Cardiol* 46(4): 559565.
- Derhaschnig U, Testori C, Riedmueller E, Hobl EL, Mayr FB, et al. (2014) Decreased renal function in hypertensive emergencies. *J Hum Hypertens* 28(7): 427431.
- Cherney D, Straus S (2002) Management of patients with hypertensive urgencies and emergencies: a systematic review of the literature. *J Gen Intern Med* 17(12): 937-945.

19. Truelsen T, Begg S, Mathers C (2000) The global burden of cerebrovascular disease. Pp. 1-67.
20. Godoy DA, Boccio A (2005) Early neurologic deterioration in intracerebral hemorrhage: Predictors and associated factors. *Neurology* 64(5): 931-932.
21. An SJ, Kim TJ, Yoon BW (2017) Epidemiology, Risk Factors, and Clinical Features of Intracerebral Hemorrhage: An Update. *J Stroke* 19(1): 310.



This work is licensed under Creative Commons Attribution 4.0 License
DOI: [10.19080/JOCCT.2023.19.556001](https://doi.org/10.19080/JOCCT.2023.19.556001)

**Your next submission with Juniper Publishers
will reach you the below assets**

- Quality Editorial service
- Swift Peer Review
- Reprints availability
- E-prints Service
- Manuscript Podcast for convenient understanding
- Global attainment for your research
- Manuscript accessibility in different formats
(Pdf, E-pub, Full Text, Audio)
- Unceasing customer service

Track the below URL for one-step submission
<https://juniperpublishers.com/online-submission.php>