



# Evaluation of Hepato-Protective Activity of *B. Lycium* Methenolic Crude Extracts Collected from Distric Sherani, Balochistan



Sami Ullah Sherani, Javied Iqbal, Amanullah Khan, Muhammad Ali Khan\*, Nadeem Rashid, Mohammad Masood Tariq, Zia ud Din and Saadullah Jan

University of Baluchistan Quetta, Pakistan

Submission: January 05, 2019; Published: January 25, 2019

\*Corresponding author: Muhammad Ali, University of Baluchistan Quetta, Pakistan

## Abstract

*Berberis lycium*, which is commonly called as Indian barberry (English) and Kashmal or *Ishkeen* in Urdu, is a spiky plant which is the member of the genus *Berberis* of family *Berberidaceae*. *B. lycium* also includes anti-hepatotoxicity effect, when was mixed with *G. aparine* and *P. integerrima* and was tested in rats that were treated with carbon tetra chloride; the results revealed that the combination of these three medicinal plants encompasses anti hepatotoxicity effects. *B. lycium* (root) sample was collected from the hill of village of Ahmadedergah near to Tahkhta Suleiman District Sherani Baluchistan, Pakistan. The collected samples were identified by Pharmacognosy, Department faculty of Pharmacy University of Baluchistan, Quetta. Adult healthy rabbits (male) having weights approximately 950g-1300g, were kept in animals house at CASVAB, UoB.

Sample serum, within 3 hours after collection, was analyzed for certain biochemical parameters (Alkaline Phosphatase (ALP), Alanine Aminotransferase (ALT), Gamma Glutamyl Transpeptidase ( $\gamma$ -GT), Aspartate aminotransferase (AST), and total Proteins like Bilirubin, Albumin and Globulin) through automatic analyzer (Merck) at 37° C through standard reagent kits. The obtained values for LFT in the current portion of controlled group were, 0.76± 0.060, 0.032±0.008 (mg/dL), 4.2±0.802, 93.8±1.500, 2.28±0.107 and 273±2.818 (U/L) for TB, DB, ALT, AKP, GGT, SGOT and SGPT (AST) levels. Whereas, the group treated with CCl<sub>4</sub> these parameters were, 0.86±0.075, 0.064±0.006 (mg/dL), 4.6±0.680, 2.44±0.150, 90.4±3.467 and 218.4±1.439 (U/L) level. While, the group treated with CCl<sub>4</sub> and *B. lycium* 500mg, the above parameters were calculated as 0.92±0.086, 0.442±0.228 (mg/dL), 4.4±0.601, 93.2±1.244, 2.62±0.097 and 221.6±1.540 (U/L), respectively.

In controlled group the values for Total Proteins, Albumin and Globulin, were 6.18±0.097, 3.38±0.132 and 3.42±0.165 (g/dL), while, the values for the same parameters in CCl<sub>4</sub> treated group were, 6.54±0.116, 5.24±0.12 and 7.17±0.116 (g/dL) respectively. Whereas, the same parameters were calculated in the group treated with *B. Lycium* 500mg/kg and CCl<sub>4</sub>, the resulted values were 6.4±0.164, 3.86±0.081 and 2.68±0.102 (g/dL), respectively.

**Keywords:** Berberis lyceum; Sherani; Hepatoprotective activity; Balochistan; LFT; PP

## Introduction

In Pakistan, many native plants are utilized in herbal medicine to treat diseases and injuries. Such plants often show a broad spectrum of biologic and pharmacologic activities, for example, they are able to reduce inflammation, having antibacterial and antifungal properties Cowan MM [1]. The root, bark, seed and fruit extracts of the medicinal plants are used in syrups and infusions, traditionally [2]. *Berberis lycium*, which is commonly called as Indian barberry (English) and Kashmal or *Ishkeen* in Urdu, is a spiky plant which is the member of the genus *Berberis* of family *Berberidaceae* [3]. It is found in the moderate and semitropical Asian, European and American divisions [4]. In Pakistan it is extensively distributed in Baluchistan, KPK and Punjab provinces,

especially in northerly regions, Swat and Azad Kashmir at elevation of 900 to 2900m [5]. *B. lycium* is a vertical flowering bush plant that increases to a length of 3-4 meters, having a solid timber stem and is enclosed in a slight fragile bark. The branches of *B. lycium* are light white to grayish and have thorns alternatively fixed on them [6]. Root bark could be approximately 3 mm solid, from the outside fractured and inside smooth [7]. *B. lycium* is extensively utilized for the treatment UTI, swelling of spleen, stomach and intestinal ulcer and liver diseases.

Local population utilizes the powdered form of dried root bark after combining with dissolved animal fat for bone fractures as a bandage. Shoots of the plant are employed for the abdomen

pain, jaundice and loose bowels [8]. The bark of the plant has wound healing activity [9] (Figure 1). *B. lycium* also includes anti-hepatotoxicity effect, when was mixed with *G. aparine* and *P. integerrima* and was tested in rats that were treated with carbon tetra chloride; the results revealed that the combination of these three medicinal plants encompasses anti hepatotoxicity effects [10]. To estimate Hepatoprotective effect of *B. lycium*, crude powder and Methanolic extract of plant were used.  $CCl_4$  was given to the rabbits to induce hepatotoxicity [11]. Results showed that plant considerably decreased the elevated levels of serum glutamic oxaloacetic transaminase, serum glutamic pyruvic transaminase and alkaline phosphatase enzymes in hepatotoxic rabbits [4]. Herbo-med, Kolkata in another study six poly herbal formulations including Livokin and *B. lycium* in mice. This formulation showed Hepatoprotective effect in paracetamol stimulated hepatotoxic mice [7]. The present study was therefore designed to evaluate the in vitro hepatoprotective effect of *B. lycium*.



Figure 1: *B. Lycium*.

## Materials and Methods

*Berberis Lycium* (root) sample was collected from the hill of village of Ahmadedergah near to Tahkhta Suleiman District Sherani Balochistan, Pakistan. The collected samples were identified by Pharmacognosy, Department faculty of Pharmacy University of Baluchistan, Quetta under the specimen's voucher (No. S-243) (Figure 2).



Figure 2: Ahmadedergah near to Tahkhta Suleiman District Sherani.

After the collection of the plant roots following procedure was adapted;

- The fresh plant of *B. lycium* roots were exposed to washing and chopping [12].
- Then desired materials were left for 60 minutes (Lust, 2014).
- After that the herb was cut into small pieces.
- Dehydrated is shed at 25°C for 30 days.
- The dried fragments were milled into fine powder.
- Macerated in methanol at room temperature, occasional shaking as well as stirring done on alternate day for fifteen days followed filtration.
- The extracts obtained were concentrated via Hieroglyph rotary serial number 519-00000-003, made of (Germany) evaporation at (45°C).
- Semi-solid (CMEs) was obtained, kept at 4°C until screened for further processing [13].

Adult healthy rabbits (male) having weights approximately 950g-1300g, were kept in animals house at CASVAB, UoB. The selected animals were kept in metal cage and feed with clean water and food throughout the study period under standard protocol of relative humidity, [14] temperature (22 ± 1°C) and 12hrs light/dark cycles and adapted for 1 week earlier the test in the research Laboratory of CASVAB. Before conducting the research, the procedure for research was approved by the Animal Ethics Committee (AEEC) of university of Balochistan, Quetta. Silimycin (DTL) liquid paraffin and Media of analytical grade were used in in the experiments [15].

The dose was based on the body weight (mg/kg) and calculated through following formula

$$\frac{\text{Animal Weight (kg)} \times \text{dosage (mg / kg)}}{\text{Concentration of drug (mg / ml)}} = \text{Drug Volume in ml or cc}$$

The Methanolic crude extracts (MCE) were dissolved and diluted with distilled water. Controlled animals were treated with an equal volume of saline solution [16]. The oral route was used for plant extract while for the standard and control oral and intraperitoneal (i.p) and subcutaneously route was used.

- Rabbits were adapted for seven days before experiment and housed in standard temperature humidity and light conditions with 12-hour light/ darkness cycle (Good Laboratory) were used [17].
- Rabbits weighing 1000-1400 gm in the control group (group 1), NaCl 0.9% (1ml / Kg)
- The treated group was given  $CCl_4$  (Carbon tetrachloride) (Group II).
- Plant extract (MCE) dose 500mg/kg/day was given to Group III [18].

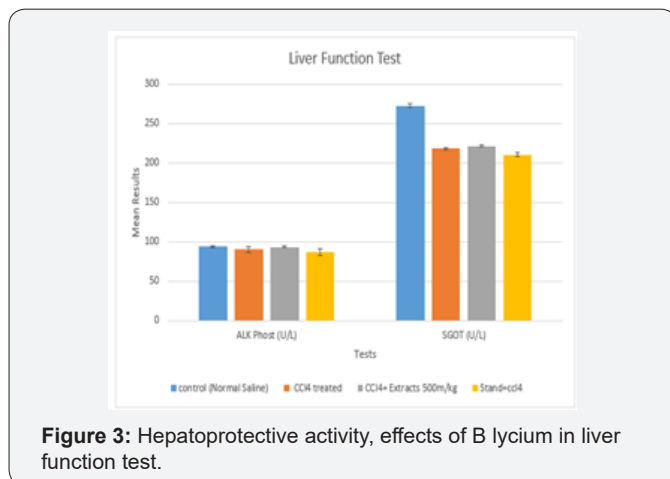
- e. Standard drug (Silimyarin) of dose 100 mg/kg/day administered to Group IV. (15 days)
- f. On the sixteenth day the Groups 2,3,4 were administered CCl<sub>4</sub> with 1:1, 1.5ml/Kg liquid paraffin afterward 30 min of the 2nd dosage of vehicle [19].
- g. Group IV was treated with Silimyarin 100 µg/kg bw weight group along with CCl<sub>4</sub> [20].
- h. Group III were treated with MCE with the concentration of 500 mg/kg body weight, respectively with CCl<sub>4</sub> [21].
- i. After 36 hours of last dose, 5cc blood were taken in Eppendorf via cardiac puncture technique to obtain the serum [22]. The samples were kept in centrifuge machine up to 6000 rpm for ten minutes.
- j. Sample serum, within 3 hours after collection, was analyzed for certain biochemical parameters (Alkaline phosphatase (ALP), Alanine aminotransferase (ALT) [23], Gamma glutamyl transpeptidase (γ-GT), Aspartate aminotransferase (AST), and total Proteins like Bilirubin, Albumin and Globulin) through automatic analyzer (Merck) at 37°C through standard reagent kits [24].

**Results**

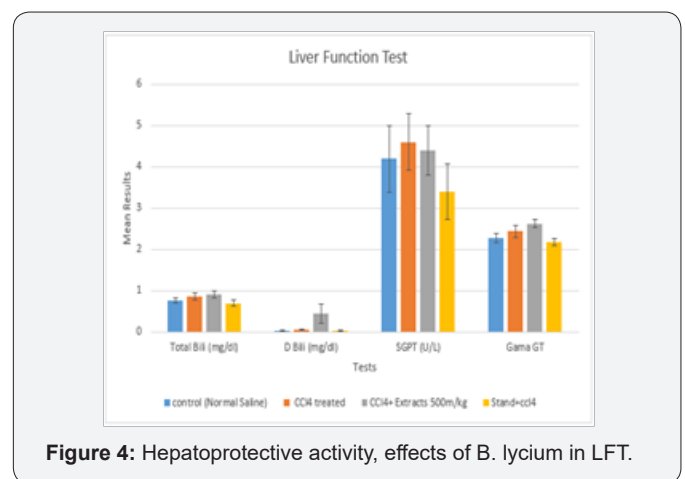
**Liver Function Test (LFT)**

**Table 1:** Hepatoprotective activity, effects of *B. lycium* in liver function test.

Test	TB (mg/dl)	DB (mg/dl)	SGPT(U/L)	Gama GT	AKP (U/L)	SGOT (U/L)
Control-Normal Saline	0.46±0.060	0.22±0.008	3.± 0.802	2.28±0.107	80.8±1.500	260± 2.818
CCl <sub>4</sub> treated	0.86±0.075	0.064±0.006	4.9±0.680	2.44±0.150	99.4±3.467	288.4±1.439
CCl <sub>4</sub> +Ex-tracts500m/kg	0.92±0.086	0.442±0.228	4.0± 0.601	2.62± 0.097	90.2±1.244	270.6±1.540
Stand+CCl <sub>4</sub>	0.7±0.0838	0.28±0.008	3.4±0.680	2.18±0.0802	86.8±4.544	210.6±2.587



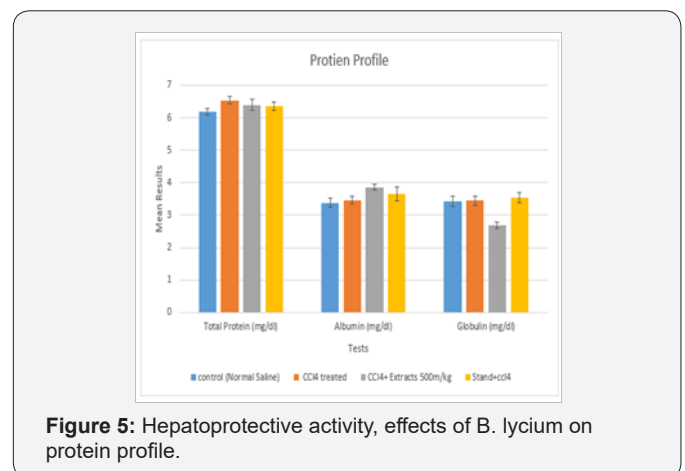
**Figure 3:** Hepatoprotective activity, effects of *B. lycium* in liver function test.



**Figure 4:** Hepatoprotective activity, effects of *B. lycium* in LFT.

The obtained values for LFT in the current portion of controlled group were, 0.76± 0.060, 0.032±0.008 (mg/dL), 4.2±0.802, 93.8±1.500, 2.28±0.107 and 273±2.818 (U/L) for TB, DB, ALT, AKP, GGT, SGOT and SGPT (AST) levels. Whereas, the group treated with CCl<sub>4</sub> these parameters were, 0.86±0.075, 0.064±0.006 (mg/dL), 4.6±0.680, 2.44±0.150, 90.4±3.467 and 218.4±1.439 (U/L) level. While, the group treated with CCl<sub>4</sub> and *B. lycium* 500mg, the above parameters were calculated as 0.92±0.086, 0.442±0.228 (mg/dL), 4.4±0.601, 93.2±1.244, 2.62±0.097 and 221.6±1.540 (U/L), respectively. Silimyarin, was used as a standard drug treated with CCl<sub>4</sub> and the values for TB, DB, ALT, AKP, GGT, SGOT and SGPT were, 0.7±0.0838, 0.028±0.008 (mg/dL) 3.4±0.680, 86.8±4.544, 2.18±0.0802 and 210.6±2.587 (U/L), respectively (Table 1) (Figures 3 & 4).

**Protein Profile**



**Figure 5:** Hepatoprotective activity, effects of *B. lycium* on protein profile.

In controlled group the values for Total Proteins, Albumin and Globulin, were 6.18±0.097, 3.38±0.132 and 3.42±0.165 (g/dL), while, the values for the same parameters in CCl<sub>4</sub> treated group were [25], 6.54±0.116, 5.24±0.12 and 7.17±0.116 (g/dL)

respectively. Whereas, the same parameters were calculated in the group treated with B. Lycium [26]500mg/kg and CCl<sub>4</sub>, the resulted values were 6.4±0.164, 3.86±0.081 and 2.68±0.102 (g/dL), respectively (Table 2) (Figure 5).

**Table 2:** Hepatoprotective activity, effects of B. lycium on protein profile.

	TP (mg/dl)	Al(mg/dl)	Gl (mg/dl)
Controlled group	6.18±0.097	3.38±0.132	3.42±0.165
CCl <sub>4</sub> treated	6.54±0.116	5.24±0.12	7.17±0.116
CCl <sub>4</sub> ±Extracts 500m/kg	6.4±0.164	3.86±0.081	2.68±0.102
Stand+CCl <sub>4</sub>	6.36±0.133	3.64±0.211	3.54±0.163

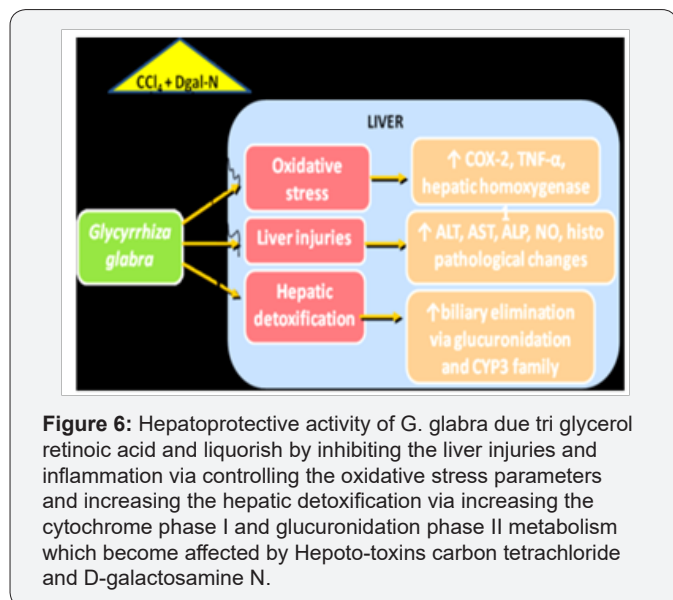
## Discussion

Liver is the main organ of metabolism and energy production. It regulates systemic lipid homeostasis, which is involved in the redistribution of lipoproteins, triacylglycerol for storage and utilization by peripheral tissues [22]. Several plant extracts have been examined for use in a wide variety of liver disorders, *G. pentaphylla* protects membrane integrity in mice hepatocytes [19]. *S. marianum* is a chemo-preventive agent that shows antitumor activity against human tumors in rodents (Agarwal et al., 2006). Similarly, several cases of hepatotoxic side effects of green tea have been reported in rats [19] (Figure 6). During the present study all the treated groups of the tested animals (rabbits) were given CCl<sub>4</sub> according to the recommended doses and evaluated serum TB, DB, Alanine aminotransferase (ALT), Alkaline phosphatase (ALP), Gamma glut-amy transferases (GGT), SGOT and Aspartate aminotransferase (AST or SGPT) by Liver function test (LFT), furthermore, total protein (TP), Albumin (Al), Globulin (Gb) were calculated through Protein Profile test (PFT) [17].

(AST) and TP, Al and Gb in the tested animals (rabbits) [27]. Higher activities of these enzymes in serum have been found in response to oxidative stress induced CCl<sub>4</sub>. This was also evidenced from the downturn in levels of marker enzymes of test groups compared with the toxic control group and pure drug [28]. The improvement in the enzyme activity was due to sustained and targeted action of Silimyarin and MCE on the hepatocytes due to their pronounced antioxidant effect may have diminished the release of SGOT, SGPT and ALP enzymes from the liver cells, [29] thereby eliciting Hepatoprotective activity [30]. The findings of the present study also showed antioxidant properties, which are comparable to some previous reported [31] studies of other plant extracts, having Hepatoprotective activity [32], *B. lyceum* showed strong free radical scavenging activity when extracted [33] by methanol [9]. The results of this study showed that after administration of MCE the activities [34] of the serum marker enzymes were returned to near to the standard drug (Silimyarin) [35].

## Conclusion

Methanolic Crude Extracts of root of *B. lycium* showed remarkable Hepatoprotective activity in the experimental rabbits and the results were almost near to those of the Silimyarin drug, which was used as a standard drug during the study. Furthermore, the hepatotoxicity due to CCl<sub>4</sub> can be reduced up to safe level through the usage of this plant extract. These results have showed some light on the clinical therapeutic potential of these MCE of *B. lyceum* against hepatotoxic agents. More studies should be performed similar to this research in order to specify the main phyto compounds present in this plant which may be responsible for Hepatoprotective activity.



**Figure 6:** Hepatoprotective activity of *G. glabra* due tri glycerol retinoic acid and liquorish by inhibiting the liver injuries and inflammation via controlling the oxidative stress parameters and increasing the hepatic detoxification via increasing the cytochrome phase I and glucuronidation phase II metabolism which become affected by Hepato-toxins carbon tetrachloride and D-galactosamine N.

It is revealed from the results of this study that the Methanolic Crude Extracts (MCE) of *B. lyceum* at the dose of 500mg/kg body weight decreased serum TB, DB, ALT, AKP, GGT, SGOT and SGPT

## References

- Cowan MM (1999) Plant products as antimicrobial agents. Clinical microbiology reviews p. 564-582.
- Imtiaz UH, Manzoor H (2003) Medicinal plants of Mansehra. Hamdard medicus 36: 69.
- Sabir S (2013) Phytochemical and antioxidant studies of *Berberis lycium*. Pakistan journal of pharmaceutical sciences 26(6): 1165-1172.
- Jabeen N, Saleem A, Anwaar S, Hussain Z (2015) *Berberis lycium* Royle (Royle, 1837): A threatened medicinal plant and Its biological activities. EC Agri culture 1(2): 100-108.



5. Dhar S, sharma YP, Wakhlu AK (2012) In vitro plant regeneration system for *Berberis lycium* using cotyledonary node explants. *Journal of Tropical Medicinal Plants* 13(1): 51-55.
6. Ahmad M, Alamgeer, Sharif T (2009) A potential adjunct to Insulin: *Berberis lycium* Royle. *Diabetologia Croatica* 38(1): 13-18.
7. Chauhan, NS (1999) Medicinal and aromatic plants of Himachal Pradesh. Indus publishing, India.
8. Beers SJ (2012) *Jamu: the ancient Indonesian art of herbal healing*. Tuttle Publishing, USA.
9. Asif A, Kakub G, Mehmood S, Khunum R, Gulfraz M, et al. (2007) Wound healing activity of root extracts of *Berberis lycium* Royle in rats. *Phytotherapy Research* 21(6): 589-591.
10. Thounaojam MC, Jadeja RN, Valodkar M, Nagar PS, Devkar RV, et al. (2011) Oxidative stress induced apoptosis of human lung carcinoma (A549) cells by a novel copper nanorod formulation. *Food and chemical toxicology* 49(11): 2990-2996.
11. Ahmad M (2008) Hepatoprotective effect of *Berberis lycium* (Royle) in hepatotoxic rabbits. *Gomal University journal of research* pp. 24.
12. Joseph B, Jini D (2011) Insight into the hypoglycaemic effect of traditional Indian herbs used in the treatment of diabetes. *Research Journal of Medicinal Plant* 5(4): 352-376.
13. Yang Z, Zhai W (2010) Identification and antioxidant activity of anthocyanins extracted from the seed and cob of purple corn (*Zea mays* L.). *Innovative Food Science & Emerging Technologies* 11(1): 169-176.
14. Potdar D (2012) Phyto-chemical and pharmacological applications of *Berberis aristata*. *Fitoterapia* 83(5): 817-830.
15. Zovko K, Kremer D, Karlovic K, Kosalic L (2010) Evaluation of antioxidant activities and phenolic content of *Berberis vulgaris* L. and *Berberis croatica* Horvat. *Food and chemical toxicology* 48(8-9): 2176-2180.
16. Shamsa F, Ahmadiani A, KhosroKhavar R (1999) Antihistaminic and anticholinergic activity of *Berberis* fruit (*Berberis vulgaris*) in the guinea pig ileum. *Journal of Ethnopharmacology* 64(2): 161-166.
17. Amin A, Hamza AA (2005) Oxidative stress mediates drug-induced hepatotoxicity in rats: A possible role of DNA fragmentation. *Toxicology* 208(3): 367-375.
18. Ivanovska N, Philipov S (1996) Study on the anti-inflammatory action of *Berberis vulgaris* root extract, alkaloid fractions and pure alkaloids. *International journal of Immunopharmacology* 18(10): 553-561.
19. Okamura H, Akio M, Yasuko Y, Misturu N (1993) Antioxidant activity of tannins and flavonoids in *Eucalyptus rostrata*. *Phytochemistry* 33(3): 557-561.
20. Royle JF (1834) On the *Lycium* of Dioscorides. *Transactions of the Linnean Society of London* 17(1): 83-94.
21. Kim YJ, Park T (2008) Genes are differentially expressed in the epididymal fat of rats rendered obese by a high fat diet. *Nutr Res* 28(6): 414-422.
22. Demori I., Voci A, Fugassa E., Burlando B (2006) Combined effects of high-fat diet and ethanol induce oxidative stress in rat liver. *Alcohol* 40(3): 185-191.
23. Lee CH, Olson P, Evans RM (2003) Minireview: lipid metabolism, metabolic diseases, and peroxisome proliferator-activated receptors. *Endocrinology*, 144(6): 2201-2207.
24. AgyareC, Asase A, Lechtenberg M, Niehues M, Deters A, et al. (2009) An ethnopharmacological survey and in vitro confirmation of ethnopharmacological use of medicinal plants used for wound healing in Bosomtwi Atwima Kwanwoma area Ghana. *Journal of Ethnopharmacology* 125(3): 393-403.
25. Abere TA, Okoto PE, Agoreyo FO (2010) Antidiarrhoea and toxicological evaluation of the leaf extract of *Dissotis rotundifolia* triana (Melastomataceae). *BMC complementary and alternative medicine* 10(1): 71.
26. Yang JJ, Li GL, Liu HR, Ren BB (2003) Effect of eveningrose oil on activities of oxygen free radical scavenging-related enzymes and hepatic morphosis in rats on high lipid diet. *J NingXia Med Coll* 25: 244-246.
27. Yang JS, Lee SJ, Park HW, Cha YS (2006) Effect of genistein with carnitine administration on lipid parameters and obesity in C57Bl/6J mice fed a high fat diet. *J Med Food* 9(4): 459-467.
28. Eisenberg DM, Kessler RC, Foster C, Norlock, FE, Calkins DR, et al. (1993) Unconventional medicine in the United States prevalence, costs, and patterns of use. *New England Journal of Medicine* 328(4): 246-252.
29. Eisenberg DM, Davis RB, Ettner SL, Appel S, Wilkey S, et al. (1998) Trends in alternative medicine use in the United States, 1990-1997: results of a follow-up national survey. *Jama* 280(18): 1569-1575.
30. Raskin I, Ribnicky DM, Komarnytsky S, Ilic N, Poulev A, et al. (2002) Plants and human health in the twenty-first century. *TRENDS in Biotechnology* 20(12): 522-531.
31. Abere TA, Okoto PE, Agoreyo FO (2010) Antidiarrhea and toxicological evaluation of the leaf extract of *Dissotis rotundifolia* triana (Melastomataceae). *BMC complementary and alternative medicine* 10(1): 71.
32. Myagmar BE, Shinno E, Ichiba T, Aniya Y (2004) Antioxidant activity of medicinal herb *Rhodococcum vitisidaea* on galactosamine-induced liver injury in rats. *Phytomedicine* 11(5): 416-423.
33. Paul, Daizy (2010) *Studies on the Medicinal Flora of Amritsar District*.
34. Jafri SMH. *Berberidaceae. Flora of Pakistan*.
35. Rong XL, Kim MS, Su N, Wen SP, Matsuo Y, et al. (2008) An aqueous extract of *Salacia oblonga* root, a herb-derived peroxisome proliferator-activated receptor alpha activator, by oral gavage over 28 days induces gender dependent hepatic hypertrophy in rats. *Food Chem. Toxicol* 46(6): 2165-2172.



This work is licensed under Creative Commons Attribution 4.0 License  
DOI: [10.19080/JPCR.2019.06.555696](https://doi.org/10.19080/JPCR.2019.06.555696)

**Your next submission with Juniper Publishers  
will reach you the below assets**

- Quality Editorial service
- Swift Peer Review
- Reprints availability
- E-prints Service
- Manuscript Podcast for convenient understanding
- Global attainment for your research
- Manuscript accessibility in different formats  
( Pdf, E-pub, Full Text, Audio)
- Unceasing customer service

Track the below URL for one-step submission  
<https://juniperpublishers.com/online-submission.php>